Advanced Analysis of Complex Aortic Aneurysm Repair



Titia A.L. Sulzer

Propositions

1. Whether FEVAR is a durable treatment after failed EVAR remains unclear: although mid-term survival is unaffected, nearly half of patients show aneurysm sac growth within a year, and reinterventions are frequently required. — This thesis

2. Mid-term outcomes show no difference between supraceliac and infraceliac sealing. However, a longer sealing zone may theoretically improve durability, a hypothesis that can only be confirmed with longer follow-up. — This thesis

3. Aneurysm sac growth after FB-EVAR is associated with increased mortality, highlighting the prognostic value of aneurysm sac dynamics during follow-up. — This thesis

4. Stenting of renal and mesenteric arteries reshapes blood flow: peak systolic velocities shift with vessel type, fenestration or branch technique, and stent design, yet never reach the threshold for native vessel stenosis. — This thesis

5. A family history of aortic disease does not affect mid-term outcomes after FB-EVAR in patients with complex aortic aneurysms in the absence of an identified genetic aortic disease. — This thesis

6. Tell me and I forget, teach me and I may remember, involve me and I learn. (Inspired by Benjamin Franklin, 1706-1790)

7. Diligence, not genius, is what makes good outcomes possible. (Inspired by Atul Gawande, 1965-present)

8. A stent may be perfect, yet the patient decides the outcome.

9. Festina lente.

10. Not everything that counts can be counted, and not everything that can be counted counts. (Often attributed to Albert Einstein, 1879-1955)

11. Wär' ich doch ein Huhn, dann hätt' ich nichts zu tun. Ich legte jeden Tag ein Ei, und sonntags manchmal zwei.

Advanced Analysis of Complex Aortic Aneurysm Repair

Titia A.L. Sulzer

The work presented in this thesis was conducted at the department of Vascular Surgery, Erasmus MC University Medical Center Rotterdam, the Netherlands, and the Department of Cardiothoracic and Vascular Surgery at the University of Texas Health Science Centre at Houston, TX, USA.

Financial support for printing this thesis was kindly provided by Erasmus Universiteit Rotterdam.

Cover design	Sophie van Hilten
Layout	Renate Siebes | Proefschrift.nu
Printing	ProefschriftMaken | www.proefschriftmaken.nl
ISBN	978-94-6534-557-4

© 2026 Titia A.L. Sulzer, the Netherlands
All rights reserved. No part of this thesis may be reproduced, distributed, stored in a retrieval system, or transmitted in any form or by any means, without prior written permission of the author.

Advanced Analysis of Complex Aortic Aneurysm Repair

Geavanceerde analyse van complexe aorta-aneurysma chirurgie

Proefschrift

ter verkrijging van de graad van doctor aan de
Erasmus Universiteit Rotterdam
op gezag van de
rector magnificus

Prof.dr.ir. A.J. Schuit

en volgens besluit van het College voor Promoties.
De openbare verdediging zal plaatsvinden op

vrijdag 11 september 2026 om 10.30 uur

door

Titia Anna Louise Sulzer
geboren te Haarlem.

Erasmus University Rotterdam

Promotiecommissie

Promotoren:	Prof.dr. H.J.M. Verhagen
	Prof.dr. G.S. Oderich
Copromotoren:	Dr. J.L. de Bruin
	Dr. T. Mesnard
Beoordelingscommissie:	Prof.dr. I. Kardys
	Prof.dr. J.D. Blankensteijn
	Prof.dr. B.M.E. Mees

Voor mijn familie

Table of contents

Chapter 1 Introduction **9**

PART I: Perioperative and Technical Aspects of Complex Aortic Aneurysms

Chapter 2 How We Would Treat Our Own Thoracoabdominal Aortic Aneurysm **19**

Chapter 3 Intraoperative Complications During Standard and Complex Endovascular Aortic Repair **39**

Chapter 4 Technical Pitfalls and Proposed Modifications of Instructions for use for Endovascular Aortic Aneurysm Repair Using the Gore Excluder Conformable Device in Angulated and Short Landing Zones **61**

PART II: Sac Dynamics as a Prognostic Marker for Clinical Success

Chapter 5 Aneurysm Sac Shrinkage at 1 Year After Fenestrated-Branched Endovascular Aortic Repair of Complex Aortic Aneurysms Offers Mid-Term Survival Advantage **73**

Chapter 6 Aneurysm Sac Dynamics and its Prognostic Significance Following Fenestrated and Branched Endovascular Aortic Aneurysm Repair **93**

Chapter 7 Midterm Outcomes and Aneurysm Sac Dynamics Following Fenestrated Endovascular Aneurysm Repair After Previous Endovascular Aneurysm Repair **113**

PART III: Duplex Ultrasound Surveillance After Complex Aortic Aneurysm Repair

Chapter 8	Changes in Renal-Mesenteric Duplex Ultrasound Velocities After Fenestrated and Branched Endovascular Aortic Aneurysm Repair	**135**
Chapter 9	Prospective Assessment of Changes in Target Vessel Peak Systolic Velocity Measurements After Fenestrated-Branched Endovascular Aortic Repair	**153**

PART IV: Optimizing Mid-Term Outcomes; The Role of Family History and Proximal Sealing Strategies

Chapter 10	Effect of Family History of Aortic Disease on Outcomes of Fenestrated and Branched Endovascular Aneurysm Repair of Complex Aortic Aneurysms	**177**
Chapter 11	Perioperative and Mid-Term Results of Supraceliac Versus Infraceliac Sealing for Fenestrated Endovascular Aortic Repair of Juxtarenal Aortic Aneurysms	**193**
Chapter 12	General discussion	**213**
Appendices	Nederlandse samenvatting	**233**
	List of publications	**238**
	PhD portfolio	**242**
	Dankwoord	**243**
	Curriculum vitae	**250**



Chapter 1

Introduction

The aorta is the largest artery in the human body and can be subdivided into five segments: the aortic root, the ascending thoracic aorta, the aortic arch, the descending thoracic aorta, and the abdominal aorta.[1]

An arterial aneurysm is typically defined as a dilatation of at least 1.5 times the expected normal diameter.[1, 2] Abdominal aortic aneurysm (AAA) is a common disease, with a global prevalence of approximately 4.8%.[3] The majority of AAAs are asymptomatic. When symptoms occur, they typically manifest as back pain, abdominal pain, or, in the worst-case clinical scenario rupture. A ruptured AAA requires emergency repair, whereas a non-ruptured symptomatic AAA is treated urgently, and asymptomatic AAAs are usually managed electively.[2, 4]

Established risk factors for AAA include male sex, cigarette smoking, hypertension, peripheral arterial disease, cerebrovascular disease, and a family history of AAA.[5, 6] The risk of rupture increases with the larger size of the aneurysm.[3] Computed tomography angiography (CTA) scans are highly sensitive and specific for detecting aortic pathology and are therefore considered the gold standard for diagnosis and management of AAAs.[1, 7]

Since the introduction in 1991, minimally invasive endovascular aortic aneurysm repair (EVAR) has become an established treatment option for AAA, offering lower perioperative morbidity and mortality compared to open surgical repair.[8] During EVAR, a stent graft is delivered through small groin incisions or percutaneously and deployed inside the aorta to exclude the aneurysm.[9]

Over subsequent decades, endovascular techniques have advanced rapidly. Fenestrated and branched endovascular aortic aneurysm repair (FB-EVAR) are less invasive approaches developed to treat complex aneurysms, and extensive research has demonstrated the effectiveness of these complex procedures.[10] Unlike standard EVAR, FB-EVAR incorporates fenestrations or branches to maintain perfusion of vital visceral arteries, including the renal arteries, the superior mesenteric artery, and the celiac trunk. The main goal of aneurysm management is to achieve a durable repair by sealing the stent graft within healthy aortic segments and excluding the aneurysm sac. Moreover, these techniques allow treatment of patients with complex aortic anatomy or extensive aneurysms without compromising blood flow to the visceral organs.

Since 2001, fenestrated devices have proven to be a safe and durable option for treating aneurysms. As of today, fenestrated stent grafts with up to five fenestrations and scallops (designed to preserve vessel patency at the edge of the graft) are used to

treat thoracoabdominal aortic aneurysms (TAAAs), and complex AAAs (e.g. pararenal, juxtarenal, and short-neck AAAs). Branched devices, which have been used in Europe since 2014, were approved by the Food and Drug Administration (FDA) in 2024. In the United States, the TAMBE device is the only branched device approved and commercially available since then.

This thesis is dedicated to examining the outcomes of complex aortic aneurysms treated with FB-EVAR, with the aim of evaluating the results of this technique at a time when the field is rapidly evolving and new technologies are continually emerging.

The thesis begins with **Part I**, which explores the clinical and technical background for complex endovascular aortic repair. **Chapter 2** investigates the pathophysiology and epidemiology of TAAAs. It also offers an in-depth discussion of the perioperative, intraoperative, and postoperative complications and subsequent management of these complex endovascular procedures in order to prevent or solve those issues.[11] **Chapter 3** provides a comprehensive review of the most common technical intraoperative adverse events (IAEs) during EVAR and FB-EVAR and potential solutions.[12] Focusing on technical challenges, **Chapter 4** illustrates a step-by-step modification of the Instructions For Use to facilitate deployment in a patient with a severely angulated proximal neck. Although EVAR is the treatment of choice for infrarenal AAAs with suitable anatomy, a severely angulated proximal neck (>60°-90°) remains challenging for accurate stent graft deployment and increases the risk of complications.[13]

Part II of this thesis focuses on aneurysm sac dynamics. **Chapter 5**, **6** and **7** are dedicated to the concept of aneurysm sac dynamics. Successful treatment with FB-EVAR is achieved by complete exclusion of the aneurysm sac, which typically results in sac regression or stabilization.[14] Stable aneurysm sac, and particularly sac regression, are recognized as important prognostic markers for improved mid- and long-term outcomes, including survival and reduced reintervention rates after infrarenal EVAR.[15, 16] **Chapter 5**, focuses on the impact of one-year changes in the aneurysm sac on patient survival after FB-EVAR for complex abdominal aortic aneurysms or TAAAs.[17] **Chapter 6** explores a broader approach by evaluating aneurysm sac dynamics and their prognostic significance following FB-EVAR, as well as identifying factors associated with lack of sac regression.[18] Finally, **Chapter 7** investigates the durability of FEVAR after prior (failed) EVAR, focusing on survival, reinterventions and sac dynamics.[19]

In **Part III**, the potential role of duplex ultrasound (DUS) in the follow-up after FB-EVAR is explored. Lifelong surveillance is required to detect complications and prompt secondary interventions.[20, 21] Although CTA remains the cornerstone for surveillance

after FB-EVAR, DUS examination is a valuable, noninvasive imaging modality that provides complementary information by detecting hemodynamic changes within stents, which are most often associated with significant stenosis.[22, 23] While velocity criteria for detecting renal and mesenteric arterial stenosis have been established for native vessels, such criteria do not yet exist for stented vessels.[24, 25] Moreover, the expected changes in systolic velocity (PSV) of renal and mesenteric arteries have not been reported. To address this gap, **Chapter 8** describes the patterns of velocity changes associated with the implantation of bridging stent grafts after FB-EVAR, comparing preoperative measurements to those obtained six to eight weeks postoperatively.[26] To further explore this subject, **Chapter 9** analyzes PSV measurements over a longer follow-up after FB-EVAR and examines the velocity patterns in patients who required secondary interventions for stent-related stenosis.[27]

In **Part IV**, specific factors are explored: family history of aortic disease and the choice of proximal sealing zone. Several factors may influence mid-term outcomes following FB-EVAR. A family history of aortic disease, commonly defined as the presence of a first-degree relative with an aortic aneurysm or dissection, is a recognized risk factor, affecting up to 10-25% of patients with AAAs.[1, 28, 29] Previous studies have reported worse 30-day and mid-term outcomes after standard EVAR in patients with a positive FH, although the mechanisms remain unclear and may relate to adverse anatomy or underlying, unrecognized connective tissue disorders.[30, 31] Evidence on the effect of family history in patients undergoing FB-EVAR for complex aortic aneurysms is limited. **Chapter 10** aims to fill this gap by using the United States Aortic Research Consortium multicenter database, to assess the impact of family history of aortic disease on 30-day and mid-term outcomes after FB-EVAR.[32]

Regarding FEVAR, centers are now opting to stent in a healthier and more proximal segment of the aorta. The strategy of sealing above the superior mesenteric artery and celiac axis may reduce the risk of sealing zone dilatation and disease progression and expand the durability of the repair.[33, 34] Although not much is known about long-term consequences of proximal seal dilatation at the visceral portion of the aorta after FEVAR, it might lead to complications requiring reinterventions. **Chapter 11** examines perioperative and mid-term outcomes, including sac dynamics, comparing supraceliac versus infraceliac sealing strategies for the treatment of juxtarenal and pararenal AAAs.[35]

References

1. Isselbacher EM, Preventza O, Hamilton Black J, 3rd, Augoustides JG, Beck AW, Bolen MA, et al. 2022 ACC/AHA Guideline for the Diagnosis and Management of Aortic Disease: A Report of the American Heart Association/American College of Cardiology Joint Committee on Clinical Practice Guidelines. Circulation. 2022;146(24):e334-e482.
2. Chaikof EL, Dalman RL, Eskandari MK, Jackson BM, Lee WA, Mansour MA, et al. The Society for Vascular Surgery practice guidelines on the care of patients with an abdominal aortic aneurysm. J Vasc Surg. 2018;67(1):2-77 e2.
3. Huber TS, Wang JG, Derrow AE, Dame DA, Ozaki CK, Zelenock GB, et al. Experience in the United States with intact abdominal aortic aneurysm repair. J Vasc Surg. 2001;33(2):304-10; discussion 10-1.
4. Li X, Zhao G, Zhang J, Duan Z, Xin S. Prevalence and trends of the abdominal aortic aneurysms epidemic in general population--a meta-analysis. PLoS One. 2013;8(12):e81260.
5. Johnston KW. Influence of sex on the results of abdominal aortic aneurysm repair. Canadian Society for Vascular Surgery Aneurysm Study Group. J Vasc Surg. 1994;20(6):914-23; discussion 23-6.
6. Vardulaki KA, Walker NM, Day NE, Duffy SW, Ashton HA, Scott RA. Quantifying the risks of hypertension, age, sex and smoking in patients with abdominal aortic aneurysm. Br J Surg. 2000;87(2):195-200.
7. Chung Y, Joh JH, Park HC. Measuring of Abdominal Aortic Aneurysm with Three-Dimensional Computed Tomography Reconstruction before Endovascular Aortic Aneurysm Repair. Vasc Specialist Int. 2017;33(1):27-32.
8. Parodi JC, Palmaz JC, Barone HD. Transfemoral intraluminal graft implantation for abdominal aortic aneurysms. Ann Vasc Surg. 1991;5(6):491-9.
9. Davis M, Taylor PR. Endovascular infrarenal abdominal aortic aneurysm repair. Heart. 2008;94(2):222-8.
10. Oderich GS, Forbes TL, Chaer R, Davies MG, Lindsay TF, Mastracci T, et al. Reporting standards for endovascular aortic repair of aneurysms involving the renal-mesenteric arteries. J Vasc Surg. 2021; 73(1S):4S-52S.
11. Sulzer TAL, Vacirca A, Mesnard T, Baghbani-Oskouei A, Savadi S, Kanamori LR, et al. How We Would Treat Our Own Thoracoabdominal Aortic Aneurysm. J Cardiothorac Vasc Anesth. 2024;38(2):379-87.
12. Sulzer T, Tenorio ER, Mesnard T, Vacirca A, Baghbani-Oskouei A, de Bruin JL, et al. Intraoperative complications during standard and complex endovascular aortic repair. Semin Vasc Surg. 2023; 36(2):189-201.
13. Vacirca A, Sulzer TAL, Mesnard T, Baghbani-Oskouei A, Ocasio L, Macedo TA, et al. Technical pitfalls and proposed modifications of instructions for use for endovascular aortic aneurysm repair using the Gore Excluder conformable device in angulated and short landing zones. J Vasc Surg Cases Innov Tech. 2023;9(4):101339.
14. Lee JT, Aziz IN, Lee JT, Haukoos JS, Donayre CE, Walot I, et al. Volume regression of abdominal aortic aneurysms and its relation to successful endoluminal exclusion. J Vasc Surg. 2003;38(6):1254-63.
15. O'Donnell TFX, Deery SE, Boitano LT, Siracuse JJ, Schermerhorn ML, Scali ST, et al. Aneurysm sac failure to regress after endovascular aneurysm repair is associated with lower long-term survival. J Vasc Surg. 2019;69(2):414-22.
16. Antoniou GA, Alfahad A, Antoniou SA, Torella F. Prognostic Significance of Aneurysm Sac Shrinkage After Endovascular Aneurysm Repair. J Endovasc Ther. 2020;27(5):857-68.
17. Mesnard T, Sulzer TAL, Kanamori LR, Babocs D, Vacirca A, Baghbani-Oskouei A, et al. Aneurysm sac shrinkage at 1 year after fenestrated-branched endovascular aortic repair of complex aortic aneurysms offers mid-term survival advantage. J Vasc Surg. 2024;80(4):958-67 e3.
18. Rastogi V, Sulzer TL, de Bruin JL, Oliveira-Pinto J, Alberga AJ, Hoeks SE, et al. Aneurysm Sac Dynamics and its Prognostic Significance Following Fenestrated/Branched Endovascular Aortic Aneurysm Repair. Eur J Vasc Endovasc Surg. 2024;67(5):728-36.
19. Sulzer TAL, de Bruin JL, Rastogi V, Boer GJ, Mesnard T, Fioole B, et al. Midterm Outcomes and Aneurysm Sac Dynamics Following Fenestrated Endovascular Aneurysm Repair after Previous Endovascular Aneurysm Repair. Eur J Vasc Endovasc Surg. 2024;67(6):886-93.
20. Dossabhoy SS, Simons JP, Diamond KR, Flahive JM, Aiello FA, Arous EJ, et al. Reinterventions after fenestrated or branched endovascular aortic aneurysm repair. J Vasc Surg. 2018;68(3):669-81.
21. Schanzer A, Oderich GS. Management of Abdominal Aortic Aneurysms. N Engl J Med. 2021; 385(18): 1690-8.

22. Tran K, McFarland G, Sgroi M, Lee JT. Duplex ultrasound surveillance of renal branch grafts after fenestrated endovascular aneurysm repair. J Vasc Surg. 2019;70(4):1048-55.
23. Zierler RE. Duplex ultrasound follow-up after fenestrated and branched endovascular aneurysm repair (FEVAR and BEVAR). Semin Vasc Surg. 2020;33(3-4):60-4.
24. Olin JW, Piedmonte MR, Young JR, DeAnna S, Grubb M, Childs MB. The utility of duplex ultrasound scanning of the renal arteries for diagnosing significant renal artery stenosis. Ann Intern Med. 1995; 122(11):833-8.
25. Hoffmann U, Edwards JM, Carter S, Goldman ML, Harley JD, Zaccardi MJ, et al. Role of duplex scanning for the detection of atherosclerotic renal artery disease. Kidney Int. 1991;39(6):1232-9.
26. Sulzer TAL, Macedo TA, Strissel N, Hesley GK, Lekah A, Tallarita T, et al. Changes in Renal-Mesenteric Duplex Ultrasound Velocities after Fenestrated and Branched Endovascular Aortic Aneurysm Repair. J Vasc Surg. 2023;78(5):1162-9 e2.
27. Sulzer TAL, Macedo TA, Mesnard T, Tenorio ER, Lima GBB, Hatz H, et al. Prospective assessment of changes in target vessel peak systolic velocity measurements after fenestrated-branched endovascular aortic repair. J Endovasc Ther. 2025;15266028251368250.
28. van de Luijtgaarden KM, Bastos Goncalves F, Hoeks SE, Majoor-Krakauer D, Rouwet EV, Stolker RJ, et al. Familial abdominal aortic aneurysm is associated with more complications after endovascular aneurysm repair. J Vasc Surg. 2014;59(2):275-82.
29. Brown CR, Greenberg RK, Wong S, Eagleton M, Mastracci T, Hernandez AV, et al. Family history of aortic disease predicts disease patterns and progression and is a significant influence on management strategies for patients and their relatives. J Vasc Surg. 2013;58(3):573-81.
30. Ryer EJ, Garvin RP, Thomas B, Kuivaniemi H, Franklin DP, Elmore JR. Patients with familial abdominal aortic aneurysms are at increased risk for endoleak and secondary intervention following elective endovascular aneurysm repair. J Vasc Surg. 2015;62(5):1119-24 e9.
31. van de Luijtgaarden KM, Bastos Goncalves F, Hoeks SE, Blankensteijn JD, Bockler D, Stolker RJ, et al. Higher 30 Day Mortality in Patients with Familial Abdominal Aortic Aneurysm after EVAR. Eur J Vasc Endovasc Surg. 2017;54(2):142-9.
32. Sulzer TAL, Mesnard T, Schanzer A, Timaran CH, Schneider DB, Farber MA, et al. Effect of Family History of Aortic Disease on Outcomes of Fenestrated and Branched Endovascular Aneurysm Repair of Complex Aortic Aneurysms. Eur J Vasc Endovasc Surg. 2024;68(6):712-8.
33. Katsargyris A, Oikonomou K, Kouvelos G, Mufty H, Ritter W, Verhoeven ELG. Comparison of outcomes for double fenestrated endovascular aneurysm repair versus triple or quadruple fenestrated endovascular aneurysm repair in the treatment of complex abdominal aortic aneurysms. J Vasc Surg. 2017;66(1):29-36.
34. Zettervall SL, Dansey K, Kline B, Singh N, Starnes BW. Significant aortic neck dilation occurs after repair of juxtarenal aneurysms with fenestrated endovascular aneurysm repair. J Vasc Surg. 2021; 74(4):1090-7 e2.
35. Sulzer TAL, de Bruin JL, Rastogi V, Boer GJ, Ultee KHJ, Fioole B, et al. Peri-operative and Midterm Results of Supracoeliac versus Infracoeliac Sealing for Fenestrated Endovascular Aortic Repair of Juxtarenal Aortic Aneurysms. Eur J Vasc Endovasc Surg. 2025;69(4):619-27.

Part I

Perioperative and Technical Aspects of Complex Aortic Aneurysms



Chapter 2

How We Would Treat Our Own Thoracoabdominal Aortic Aneurysm

Titia A.L. Sulzer[1,3], Andrea Vacirca[1], Thomas Mesnard[1], Aidin Baghbani-Oskouei[1], Safa Savadi[1], Lucas Ruiter Karamori[1], Felix van Lier[2], Jorg L. de Bruin[3], Hence J.M. Verhagen[3], Gustavo S. Oderich[1]

[1] Department of Cardiothoracic & Vascular Surgery, Advanced Aortic Research Program at the University of Texas Health Science Center at Houston, McGovern Medical School, Houston, TX.
[2] Department of Anesthesiology, Erasmus University Medical Center, Rotterdam, the Netherlands.
[3] Department of Vascular Surgery, Erasmus University Medical Center, Rotterdam, the Netherlands.

Journal of Cardiothoracic and Vascular Anesthesia, Volume 38, Issue 2, February 2024, pages 379-387
DOI: 10.1053/j.jvca.2023.10.034

Abstract

This manuscript is intended to provide a comprehensive review of the current state of knowledge on endovascular repair of thoracoabdominal aortic aneurysms (TAAAs). The management of these complex aneurysms requires an interdisciplinary and patient-specific approach in high-volume centers. An index case is used to discuss the diagnosis and treatment of a patient undergoing fenestrated-branched endovascular aneurysm repair for a TAAA.

Introduction

Open surgical repair has been the preferred treatment for thoracoabdominal aortic aneurysms (TAAAs) since its initial description in the early 1950s.[1] Presently, this modality is used primarily in young and low-risk patients with genetically triggered aortic diseases. Endovascular repair was introduced in the 1990s as an alternative in elderly and higher-risk patients, and has evolved to an option that should be considered on any patient with suitable anatomy, independent of their clinical risk. Several single and multicenter studies have shown favorable results with low morbidity and mortality rates compared to historical outcomes of open surgical repair.[2-4] The aim of this manuscript is to shed light on the pathophysiology and epidemiology of TAAAs and offer an in-depth insight into the perioperative, intraoperative, and postoperative management of these complex endovascular cases. To exemplify the methodology, the authors will use an index case to show the complexities associated with these procedures.

Case Presentation

A 75-year-old man with a past medical history of hypertension, hypercholesterolemia, body mass index >25, and a history of tobacco use was diagnosed incidentally with a TAAA because of dilated abdominal aorta detected during a screening duplex ultrasound. He had no prior aortic surgeries or other relevant surgical history. Computed tomography angiography (CTA) confirmed a 7-cm extent III TAAA according to Crawford classification (**Fig 1**).[5] The patient had normal baseline renal function.

Review of the Clinical Context

Definition and classification

An aortic aneurysm is an enlargement of the aorta to >1.5 times its normal size.[6] The Crawford classification is used to categorize the extent of aneurysms in the thoracoabdominal segment. The classification system includes 4 types (extent I to IV) and was modified subsequently by Safi to include 5 types. The classification is described elsewhere and is based on the anatomic extent and the extent of open repair, as illustrated in **Fig 1**.[5, 7]

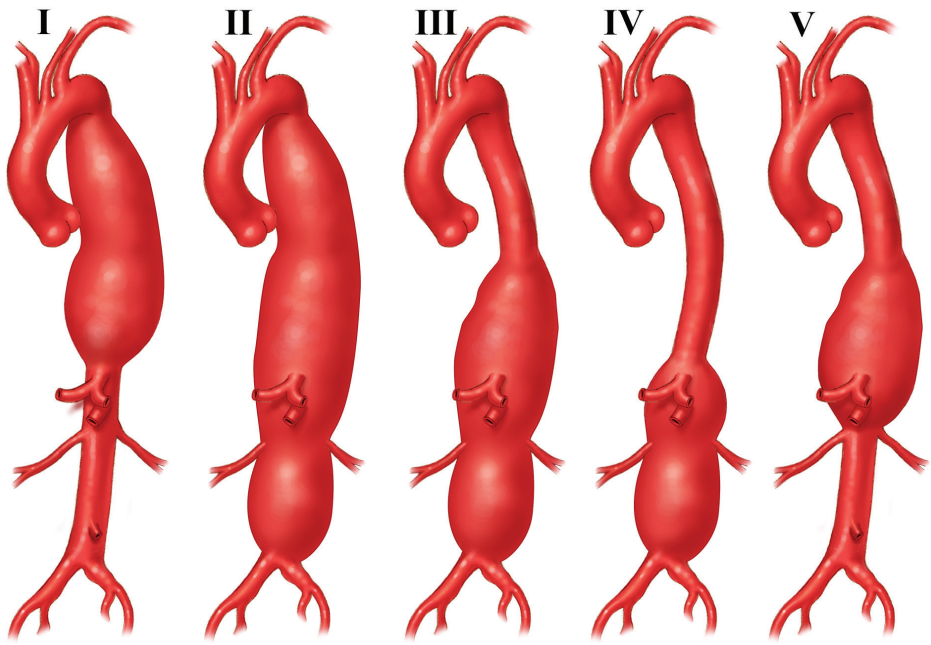

Fig 1. Modified Crawford classification of thoracoabdominal aortic aneurysms, including type V.

Pathophysiology of TAAAs

Although the focus of this review is on operative management, certain factors cannot be ignored. The pathophysiology of TAAAs is a multifaceted process that involves components such as inflammation, proteolysis, matrix injury, and dysfunction and necrosis of smooth muscle cells in the aortic wall, often in the context of underlying genetic abnormalities.[8, 9] The disintegration of the medial layer of the aortic wall and subsequent aneurysm formation is a result of the interplay between cellular and molecular mechanisms (**Fig 2**). Once the diameter of the aorta enlarges, it loses its elasticity and distensibility, causing it to resemble a rigid tube that cannot stretch any further.[10] Consequently, an enlarged, noncompliant aorta will transmit the entire force of each cardiac contraction directly into the wall stress, as the aneurysmal wall is incapable of stretching elastically.[11] In some cases, patients present with a post-dissection TAAA. This is caused by the splitting of the layers of the aortic wall, usually the medial layer, with an evident intimal tear, allowing longitudinal propagation of a false lumen filled with blood.

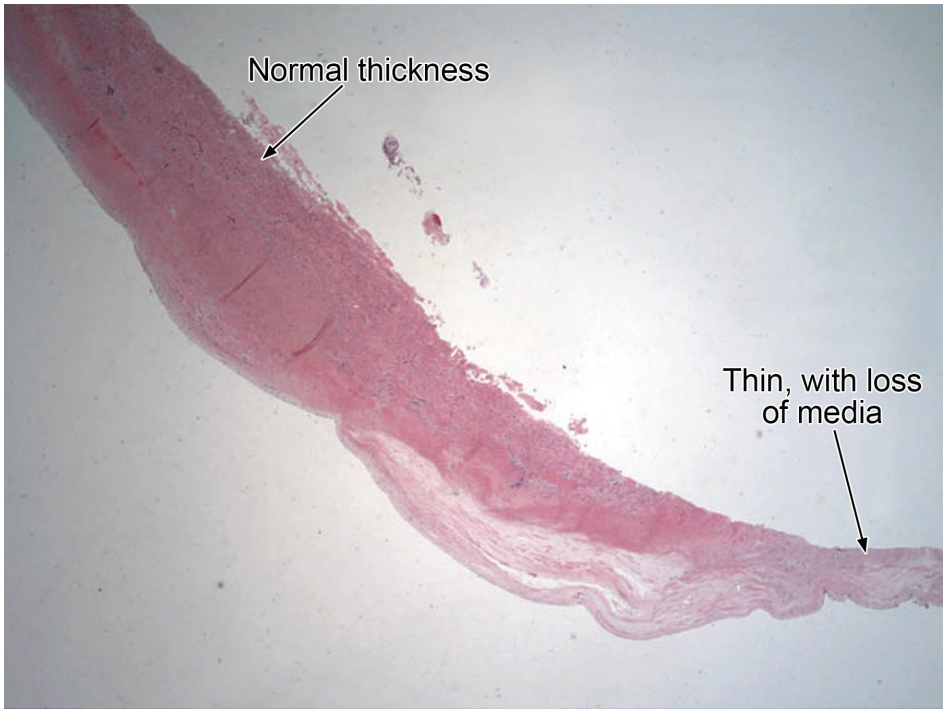

Fig 2. Microscopic image of a cross-section of the aortic wall. A clear transition from a normal to an abnormally thin aorta is seen, which is due to the complete loss of the medial layer of the blood vessel. This causes aneurysmal dilatation of the aorta and ultimately leads to dissection and/or rupture.

Epidemiology, natural history, and diagnosis

The exact incidence and prevalence of TAAAs remain unclear, as there are limited reports in the literature. It is estimated that thoracic aortic aneurysms occur in 5 to 10 per 100,000 person-years, but the true incidence of TAAAs might be higher than currently reported due to the silent nature of the disease.[12] Approximately 20% of TAAAs are related to genetic or heritable conditions. These cases can be classified into the following 2 categories: syndromic and non-syndromic. Syndromic cases are characterized by manifestations in other organs besides the aorta, whereas non-syndromic cases only involve the aorta. Syndromic cases involve conditions such as Marfan syndrome, EhlersDanlos, Turner syndrome, and LoeysDietz syndrome, in which aortic dilatation is one of many symptoms. The non-syndromic category is significantly larger and comprises familial and sporadic cases.[13, 14] Over 90% of TAAAs are asymptomatic and detected incidentally or during screening. The natural history includes the development of symptoms, rupture, dissection, and death.[15] The thoracic location poses a great challenge for diagnosis, often diagnosed by incidental discovery during imaging procedures performed for other purposes. This is in contrast to AAAs, which

are more easily detectable through duplex ultrasound screening. To detect TAAAs, the authors recommend a "guilt-byassociation" approach for individuals harboring a TAAA or at risk of developing a TAAA in the future.[16] For example, TAAAs are associated with conditions such as bicuspid aortic valve, intracranial aneurysm, aortic arch anomalies (e.g., bovine aortic arch, isolated left vertebral artery, and aberrant right subclavian artery), AAAs, temporal arteritis, simple renal cysts, and inguinal hernias (**Fig 3**).[17-24] Eventually, CTA or magnetic resonance imaging is required to adequately visualize and diagnose the TAAAs.

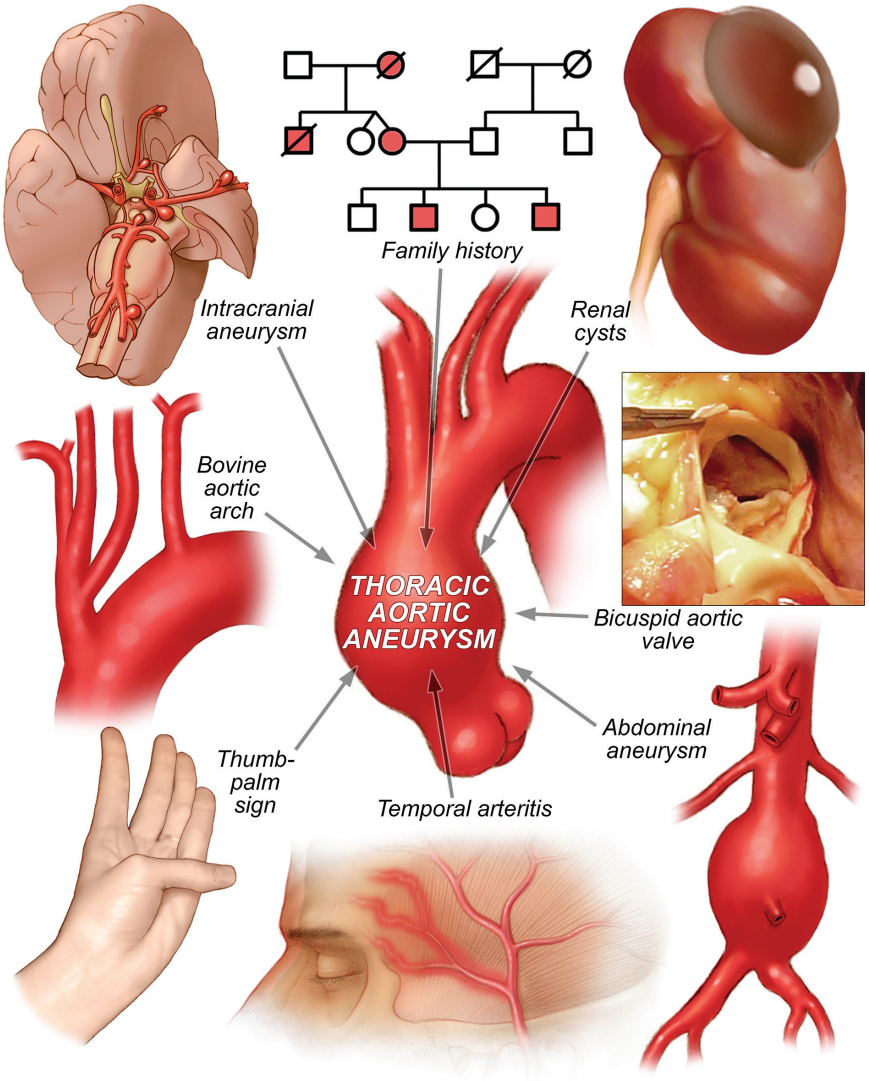

Fig 3. The detection of silent thoracoabdominal aortic aneurysms follows the paradigm of "guilt by association," as demonstrated by the associations with conditions shown in this figure.

Brief Overview of Surgical Treatment of TAAAs

For several decades, open surgical repair was considered the gold standard for the treatment of TAAAs. This continues to be the case in several institutions, but the notion of a 'gold standard' has been challenged by high mortality rates and the favorable outcomes of endovascular approaches. In many centers, open surgical repair has been relegated to younger and fit patients with genetic syndromes and those who are not suitable anatomic candidates for endovascular repair. Open surgical treatment of TAAA has been described extensively elsewhere.[12, 25, 26]

The endovascular repair offers a less invasive approach. The technique requires the placement of modular endovascular stent grafts in healthy segments of the aorta, preventing blood flow from entering the aneurysmal sac and consequently avoiding the risk of rupture. The side branches of the aorta are incorporated using fenestrations or directional branches. The terms fenestrated-branched endovascular aortic repair (FB-EVAR), fenestrated endovascular repair, and branched endovascular repair have been coined to describe variations of stent design used in patients with complex aortic aneurysms such as TAAAs. The use of fenestrations has been preferred in complex abdominal aneurysms with minimal enlargement in the renal and mesenteric segments, whereas branches are used typically with more extensive TAAAs (**Fig 4**). The stent design is selected based on analysis of the patient's anatomy. Over time, the technique evolved from physician-modified endovascular grafts to industry-manufactured patient-specific and off-the-shelf devices. Improvements in device design and the development of specialized aortic centers with perfected techniques and perioperative care have led to significant improvements in clinical outcomes.[2, 27] A patient-specific stent graft takes approximately 6 weeks and cannot be used in urgent cases. The off-the-shelf devices are readily accessible and, therefore, may be suitable for emergency situations if the patient fits the anatomic criteria.[28] Lastly, physician-modified endovascular grafts can be obtained promptly because the operator modifies this graft to suit the patient's anatomy.[29] According to the latest European Clinical Practice Guidelines for the treatment of aortoiliac aneurysms, FB-EVAR is the preferred option for suprarenal aortic aneurysms.[30] The advantages of endovascular repair include an early survival benefit, a reduced risk of complications, faster recovery, and the ability to treat older, frail, and higher-risk patients who were previously not considered suitable candidates for open repair.[31] Large studies on endovascular repair for TAAAs have reported favorable outcomes, including a 30-day mortality rate of only 1% to 3%. Additionally, there have been low incidences of new-onset dialysis (2-6%), paraplegia (1-6%), and major stroke (0.3-2%).[32-37] Before undertaking any form of aortic reconstruction, endovascular or

open surgical, a comprehensive preoperative assessment is necessary, and patients should be discussed in a multidisciplinary team.[30, 38]

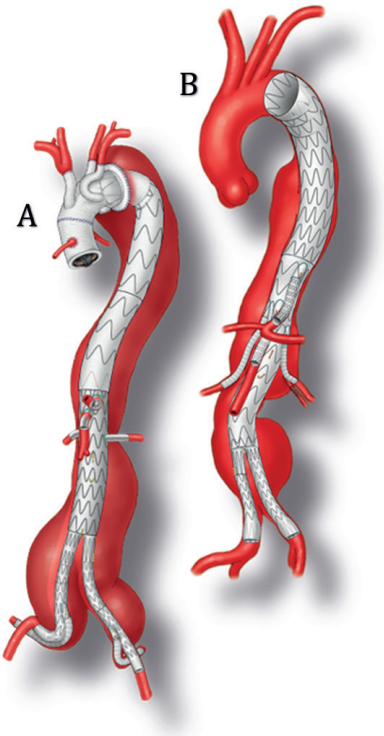

Fig 4. Examples of **(A)** fenestrated endovascular aneurysm repair and **(B)** branched endovascular repair aneurysm repair for thoracoabdominal aortic aneurysms.

Preoperative Workup

All patients undergoing elective endovascular interventions should have a comprehensive preoperative assessment, which includes cardiac, pulmonary, and renal assessment. A CTA of the chest, abdomen, and pelvis with thin cuts is the most important study to analyze the anatomy and extent of involvement (**Table 1**). Accurate distance measurements based on curved planar reconstruction views or straightened centerline of flow multiplanar reconstructions are crucial aspects of preoperative work for planning and sizing a patient's anatomy. Furthermore, the zero-reference point must be established at the center of the 2 highest target vessels, the celiac axis or the superior mesenteric artery. This reference point allows for measurements between target vessels or estimation of stent graft coverage length above each target vessel. The minimum recommended sealing zone for FB-EVAR should be within the range of 15 to 25 mm.[28]

Additionally, a thorough preoperative evaluation must take place to determine the need for perioperative hemodynamic and neurologic monitoring and the need for spinal cord protection.

Table 1. Preoperative assessment for all patient undergoing endovascular interventions

Assessment	Description
History	Age Sex Functional capacity Past medical and surgical history Present and past medication use Smoking status Allergies Alcohol misuse Illicit drug use History of trauma Family history of aneurysm or dissection Marfan's syndrome Connective tissue disorder Aortic dissection
Physical examination	Vital signs Carotid bruit Heart sounds and murmur Lung fields and sounds Abdominal examination Pulse examination
Laboratory studies	Complete blood count BUN and Cr Serum electrolyte values Blood glucose PT, aPTT, INR
Resting 12-lead electrocardiogram	
Ankle-brachial index test	
Imaging studies	Chest radiograph CTA chest, abdomen, and pelvis Duplex ultrasound
Informed consent	

aPTT, activated partial thromboplastin time; *BUN*, blood urea nitrogen; *Cr*, serum creatinine; *CTA*, computed tomographic angiography; *INR*, international normalized ratio; *PT*, prothrombin time.

Spinal cord ischemia (SCI) is a severe complication that can occur as a result of TAAA treatment, regardless of whether endovascular or open surgical repair is performed. It is a consequence of the interruption of flow into segmental and/or collateral arteries that perfuse the spinal cord. Etiologies include ischemic, embolic, and hemorrhagic and can be immediate or several hours or days later.[39] This complication remains the Achilles heel of

TAAA repair even in high-volume and experienced hospitals. The incidence of SCI ranges from 3% to 30%, and it is linked to increased mortality and morbidity.[34, 40-42] A grading system ranging from 0 to 3 is used to classify SCI, with 0 indicating no neurologic deficit, 1 indicating minor sensory deficit with no motor deficit and the ability to walk independently, 2 indicating paraparesis, and 3 indicating paraplegia (**Table 2**).[43] To prevent SCI after endovascular TAAA repair, permissive hypertension with a systolic blood pressure greater than 130 mmHg (or mean arterial pressure no less than 90 mmHg) is recommended.[44] Optimization of oxygen delivery is recommended, including a minimum hemoglobin count of 10 mg/dL.[45,46] Other frequently used modalities are staged repair and the use of neuromonitoring. During staged repair, the surgery is performed in several stages.[47] Thus, collaterals to the spinal cord have the opportunity to proliferate.

Table 2. Spinal cord injury grading system based on the reporting standards for endovascular aortic repair of aneurysms involving the renal-mesenteric arteries

Spinal cord injury	
Grade 0	No neurologic deficit.
Grade 1	Minimal sensory deficit with no motor deficit and ability to walk independently.
Grade 2	Paraparesis; minor motor deficit with ability to walk with assistance or independently. This definition implies that the patient is able to move the extremity against gravity.
Grade 3	Paraplegia: severe motor deficit causing inability to walk (wheelchair bound); should be further classified:
3A	Nonambulatory with ability to move extremities against gravity.
3B	Nonambulatory with ability to move extremity laterally but not against gravity.
3C	Nonambulatory with minimal or no movement.

Neuromonitoring is used to assess the integrity of the corticospinal tract to identify ischemia in the spinal columns during surgery; frequently used are motor-evoked potentials (MEPs), somatosensory evoked potentials (SSEPs), and compound muscle action potential. Although many centers do not use it, the authors strongly advocate the use of neuromonitoring in all complex aortic cases with coverage of ≥4 cm above the celiac axis.[40] This is because it can promptly identify any damage or complications that may occur during the procedure.[48-52] As a result, one can implement cerebrospinal fluid drainage (CSFD) to achieve perfusion to the spinal cord. It's important to note that the presence of an experienced neurophysiologist is essential to manage this process. Lastly, the use of prophylactic CSFD can be used to minimize the risk of SCI.[53] Currently, there is a significant debate about the correct use of the prophylactic CSFD due to severe complications, such as spinal hematomas after placement. In the current

era, there is an ongoing shift from routine use of CSFD for all patients with ≥4 cm stent graft coverage above the celiac axis to a more restrained approach where prophylactic CSFD is used only in patients with a very high risk of SCI.[40] Indicators of high risk include the following: Crawford extent I, II, III TAAA, previous open or endovascular infrarenal aortic surgery, "shaggy" atheromatous aorta, unilateral hypogastric artery occlusion or bilateral hypogastric artery stenosis, and abnormal bilateral vertebral or abnormal left vertebral artery perfusion.[40, 54-56] Nevertheless, some centers are even more cautious and have changed practices to only use therapeutic CSFD for SCI rescue.

Perioperative Management Goals

Anesthesiologists have adapted to treating complex aortic pathology along with vascular surgeons, providing a less invasive alternative for patients who were previously considered inoperable or at high risk of morbidity and mortality. Before the procedure, patients with chronic kidney disease and estimated glomerular filtration rate <60 mL/min or serum creatinine >1.8 mg/dL, as well as those over 80 years old, are preadmitted for intravenous hydration to prevent contrast-induced nephropathy. The use of intravenous hydration has been proven to be most successful when done at least 12 hours before the procedure.[57, 58] The routine use of acetylsalicylic acid and the discontinuation of clopidogrel 7 to 10 days before the surgery is recommended if CSFD placement is anticipated; however, in the authors' experience, this varies per patient.[59, 60] Alternatively, patients can be switched to perioperative use of acetylsalicylic acid. Beta-blockers and statins are continued on the day of surgery. Vasodilator antihypertensive medications are withheld on the day of surgery. For optimal imaging, a hybrid endovascular room with a fixed imaging unit and onlay fusion is recommended. The selection of anesthesia method usually is guided by baseline comorbidities, hemodynamic status, need for complex neurologic monitoring, aneurysm locations, and patient preference. In complex hybrid aortic cases, general anesthesia is favored. When SSEPs or MEPs are used, total intravenous anesthesia is the preferred anesthetic technique with propofol because traditional inhaled anesthetics inhibit the evoked potential signal.[48, 61] Due to the need for an early postoperative neurologic evaluation, it is crucial to strategize a fast-track anesthesia approach. Neuraxial anesthesia is not recommended for this purpose. TEVAR and EVAR, in patients with simple anatomy, can be performed under neuraxial or monitored anesthesia care.[62, 63] These approaches might be beneficial for a selective group of patients by reducing pulmonary complications and transient sympathetic blockade. This results in a reduced surgical stress response when compared to general anesthesia, ultimately contributing to decreased

perioperative complications.[64] Furthermore, intraoperative blood salvage with a cell saver is advised for difficult cases with prolonged operating time. The recommended initial dose of heparin is 100 IU/kg. After the cannulation of the access vessel, patients receive an additional 2,500 to 5,000 IU to maintain an activated clotting time (ACT) of 200 to 250 seconds throughout the procedure. A baseline ACT can be assessed before administering intravenous heparin to assess adequate dose. The ACT should be checked 10 minutes after the administration of heparin and every 30 minutes thereafter. Additional heparin needs to be administered if ACT is fewer than 200 to 250 seconds based on the patient's weight and baseline ACT.[65-67]

Intraoperative Management

The main goals for intraoperative anesthetic management during endovascular TAAA repair are to provide hemodynamic stability and maintain adequate perfusion to vital organs, including the brain, heart, spinal cord, kidneys, and splanchnic organs. Lowering intracranial pressure with a prophylactic CSFD may reduce the risk of SCI and may, therefore, be placed in patients with a high risk of spinal injury. The guidelines for CSFD recommend keeping a cerebrospinal fluid pressure of <10 mmHg, draining approximately 10 to 20 mL/h if the intracranial pressure is higher, and avoiding drainage of large volumes.[12, 68, 69] During the surgery, the clinical neurophysiologist should observe the MEPs to prevent any potential damage to the motor pathway in the brain and spinal cord. If MEPs are planned, neuromuscular blockade should be avoided because it could interfere with the monitoring process. The SSEPs should be monitored carefully to assess the sensory pathway's function in the brain and spinal cord. Finally, they should ensure that the compound muscle action potentials that control the transmission of action potentials in the motor nerves, neuromuscular junction, and muscle function are functioning properly. Details on the use of neuromonitoring have been described extensively elsewhere.[48, 52] It is also essential to maintain euvolemic intravascular volume, monitor for bleeding, and maintain normothermia. In addition to standard monitoring, invasive arterial pressure monitoring in the left or right radial arterial line should be performed during the surgery. In the case of upper-extremity access, intra-aortic pressure also can be measured via a femoral line or sheath. This should be well communicated with the anesthesia team to place the arterial line on the contralateral side. For complex or long procedures, central venous access may be necessary. Additionally, urine output and core temperature must be monitored continuously. Management of perioperative temperature can be challenging, and it is advised to use convective warming and strive to maintain a normal or warm environment in the operating room.[70, 71] In cases where

patients fail to maintain normothermia, warming the intravenous fluids can be useful.[71] Furthermore, although the rate of conversion to open repair is low, anesthesiologists must be prepared for the possibility of massive blood loss.[72] Finally, it is important to mention the complication of endoleaks, which may occur after endovascular repair, causing blood leakage into the aneurysm. A classification system based on the use of fenestrations and directional branches is depicted in **Fig 5**.[28] Technical success assessment is an important step to identify complications during FB-EVAR. With the increasing complexity of stent design and the extent of aneurysms, there are more potential points of failure. With the use of only fusion and cone-beam computed tomography, both intraoperative and early outcomes are improved because it allows for early identification of technical issues that can be resolved during the index procedure.[73, 74] Onlay fusion enhances endovascular navigation and substantially improves the precision of endograft implantation.[75] Cone-beam computed tomography acquires 3dimensional images by rotating a C-arm around the patient.[76]

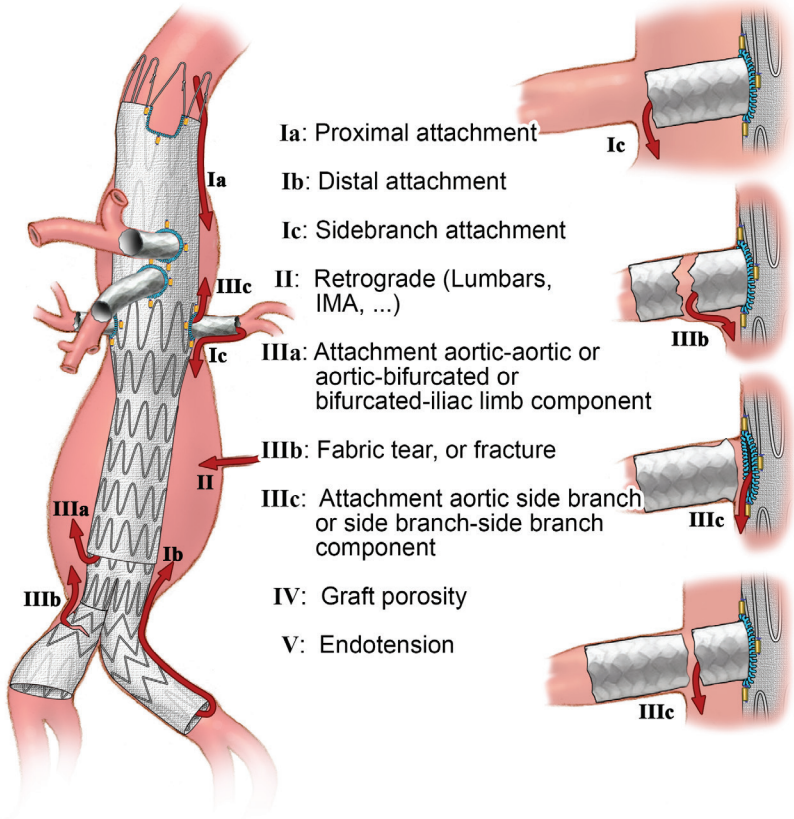

Fig 5. Classification for endoleaks in patients with complex thoracoabdominal aortic aneurysms, maintaining the standard definitions, including type Ia, Ib, II, and IV endoleaks. Additional sites of endoleak can occur with fenestrated and branched stent grafts, such as type Ic and type III.

Postoperative Management

After the procedure, patients in the authors' institution are typically extubated and monitored in the intensive care unit for 2 to 3 days. In their experience, the average length of stay is 4 to 7 days, depending on the extent of repair and patient frailty. Patients may be discharged home once they are able to walk, tolerate an oral diet, and maintain a stable renal function. Moreover, strategies to prevent SCI include abstaining from drugs that reduce blood pressure or using pressor medications to maintain an appropriate mean arterial pressure of ≥90 mmHg and to keep hemoglobin ≥10 g/dl.[77] Neurologic checks must be performed every hour.[40] During placement of the stent-grafts, it is recommended to have patients on aspirin to facilitate the option of CSFD. Once the risk of SCI has subsided, patients can be on dual antiplatelet therapy to maintain target vessel patency. Subsequently, after 3 months, patients can be on a single antiplatelet or P2Y12 receptor inhibitor.[78, 79] The follow-up care involves clinical assessments and imaging (CTA and ultrasound) at 6 to 8 weeks, every 6 months during the first year, and annually thereafter.[80]

Management of Index Case

Due to the age and moderate-high anesthesiologic risk of the patient, an endovascular treatment was considered most appropriate.[81-84] After sizing the case with center lumen line evaluation using CTA, the patient was proposed to be treated with a patient-specific stent graft with a combination of reinforced fenestrations and directional branches due to the extent of the TAAA. After 3 months, the patient underwent general endotracheal anesthesia with neuromonitoring. The patient-specific device was deployed. Fenestrations and directional branches were aligned, and target arteries (celiac artery, superior mesenteric artery, and right and left renal arteries) were incorporated using balloon-expandable stent-grafts. The length of surgery was 190 minutes with a total contrast volume of 150 mL. Intraoperative cone-beam computed tomography showed technical success and no type 1 to 3 endoleaks. The patient was transferred from the operating room to the intensive care unit for 48 hours of monitoring and discharged home 3 days after surgery. Postoperatively, the patient was continued on aspirin treatment, and clopidogrel was started 2 weeks after discharge.

Conclusion

The treatment of choice in patients with TAAAs is endovascular aortic repair using fenestrated-branched aortic endografts due to the lower postoperative mortality and major adverse events rate compared with open repair. However, these procedures carry potential serious postoperative complications, such as spinal cord injury, and, therefore, several measures in the perioperative management of the patient must be adopted by a well-trained multidisciplinary team in a high-volume center.

All illustrations in this chapter were reproduced from Endovascular Aortic Repair: Current Techniques with Fenestrated, Branched, and Parallel Stent-Grafts (text by G.S. Oderich; illustrations by Mr. David Factor), used with permission.

References

1. Crawford ES. Thoraco-abdominal and abdominal aortic aneurysms involving renal, superior mesenteric, celiac arteries. Ann Surg. 1974;179(5):763-72.
2. Oderich GS, Ribeiro MS, Sandri GA, et al. Evolution from physician-modified to company-manufactured fenestrated-branched endografts to treat pararenal and thoracoabdominal aortic aneurysms. J Vasc Surg. 2019;70(1):31-42 e7.
3. Chuter TA, Gordon RL, Reilly LM, et al. An endovascular system for thoracoabdominal aortic aneurysm repair. J Endovasc Ther. 2001;8(1):25-33.
4. Karkkainen JM, Pather K, Tenorio ER, et al. Should endovascular approach be considered as the first option for thoraco-abdominal aortic aneurysms? J Cardiovasc Surg (Torino). 2019;60(3):298-312.
5. Crawford ES, Coselli JS. Thoracoabdominal aneurysm surgery. Semin Thorac Cardiovasc Surg. 1991; 3(4):300-22.
6. Johnston KW, Rutherford RB, Tilson MD, et al. Suggested standards for reporting on arterial aneurysms. Subcommittee on Reporting Standards for Arterial Aneurysms, Ad Hoc Committee on Reporting Standards, Society for Vascular Surgery and North American Chapter, International Society for Cardiovascular Surgery. J Vasc Surg. 1991;13(3):452-8.
7. Safi HJ, Miller CC, 3rd. Spinal cord protection in descending thoracic and thoracoabdominal aortic repair. Ann Thorac Surg. 1999;67(6):1937-9; discussion 53-8.
8. Elefteriades JA. Thoracic aortic aneurysm: reading the enemy's playbook. Yale J Biol Med. 2008;81(4): 175-86.
9. Hellenthal FA, Buurman WA, Wodzig WK, et al. Biomarkers of AAA progression. Part 1: extracellular matrix degeneration. Nat Rev Cardiol. 2009;6(7):464-74.
10. Davis FM, Rateri DL, Daugherty A. Mechanisms of aortic aneurysm formation: translating preclinical studies into clinical therapies. Heart. 2014;100(19):1498-505.
11. Koullias G, Modak R, Tranquilli M, et al. Mechanical deterioration underlies malignant behavior of aneurysmal human ascending aorta. J Thorac Cardiovasc Surg. 2005;130(3):677-83.
12. Isselbacher EM, Preventza O, Hamilton Black J, 3rd, et al. 2022 ACC/AHA Guideline for the Diagnosis and Management of Aortic Disease: A Report of the American Heart Association/American College of Cardiology Joint Committee on Clinical Practice Guidelines. Circulation. 2022;146(24):e334-e482.
13. Coady MA, Davies RR, Roberts M, et al. Familial patterns of thoracic aortic aneurysms. Arch Surg. 1999;134(4):361-7.
14. Pomianowski P, Elefteriades JA. The genetics and genomics of thoracic aortic disease. Ann Cardiothorac Surg. 2013;2(3):271-9.
15. Gouveia EMR, Silva Duarte G, Lopes A, et al. Incidence and Prevalence of Thoracic Aortic Aneurysms: A Systematic Review and Meta-analysis of Population-Based Studies. Semin Thorac Cardiovasc Surg. 2022;34(1):1-16.
16. Elefteriades JA, Sang A, Kuzmik G, et al. Guilt by association: paradigm for detecting a silent killer (thoracic aortic aneurysm). Open Heart. 2015;2(1):e000169.
17. Davies RR, Kaple RK, Mandapati D, et al. Natural history of ascending aortic aneurysms in the setting of an unreplaced bicuspid aortic valve. Ann Thorac Surg. 2007;83(4):1338-44.
18. Kuzmik GA, Feldman M, Tranquilli M, et al. Concurrent intracranial and thoracic aortic aneurysms. Am J Cardiol. 2010;105(3):417-20.
19. Hornick M, Moomiaie R, Mojibian H, et al. 'Bovine' aortic arch – a marker for thoracic aortic disease. Cardiology. 2012;123(2):116-24.
20. Dumfarth J, Chou AS, Ziganshin BA, et al. Atypical aortic arch branching variants: A novel marker for thoracic aortic disease. J Thorac Cardiovasc Surg. 2015;149(6):1586-92.
21. Hultgren R, Larsson E, Wahlgren CM, et al. Female and elderly abdominal aortic aneurysm patients more commonly have concurrent thoracic aortic aneurysm. Ann Vasc Surg. 2012;26(7):918-23.
22. Robson JC, Kiran A, Maskell J, et al. The relative risk of aortic aneurysm in patients with giant cell arteritis compared with the general population of the UK. Ann Rheum Dis. 2015;74(1):129-35.
23. Ziganshin BA, Theodoropoulos P, Salloum MN, et al. Simple Renal Cysts as Markers of Thoracic Aortic Disease. J Am Heart Assoc. 2016;5(1).
24. Olsson C, Eriksson P, Franco-Cereceda A. Association between thoracic aortic disease and inguinal hernia. J Am Heart Assoc. 2014;3(4).

25. Coselli JS, Bozinovski J, LeMaire SA. Open surgical repair of 2286 thoracoabdominal aortic aneurysms. Ann Thorac Surg. 2007;83(2):S862-4; discussion S90-2.
26. Crawford ES, Crawford JL, Safi HJ, et al. Thoracoabdominal aortic aneurysms: preoperative and intraoperative factors determining immediate and long-term results of operations in 605 patients. J Vasc Surg. 1986;3(3):389-404.
27. Greenberg RK, Haulon S, Lyden SP, et al. Endovascular management of juxtarenal aneurysms with fenestrated endovascular grafting. J Vasc Surg. 2004;39(2):279-87.
28. Oderich GS, Forbes TL, Chaer R, et al. Reporting standards for endovascular aortic repair of aneurysms involving the renal-mesenteric arteries. J Vasc Surg. 2021;73(1S):4S-52S.
29. Starnes BW. Physician-modified endovascular grafts for the treatment of elective, symptomatic, or ruptured juxtarenal aortic aneurysms. J Vasc Surg. 2012;56(3):601-7.
30. Wanhainen A, Verzini F, Van Herzeele I, et al. Editor's Choice – European Society for Vascular Surgery (ESVS) 2019 Clinical Practice Guidelines on the Management of Abdominal Aorto-iliac Artery Aneurysms. Eur J Vasc Endovasc Surg. 2019;57(1):8-93.
31. Han Y, Zhang S, Zhang J, et al. Outcomes of Endovascular Abdominal Aortic Aneurysm Repair in Octogenarians: Meta-analysis and Systematic Review. Eur J Vasc Endovasc Surg. 2017;54(4):454-63.
32. Tenorio ER, Oderich GS, Farber MA, et al. Outcomes of endovascular repair of chronic postdissection compared with degenerative thoracoabdominal aortic aneurysms using fenestrated-branched stent grafts. J Vasc Surg. 2020;72(3):822-36 e9.
33. Oderich GS, Tenorio ER, Mendes BC, et al. Midterm Outcomes of a Prospective, Nonrandomized Study to Evaluate Endovascular Repair of Complex Aortic Aneurysms Using Fenestrated-Branched Endografts. Ann Surg. 2021;274(3):491-9.
34. Eagleton MJ, Follansbee M, Wolski K, et al. Fenestrated and branched endovascular aneurysm repair outcomes for type II and III thoracoabdominal aortic aneurysms. J Vasc Surg. 2016;63(4):930-42.
35. Youssef M, Deglise S, Szopinski P, et al. A Multicenter Experience With a New Fenestrated-Branched Device for Endovascular Repair of Thoracoabdominal Aortic Aneurysms. J Endovasc Ther. 2018;25(2): 209-19.
36. Verhoeven EL, Katsargyris A, Bekkema F, et al. Editor's Choice – Ten-year Experience with Endovascular Repair of Thoracoabdominal Aortic Aneurysms: Results from 166 Consecutive Patients. Eur J Vasc Endovasc Surg. 2015;49(5):524-31.
37. Kolbel T, Spanos K, Jama K, et al. Early outcomes of the t-Branch off-the-shelf multi-branched stent graft in 542 patients for elective and urgent aortic pathologies: A retrospective observational study. J Vasc Surg. 2021;74(6):1817-24.
38. Riambau V, Bockler D, Brunkwall J, et al. Editor's Choice – Management of Descending Thoracic Aorta Diseases: Clinical Practice Guidelines of the European Society for Vascular Surgery (ESVS). Eur J Vasc Endovasc Surg. 2017;53(1):4-52.
39. Estrera AL, Miller CC, 3rd, Huynh TT, et al. Preoperative and operative predictors of delayed neurologic deficit following repair of thoracoabdominal aortic aneurysm. J Thorac Cardiovasc Surg. 2003; 126(5):1288-94.
40. Aucoin VJ, Eagleton MJ, Farber MA, et al. Spinal cord protection practices used during endovascular repair of complex aortic aneurysms by the U.S. Aortic Research Consortium. J Vasc Surg. 2021; 73(1):323-30.
41. Griepp RB, Griepp EB. Spinal cord protection in surgical and endovascular repair of thoracoabdominal aortic disease. J Thorac Cardiovasc Surg. 2015;149(2 Suppl):S86-90.
42. Katsargyris A, Oikonomou K, Kouvelos G, et al. Spinal cord ischemia after endovascular repair of thoracoabdominal aortic aneurysms with fenestrated and branched stent grafts. J Vasc Surg. 2015; 62(6):1450-6.
43. Fillinger MF, Greenberg RK, McKinsey JF, et al. Reporting standards for thoracic endovascular aortic repair (TEVAR). J Vasc Surg. 2010;52(4):1022-33 e15.
44. Weissler EH, Voigt SL, Raman V, et al. Permissive Hypertension and Collateral Revascularization May Allow Avoidance of Cerebrospinal Fluid Drainage in Thoracic Endovascular Aortic Repair. Ann Thorac Surg. 2020;110(5):1469-74.
45. Hnath JC, Mehta M, Taggert JB, et al. Strategies to improve spinal cord ischemia in endovascular thoracic aortic repair: Outcomes of a prospective cerebrospinal fluid drainage protocol. J Vasc Surg. 2008;48(4):836-40.

46. Svensson LG, Crawford ES, Hess KR, et al. Experience with 1509 patients undergoing thoracoabdominal aortic operations. J Vasc Surg. 1993;17(2):357-68; discussion 68-70.
47. Dias-Neto M, Tenorio ER, Huang Y, et al. Comparison of single- and multistage strategies during fenestrated-branched endovascular aortic repair of thoracoabdominal aortic aneurysms. J Vasc Surg. 2023;77(6):1588-97 e4.
48. Sloan TB, Edmonds HL, Jr., Koht A. Intraoperative electrophysiologic monitoring in aortic surgery. J Cardiothorac Vasc Anesth. 2013;27(6):1364-73.
49. van Dongen EP, Schepens MA, Morshuis WJ, et al. Thoracic and thoracoabdominal aortic aneurysm repair: use of evoked potential monitoring in 118 patients. J Vasc Surg. 2001;34(6):1035-40.
50. de Haan P, Kalkman CJ. Spinal cord monitoring: somatosensory- and motor-evoked potentials. Anesthesiol Clin North Am. 2001;19(4):923-45.
51. Horiuchi T, Kawaguchi M, Inoue S, et al. Assessment of intraoperative motor evoked potentials for predicting postoperative paraplegia in thoracic and thoracoabdominal aortic aneurysm repair. J Anesth. 2011;25(1):18-28.
52. Jacobs MJ, Mess W, Mochtar B, et al. The value of motor evoked potentials in reducing paraplegia during thoracoabdominal aneurysm repair. J Vasc Surg. 2006;43(2):239-46.
53. Banga PV, Oderich GS, Reis de Souza L, et al. Neuromonitoring, Cerebrospinal Fluid Drainage, and Selective Use of Iliofemoral Conduits to Minimize Risk of Spinal Cord Injury During Complex Endovascular Aortic Repair. J Endovasc Ther. 2016;23(1):139-49.
54. Feezor RJ, Martin TD, Hess PJ, Jr., et al. Extent of aortic coverage and incidence of spinal cord ischemia after thoracic endovascular aneurysm repair. Ann Thorac Surg. 2008;86(6):1809-14; discussion 14.
55. Baril DT, Carroccio A, Ellozy SH, et al. Endovascular thoracic aortic repair and previous or concomitant abdominal aortic repair: is the increased risk of spinal cord ischemia real? Ann Vasc Surg. 2006; 20(2):188-94.
56. Ullery BW, Cheung AT, Fairman RM, et al. Risk factors, outcomes, and clinical manifestations of spinal cord ischemia following thoracic endovascular aortic repair. J Vasc Surg. 2011;54(3):677-84.
57. Solomon R, Werner C, Mann D, et al. Effects of saline, mannitol, and furosemide on acute decreases in renal function induced by radiocontrast agents. N Engl J Med. 1994;331(21):1416-20.
58. Nijssen EC, Rennenberg RJ, Nelemans PJ, et al. Prophylactic hydration to protect renal function from intravascular iodinated contrast material in patients at high risk of contrast-induced nephropathy (AMACING): a prospective, obilizati, phase 3, controlled, open-label, non-inferiority trial. Lancet. 2017;389(10076):1312-22.
59. Douketis JD, Spyropoulos AC, Murad MH, et al. Perioperative Management of Antithrombotic Therapy: An American College of Chest Physicians Clinical Practice Guideline. Chest. 2022;162(5):e207-e43.
60. Mazzeffi MA, Lee K, Taylor B, et al. Perioperative management and monitoring of antiplatelet agents: a focused review on aspirin and P2Y(12) inhibitors. Korean J Anesthesiol. 2017;70(4):379-89.
61. Keyhani K, Miller CC, 3rd, Estrera AL, et al. Analysis of motor and somatosensory evoked potentials during thoracic and thoracoabdominal aortic aneurysm repair. J Vasc Surg. 2009;49(1):36-41.
62. Panossian VS, Berro MM, Ismail AM, et al. General Versus Locoregional Anesthesia in TEVAR: An NSQIP Analysis. Ann Vasc Surg. 2023;90:109-18.
63. Broos PP, Stokmans RA, Cuypers PW, et al. Effects of Anesthesia Type on Perioperative Outcome After Endovascular Aneurysm Repair. J Endovasc Ther. 2015;22(5):770-7.
64. Edwards MS, Andrews JS, Edwards AF, et al. Results of endovascular aortic aneurysm repair with general, regional, and local/monitored anesthesia care in the American College of Surgeons National Surgical Quality Improvement Program database. J Vasc Surg. 2011;54(5):1273-82.
65. Norgren L, Hiatt WR, Dormandy JA, et al. Inter-Society Consensus for the Management of Peripheral Arterial Disease (TASC II). J Vasc Surg. 2007;45 Suppl S:S5-67.
66. Hirsh J, Anand SS, Halperin JL, et al. Guide to anticoagulant therapy: Heparin : a statement for healthcare professionals from the American Heart Association. Circulation. 2001;103(24):2994-3018.
67. Bernelli C, Chieffo A, Montorfano M, et al. Usefulness of baseline activated clotting time-guided heparin administration in reducing bleeding events during transfemoral transcatheter aortic valve implantation. JACC Cardiovasc Interv. 2014;7(2):140-51.
68. Scott CK, Timaran DE, Malekpour F, et al. Selective Versus Routine Spinal Drain Use for Fenestrated/Branched Endovascular Aortic Repair (F-BEVAR). Ann Vasc Surg. 2021;76:168-73.

69. Stokland O, Miller MM, Ilebekk A, et al. Mechanism of hemodynamic responses to occlusion of the descending thoracic aorta. Am J Physiol. 1980;238(4):H423-9.
70. Kurz A, Sessler DI, Lenhardt R. Perioperative normothermia to reduce the incidence of surgical-wound infection and shorten hospitalization. Study of Wound Infection and Temperature Group. N Engl J Med. 1996;334(19):1209-15.
71. Smith CE, Desai R, Glorioso V, et al. Preventing hypothermia: convective and intravenous fluid warming versus convective warming alone. J Clin Anesth. 1998;10(5):380-5.
72. Blankensteijn JD, de Jong SE, Prinssen M, et al. Two-year outcomes after conventional or endovascular repair of abdominal aortic aneurysms. N Engl J Med. 2005;352(23):2398-405.
73. Tenorio ER, Oderich GS, Sandri GA, et al. Prospective nonrandomized study to evaluate cone beam computed tomography for technical assessment of standard and complex endovascular aortic repair. J Vasc Surg. 2020;71(6):1982-93 e5.
74. Hertault A, Maurel B, Sobocinski J, et al. Impact of hybrid rooms with image fusion on radiation exposure during endovascular aortic repair. Eur J Vasc Endovasc Surg. 2014;48(4):382-90.
75. McNally MM, Scali ST, Feezor RJ, et al. Three-dimensional fusion computed tomography decreases radiation exposure, procedure time, and contrast use during fenestrated endovascular aortic repair. J Vasc Surg. 2015;61(2):309-16.
76. Dijkstra ML, Eagleton MJ, Greenberg RK, et al. Intraoperative C-arm cone-beam computed tomography in fenestrated/branched aortic endografting. J Vasc Surg. 2011;53(3):583-90.
77. Afshari FT, Choi D, Russo A. Controversies regarding obilization and rehabilitation following acute spinal cord injury. Br J Neurosurg. 2020;34(2):123-6.
78. Fedorow CA, Moon MC, Mutch WA, et al. Lumbar cerebrospinal fluid drainage for thoracoabdominal aortic surgery: rationale and practical considerations for management. Anesth Analg. 2010;111(1):46-58.
79. Tibi P, McClure RS, Huang J, et al. STS/SCA/AmSECT/SABM Update to the Clinical Practice Guidelines on Patient Blood Management. J Cardiothorac Vasc Anesth. 2021;35(9):2569-91.
80. Tenorio ER, Oderich GS, Sandri GA, et al. Impact of onlay fusion and cone beam computed tomography on radiation exposure and technical assessment of fenestrated-branched endovascular aortic repair. J Vasc Surg. 2019;69(4):1045-58 e3.
81. Ellahi A, Shaikh FN, Kashif H, et al. Effectiveness of endovascular repair versus open surgery for the treatment of thoracoabdominal aneurysm: A systematic review and meta analysis. Ann Med Surg (Lond). 2022;81:104477.
82. Locham S, Dakour-Aridi H, Nejim B, et al. Outcomes and cost of open versus endovascular repair of intact thoracoabdominal aortic aneurysm. J Vasc Surg. 2018;68(4):948-55 e1.
83. Rocha RV, Lindsay TF, Austin PC, et al. Outcomes after endovascular versus open thoracoabdominal aortic aneurysm repair: A population-based study. J Thorac Cardiovasc Surg. 2021;161(2):516-27 e6.
84. Rocha RV, Friedrich JO, Elbatarny M, et al. A systematic review and meta-analysis of early outcomes after endovascular versus open repair of thoracoabdominal aortic aneurysms. J Vasc Surg. 2018; 68(6):1936-45 e5.



Chapter 3

Intraoperative Complications During Standard and Complex Endovascular Aortic Repair

Titia A.L. Sulzer[1,2], Emanuel R. Tenorio[1], Thomas Mesnard[1], Andrea Vacirca[1], Aidin Baghbani-Oskouei[1], Jorg L. de Bruin[2], Hence J.M. Verhagen[2], Gustavo S. Oderich[1]

[1] Department of Cardiothoracic & Vascular Surgery, Advanced Aortic Research Program at the University of Texas Health Science Center at Houston, McGovern Medical School, Houston, TX.
[2] Department of Vascular Surgery, Erasmus University Medical Center, Rotterdam, the Netherlands.

Seminars in Vascular Surgery, Volume 36, Issue 2,
June 2023, pages 189-201
DOI: 10.1053/j.semvascsurg.2023.04.002

Abstract

This study aimed to provide a comprehensive overview of the most common intraoperative adverse events that occur during standard endovascular repair and fenestrated-branched endovascular repair to treat abdominal aortic aneurysms, thoracoabdominal aortic aneurysms, and aortic arch aneurysms. Despite advancements in endovascular techniques, sophisticated imaging and improved graft designs, intraoperative difficulties still occur, even in highly standardized procedures and high-volume centers. This study emphasized that with the increased adoption and complexity of endovascular aortic procedures, strategies to minimize intraoperative adverse events should be protocolized and standardized. There is a need for robust evidence on this topic, which could potentially optimize treatment outcomes and durability of the available techniques.

Introduction

Endovascular aortic repair (EVAR) and fenestrated-branched endovascular aortic repair (FB-EVAR) have been widely used as alternatives to open surgical repair for treatment of abdominal aortic aneurysms (AAAs), complex AAAs, thoracoabdominal aortic aneurysms (TAAAs), and aortic arch aneurysms.[1-3] In the past several decades, graft designs have improved considerably and progress has been made in the application of endovascular techniques. The initial use of physician-modified endografts eventually led to the adoption of commercially produced, off-the-shelf, and patient-specific custom-made endografts.[4] Due to refinements in endovascular tools; improved skill set; and the emergence of hybrid operating rooms with advanced imaging applications, such as onlay fusion and cone-beam computed tomography (CBCT), technical success has increased and most immediate technical issues can be identified and resolved.[5]

Despite these advancements, intraoperative difficulties occur, even in highly standardized procedures performed by expert surgeons in high-volume centers. Especially when these techniques are applied in patients with difficult anatomies. Moreover, because FB-EVAR requires multiple concurrent steps, the risk of inadvertent complications is higher. There are few reports dealing with intraoperative complications, as most studies focused on postoperative outcomes. In this article, we aimed to provide a comprehensive review of the most common technical intraoperative adverse events (IAEs) during these procedures.

Intra-Operative Adverse Events

A large single center study by Tenorio and colleagues defined IAEs as any intraoperative complication or technical problem occurring during initial arterial access, implantation and cannulation of the aorta and its branches. These also include problems related to arterial closure and those associated with additional or unplanned interventions.[6] IAEs can be classified into three categories: access, target artery (TA) and graft-related (**Fig 1**).[6] **Supplemental Table 1** contains a comprehensive list of all additional literature sources.

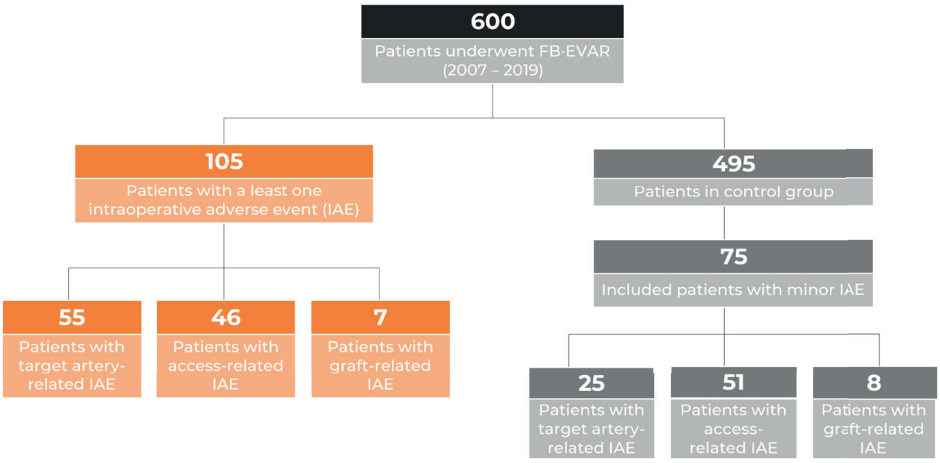

Fig 1. Flow chart showing the rates of intraoperative adverse events of the single-center study of Tenorio and colleagues.[6] *FB-FEVAR*, fenestrated-branched endovascular aortic repair.

Access complications

Access is an essential component of any endovascular procedure regardless of complexity. Currently, percutaneous access of the femoral artery has become the preferred technique in most centers. It has been associated with lower risk of complications, shorter operating time and less blood loss as compared to open surgical exposure and repair of the femoral artery.[7] Studies from Buck and colleagues and Nelson and associates found 96% success rates in patients treated by percutaneous EVAR (pEVAR), these results were in line with standard femoral approach.[8, 9] A systematic review of Malkawi and associates found among 1,087 pEVAR patients a success rate of 92%, and low rates of access related complications (4.4%).[10] Failure of the closure device has been associated with use of larger profile sheaths (>20F), patient obesity, small access vessel diameter (<5 mm), previous groin procedures, access vessel tortuosity, type of closure devices, femoral artery calcification and groin scars.[11, 12] Therefore, preoperative evaluation using clinical and imaging assessment is essential.[13]

Tenorio and associates reported access-related IAEs in 8% of patients treated by FB-EVAR. These complications included not only issues from percutaneous closure, but any problem related to the access vessels, ranging from dissection of iliac, femoral, and brachial arteries (3.5%), vessel perforation or disruption (2%), conversion from percutaneous to open femoral approach (1.5%) and iliofemoral occlusion/stenosis (1%).[6] Similarly, Cochennec and colleagues reported an incidence of access related IAEs in 9% of patients related to iliac or graft limb occlusion (4.5%), common femoral artery iatrogenic occlusion (3.5%), and iliac injury (1%).[14] De Souza and colleagues reported

technical success of percutaneous closure in 94 of 102 FB-EVAR patients, with a conversion rate to open femoral of 5%. A variety of reasons led to insufficient hemostasis, such as puncturing above or through the inguinal ligament, tears/dissections in the artery caused by calcified plaque, or difficulty in placing the percutaneous suture due to scar tissue.[15]

Several studies have demonstrated the cost-effectiveness of pEVAR compared to open surgical exposure. pEVAR has been found to reduce operative time and overall hospital length of stay, resulting in lower overall costs. Therefore, pEVAR is regarded as a cost-effective alternative to open surgical exposure.[16, 17]

Comparing brachial or axillary artery access with femoral access, the use of brachial or axillary access has been associated with lower rates of access-related complications, including hematoma and bleeding. However, the use of these upper extremity access sites may increase the risk of other complications, such as stroke, vessel dissection and brachial plexus injury.[18, 19]

Accidental disruption of the iliac arteries during access carries a risk of severe complications, such as uncontrolled hemorrhage and severe hypotension with increased risk of spinal cord injury in complex cases. It is preferable to plan for an iliac artery conduit in patients with a hostile artery defined by extensive (>50%) calcification, acute iliac angle, occlusive disease, an external iliac artery diameter of less than 7 mm, and/or previous iliofemoral grafts, than to have an inadvertent rupture requiring conversion to open repair.[20-22] Use of covered stent-grafts allows rapid control of hemorrhage but may require coverage of the internal iliac artery, an important collateral to the spinal cord. When percutaneous technique is not successful, immediate conversion is necessary. A large sheath can be reinserted through a small incision in the groin to avoid bleeding during cutdown after closure failure, depending on type of closure device used.[15]

Target artery complications

Complex aneurysms requiring endovascular incorporation of the renal and mesenteric arteries by parallel grafts or fenestrated-branched stent-grafts are especially susceptible to risk of vessel perforation, dissection or occlusion. Regardless of which technique is selected, stenting of renal and mesenteric arteries requires increased catheter manipulation and its success is dependent on vessel diameter, tortuosity, angulation and absence of occlusive disease.[23, 24]

In the study of Tenorio and associates, 9% of patients experienced at least one target artery complication during FB-EVAR, ranging from vessel perforation or disruption of

the splenic artery, superior mesenteric artery or renal arteries (3.5%), dissection of the mesenteric and renal arteries (2.8%), failure to cannulate mesenteric or renal arteries (1.7%) to vessel occlusion or severe stenosis (1%).[6] Cochennec and colleagues found that 19% of patients treated by FB-EVAR had similar issues with target artery incorporation.[14]

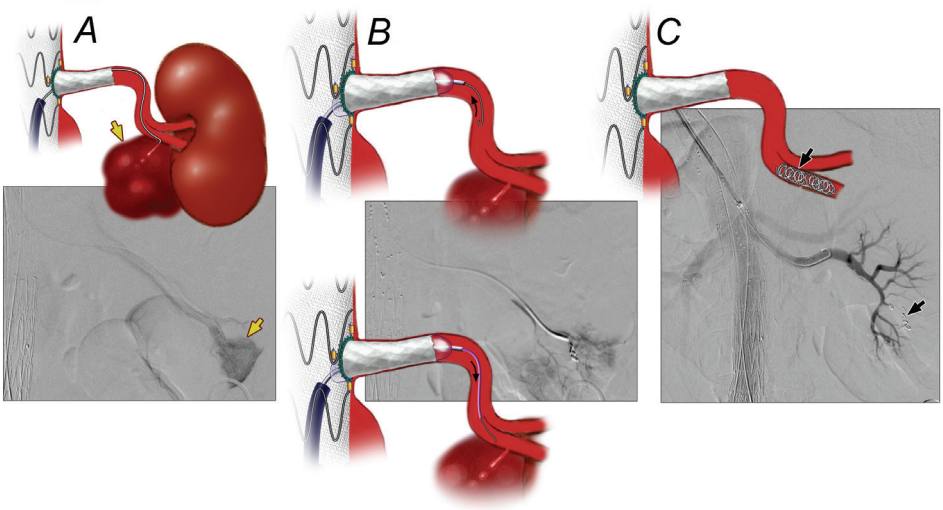

Fig 2. Distal left renal side branch perforation during target artery cannulation **(A)**. A balloon is inflated in the bridging stent to limit bleeding **(B)** and the branch is selectively embolized with coils **(C)**.

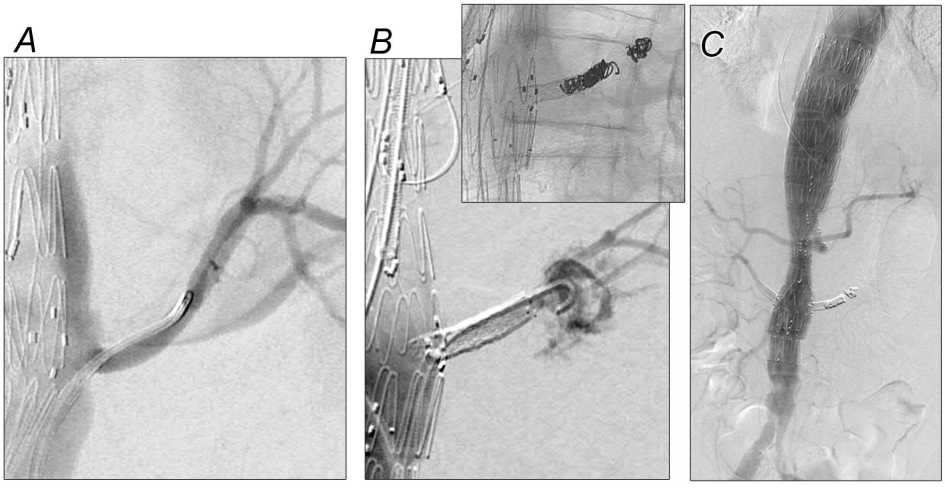

Fig 3. Angiography before left renal artery (LRA) incorporation (pre-cannulated) **(A)**. Iatrogenic disruption of the LRA after bridging stent deployment leading to retroperitoneal hematoma and bleeding **(B)** requiring prompt main trunk coiling (B). No evidence of ongoing bleeding on the completion angiography **(C)**.

Predisposing factors for perforation, disruption and dissection during target artery incorporation are small vessel diameter, atherosclerotic occlusive disease of the target vessel, and early vessel bifurcation. Immediate recognition and treatment are necessary. Focal dissections may be treated by placement of a self-expandable stent (**Fig 2-6**). Perforation and disruption of target vessels may need coiling of side branches or occluding the complete target vessel.

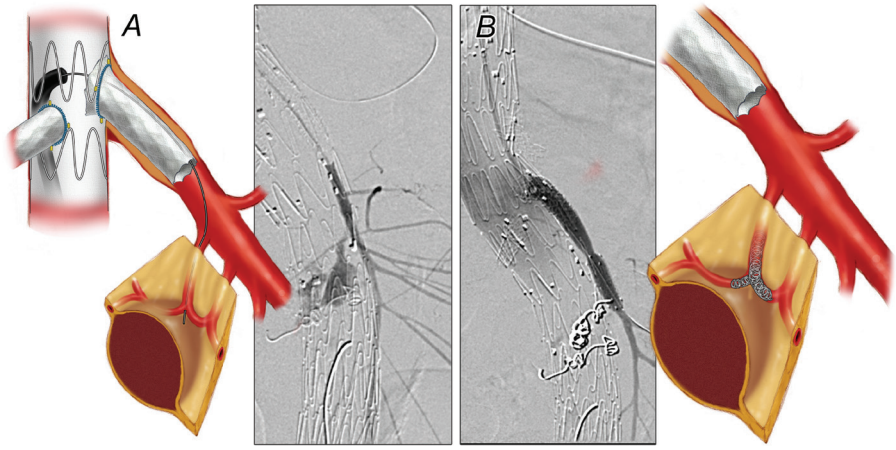

Fig 4. Distal superior mesenteric artery side branch perforation during target artery cannulation **(A)**, leading to intramesenteric bleeding. The side branch is selectively embolized with coils **(B)**.

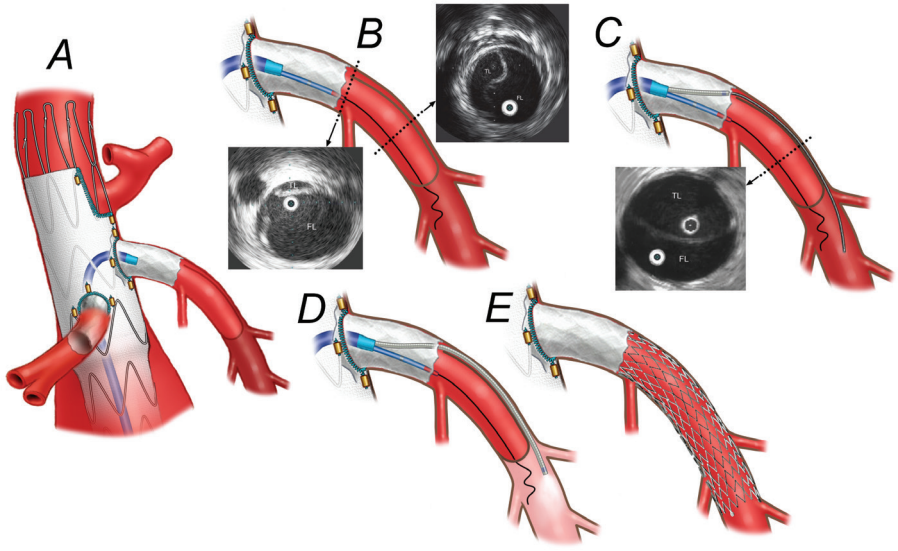

Fig 5. Superior mesenteric iatrogenic dissection distally to the bridging stent diagnosed with intravascular ultrasound **(A, B, C)**. The true lumen is selectively catheterized **(D)** and an adjunct self-expandable bare stent is deployed to treat the dissection **(E)**.

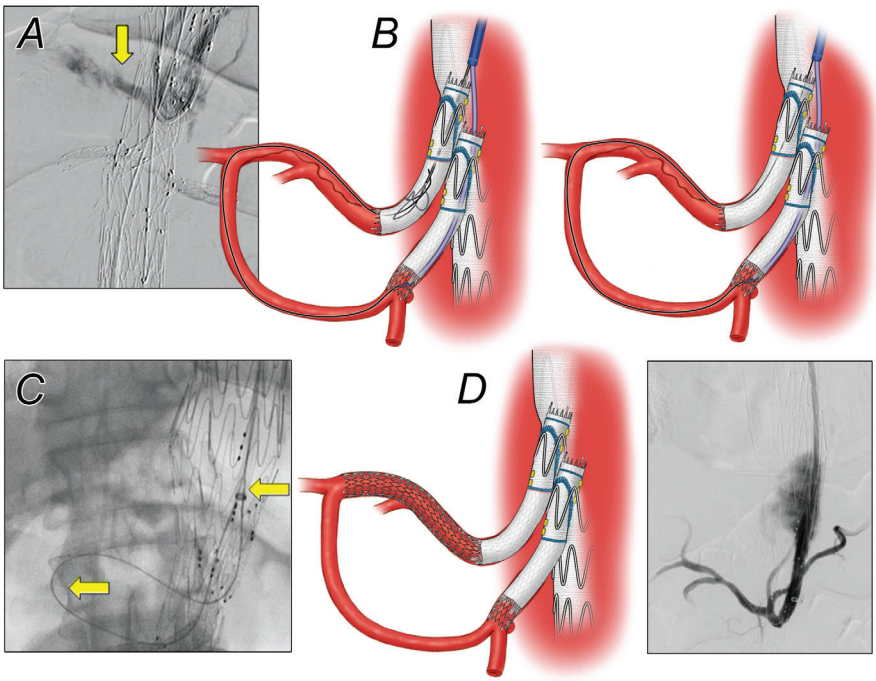

Fig 6. Celiac axis (CA) iatrogenic dissection and occlusion diagnosed on selective angiography **(A)**. Pancreaticoduodenal collaterals are used for retrograde access to the CA **(B)**, cannulation of the true lumen and then the guide wire is snared **(C)** and a self-expandable bare metal stent is deployed to treat the dissection **(D)**.

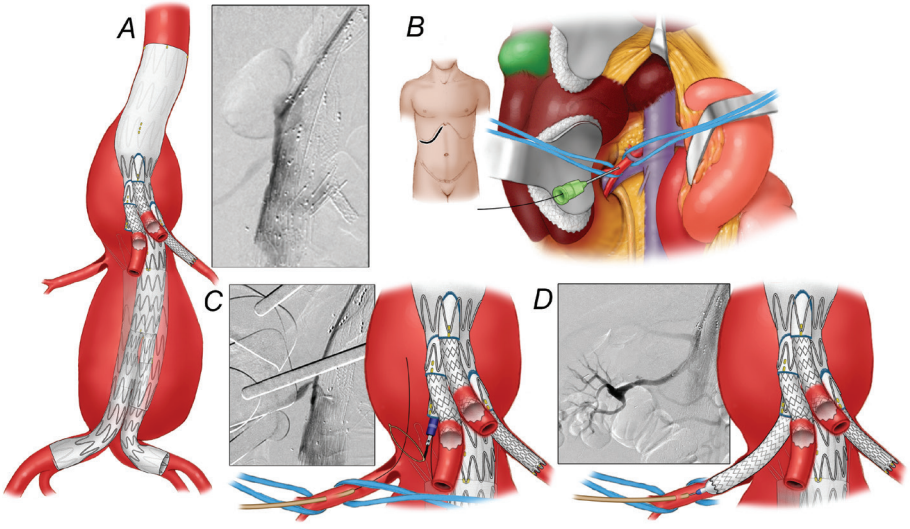

Fig 7. Failure to cannulate the right renal artery (RRA) because of tight ostial stenosis **(A)**. A right subcostal incision is performed to approach the RRA. Retrograde puncture of the RRA with a micropuncture needle **(B)**. Snaring of the guide wire through the right renal branch allows for RRA incorporation **(C, D)**.

Because an essential aspect of these procedures is successful cannulation and stenting of mesenteric and renal vessels, failure to cannulate target arteries can lead to kidney failure and mesenteric ischemia (**Fig 7**).[25] Therefore it is important that the endovascular team is equipped to treat these complications, rescue the target artery and maintain the visceral perfusion. In a few patients, surgical conversion and use of a hybrid approach allows open surgical access to the target artery (renal or mesenteric vessels) for retrograde endovascular stenting or repair of a dissection (**Fig 8**).

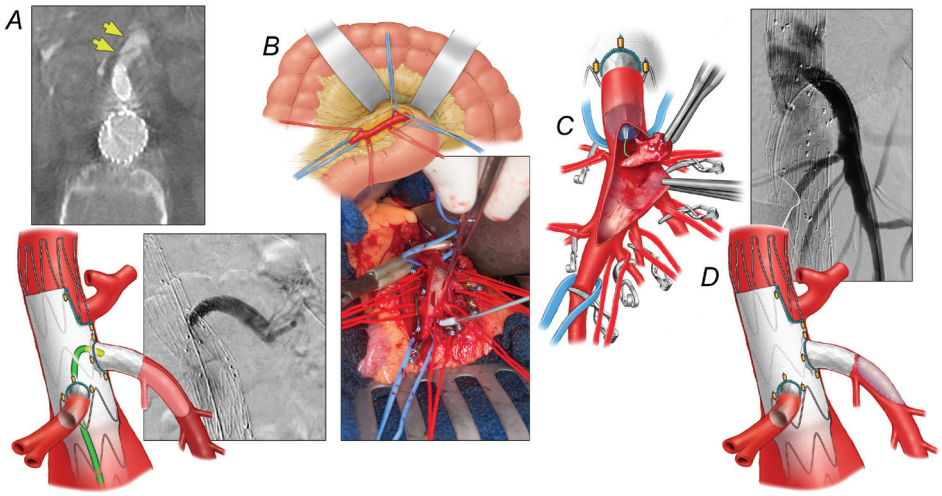

Fig 8. Iatrogenic dissection of the superior mesenteric artery (SMA) diagnosed on cone-beam computed tomography; selective angiography confirms SMA acute occlusion **(A)**. The SMA is approached through a median laparotomy and cross-clamped **(B)**. The arterial flap is gently removed **(C)** and the arteriotomy is closed with a vein patch **(D)**. Final selective shows the patency of the SMA.

Graft-related complications

Graft-related complications include difficulty in the deployment or positioning the device with an incidence ranging from 2-5%.[26] Furthermore, graft kinking has a reported incidence of 0.5-2% patients and can result in stenosis, graft thrombosis and occlusion. Kinks that are identified during EVAR are likely due to tortuosity of the iliac vessels or stump-angled aortic bifurcation.[27] Of all cases of graft limb occlusion, limb kink was present in 42.8%, according to a systematic review of Coelho and colleagues.[28] To prevent occlusion, immediate treatment of kinks is necessary.

Infolding during EVAR, is considered a rare graft-related complication. Excessive oversizing may increase the risk of infolding. Due to a reduction in blood flow or obstruction emergency repair is typically required in these cases.[29] Lastly, unintentional coverage of the renal arteries during graft deployment in EVAR is a severe IAE, which can have

devastating consequences, though it is rare with a current incidence of less than 1%.[30, 31] As bail out techniques, an open by-pass or endovascular (chimney) repair may be used, based on the accessibility of the renal orifice.[32, 33]

Seven patients in the study by Tenorio and colleagues experienced graft related IAEs during FB-EVAR. Infolding of the aortic device occurred in three patients, and four patients had misalignments. No cases of graft-related kinks were observed.[6] The stent grafts used for FEVAR are usually made slightly larger than the intended diameter of the aorta to ensure proper sealing. When the stent graft is oversized around the renal arteries, it may result in infolding, a rare but serious complication that can lead to type 1a endoleaks and compromise of the branch vessels (**Fig 9-10**).[34, 35]

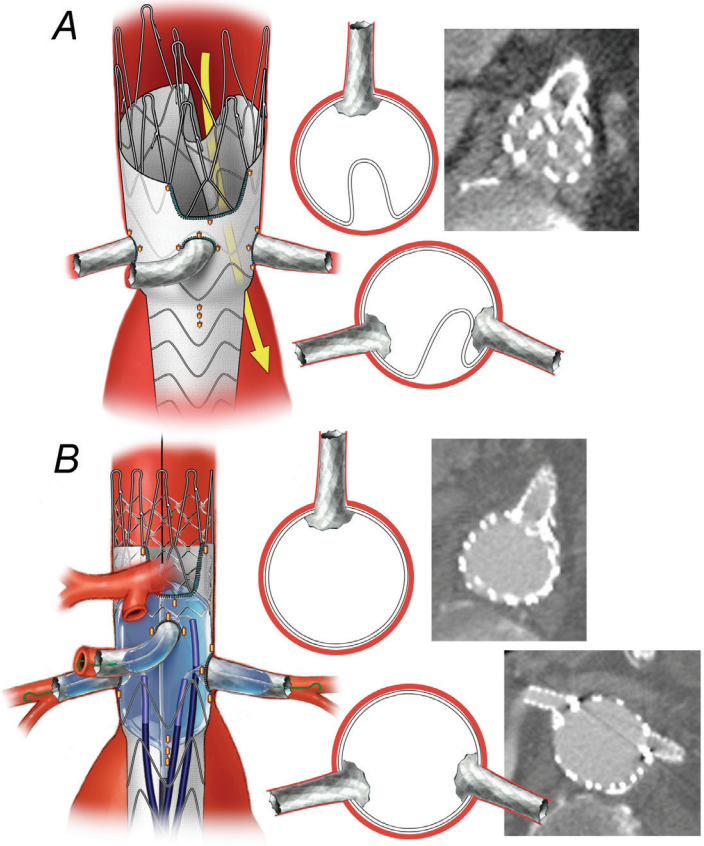

Fig 9. Infolding of the proximal aspect of the fenestrated component leading to Type IA endoleak, diagnosed on final cone-beam computed tomography (CBCT) **(A)**. To avoid bridging stent compression, the renal and mesenteric bridging stents are selectively recannulated and ballooned, while the proximal sealing zone is inflated with a compliant balloon **(B)**. Final CBCT show complete deployment of the fenestrated stent graft and aortic wall apposition.

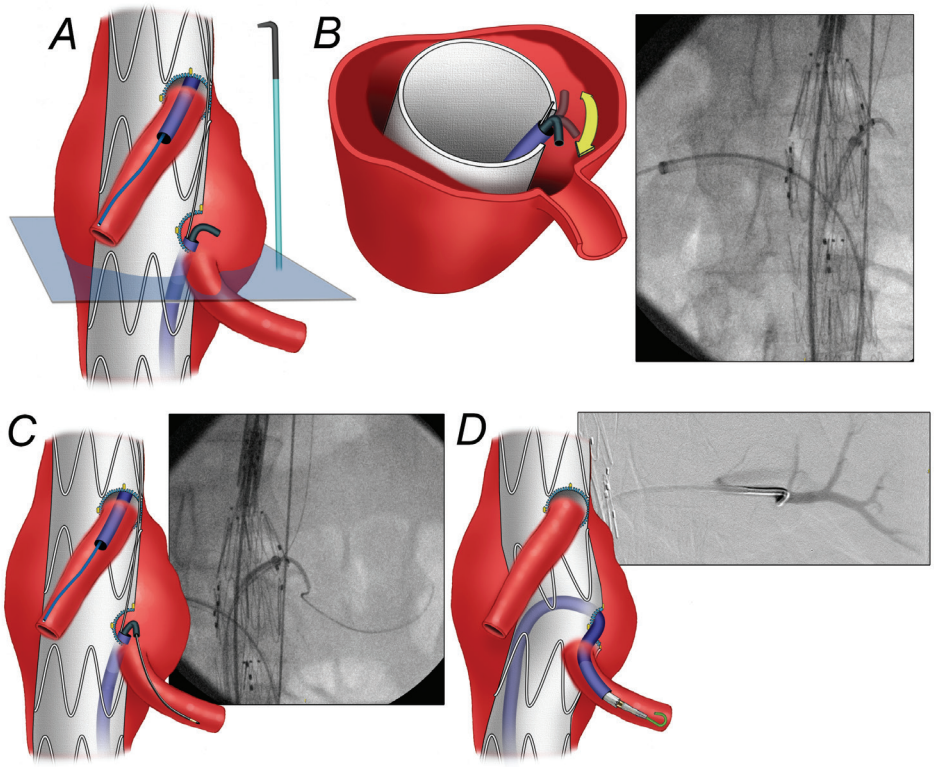

Fig 10. Misalignment of the left renal fenestration, which is too high and posteriorly positioned **(A)**. A 90-degree angulated catheter is used to cannulate the target vessel **(B, C)** and advance the bridging stent into a sheath placed into the side branch to avoid stent dislodgement **(D)**.

Accurate placement of the fenestration of the main aortic stent during FB-EVAR requires accurate identification of the target vessels using angiography, pre-catheterization, or fusion imaging. This is followed by selective catheterization of the fenestrated target vessels through the aortic device while the graft is not fully deployed and diameter reducing ties are still in place (**Fig 11**).[36] Although manufactured fenestrated stent-grafts undergo thorough quality control and are specifically designed to fit the patient's anatomy, factors such as neck angulation, tortuosity and errors in design can still lead to misalignment between the fenestration and the intended vessel (**Fig 12-13**).[37] Directional branch misalignment is infrequent, and typically caused by design errors or variations in patient's anatomy.

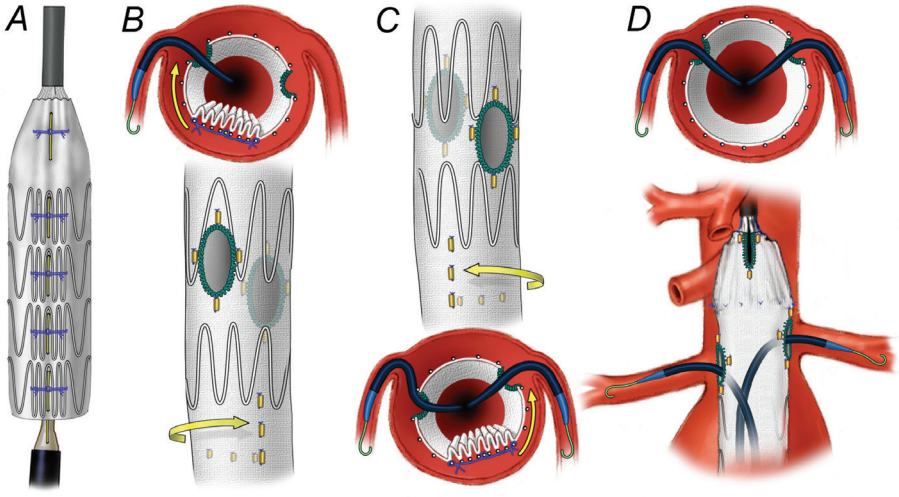

Fig 11. The diameter-reducing ties **(A)** modify the orientation of the renal fenestrations posteriorly **(B)**. Successively the stent-graft is rotated **(B, C)** to orientate the fenestration anteriorly to assist renal arteries cannulation **(D)**.

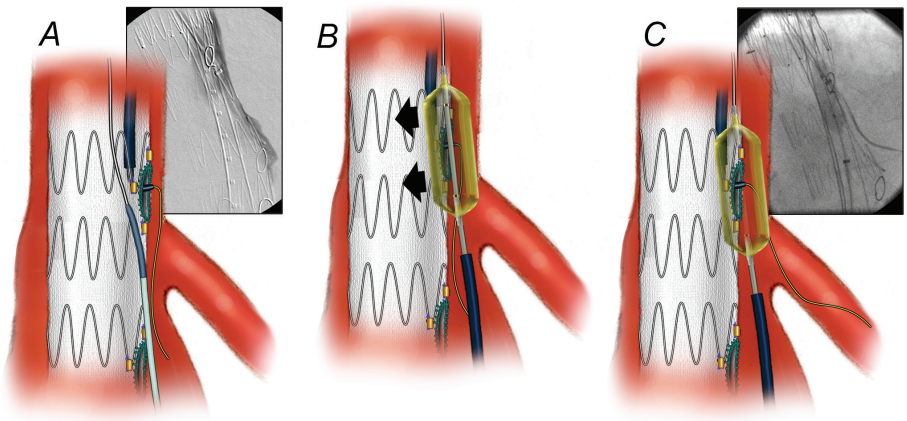

Fig 12. Misalignment of the superior mesenteric artery (SMA) fenestration, which is too highly positioned, the stent-graft is against the aortic wall **(A)**. A 6-mm balloon is inflated between the stent-graft and the aortic wall to create more room and allow for SMA cannulation **(B, C)**.

Recognizing and preventing kinks is important as they are one of the main causes of secondary interventions.[38] During the procedure, compression of the stent-graft can occur because of certain maneuvers. Particularly during the advancement of the bifurcated component, a conflict of the nosecone of the delivery system can crush the endoaortic portion of a fenestration bridging stent. It can also occur with the use of a large dilator to place an iliac limb extension. CBCT without contrast is valuable for detecting kinks and compression (**Fig 14-15**).[5] Stent dislodgement should be

recognized as soon as it occurs to prevent complications such as endoleaks, occlusion, or migration (**Fig 16**).[39] Stent migration refers to the movement of the stent graft from its original position within the aorta. This can occur due to inadequate fixation to the vessel wall, anatomical variations in the aorta. Stent migration can cause obstruction of blood flow to vital organs. To address this issue, bailout techniques such as partially ballooning the migrated stent to move it back to its original position, adding more stents to secure the migrated stent to the aortic wall, or converting to open surgery may be necessary. Therefore, it is important for practitioners to select appropriate stent graft size and shape and use appropriate techniques for sealing. Moreover, proximal extension by an additional graft or cuff might be a good bailout option as well.

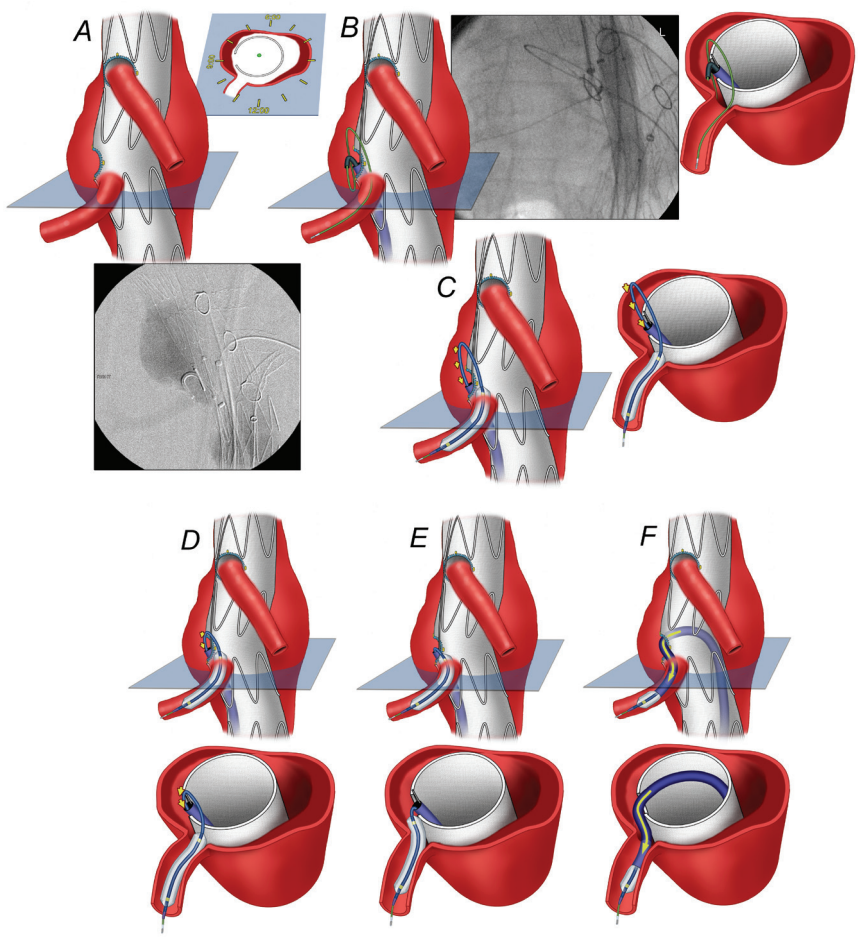

Fig 13. Misalignment of the right renal artery fenestration because of a highly angulated paravisceral aorta **(A)**. A 90-degree angulated catheter is used to cannulate the target vessel **(B)**. A balloon is then inflated at the origin of the target artery **(C)**. The balloon is gently pulled back **(D)** to better align the fenestration and the target artery **(E)** and deflated to "swallow" the sheath **(F)**.

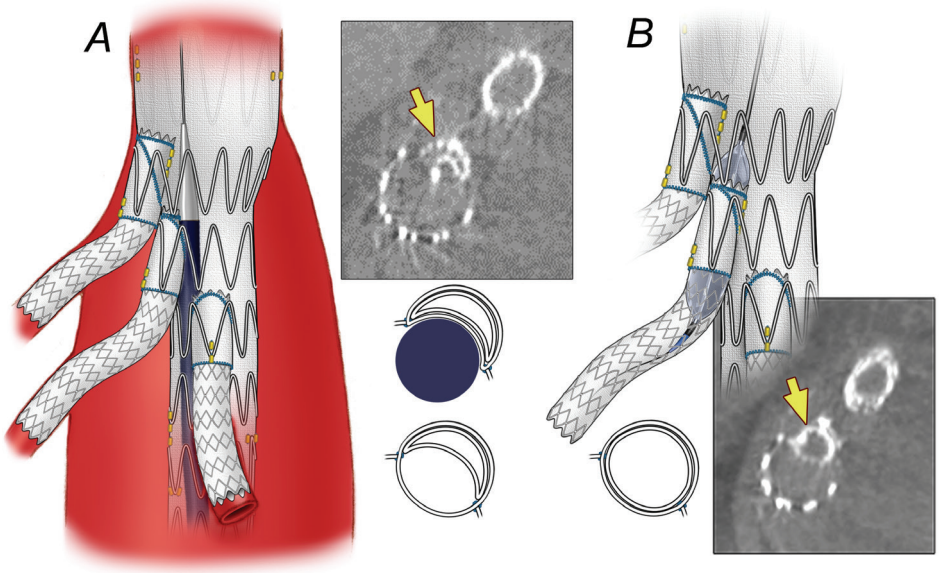

Fig 14. Compression of the superior mesenteric artery bridging stent within the branch due to a crush of the nose cone of the bifurcated graft delivery system, imaged on final cone-beam computed tomography **(A)**. The branch is ballooned to treat the stent kink **(B)**.

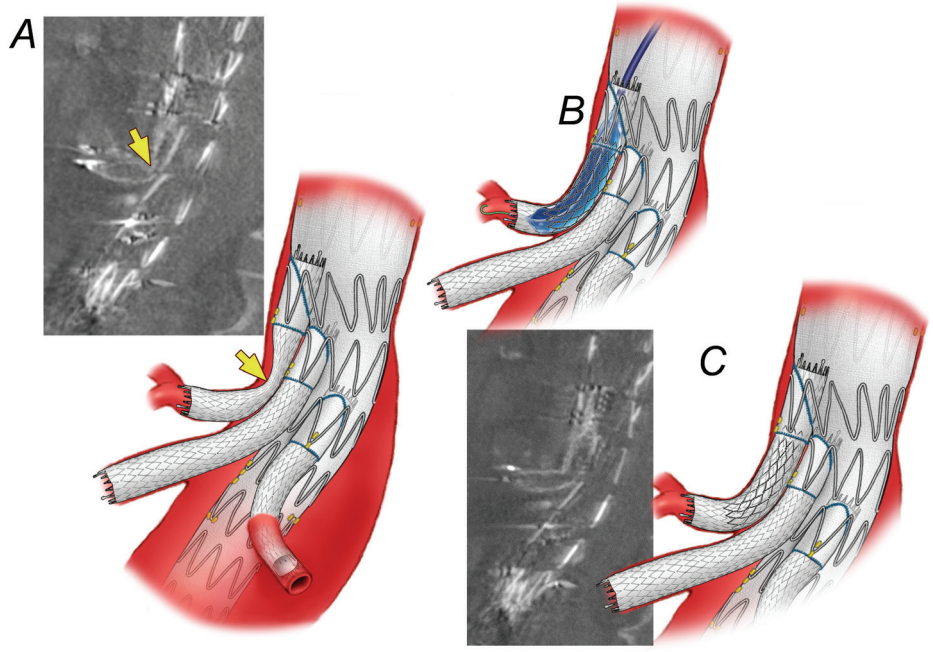

Fig 15. Kink of the celiac axis bridging stent diagnosed on final cone-beam computed tomography **(A)** and successfully treated with an adjunct balloon-expandable bare metal stent to increase radial force **(B, C)**.

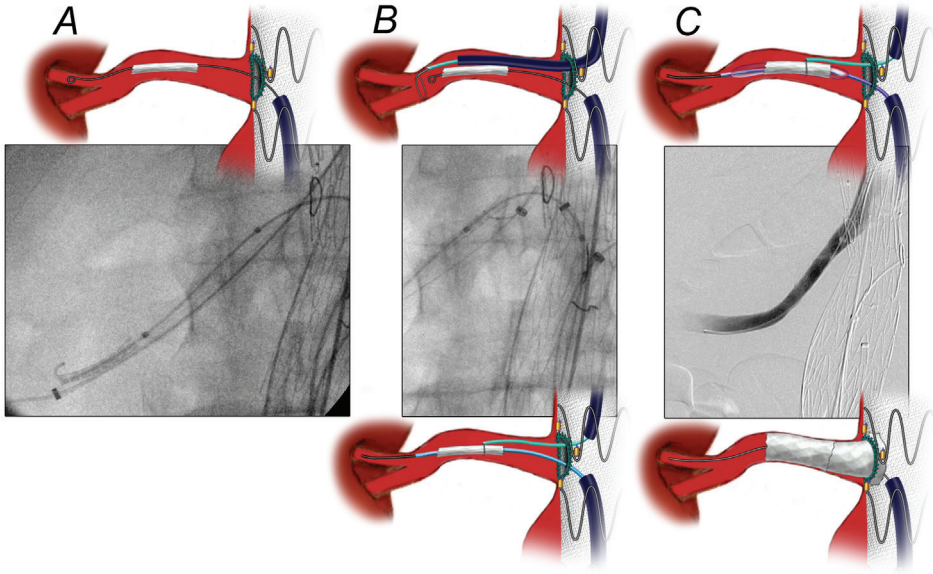

Fig 16. Right renal bridging stent dislodgement from the balloon **(A)**. The fenestration and artery are cannulated through another access and the stent is snared **(B)**. The snare is gently tightened around the snare and the balloon is advanced inside the stent and deployed **(C)**.

Intraoperative embolic events

Intraoperative embolic events during EVAR and FB-EVAR can occur when microembolization of cholesterol fragments, or macroscopic particles of thrombus and plaque become dislodged during the procedure and are carried to other parts of the body. These particles can potentially cause serious complications such as loss of renal function, bowel infarction, stroke, myocardial infarction, spinal cord injury (SCI), or limb ischemia.[40] Embolic events can occur during the deployment of the stent graft or during the removal of the guide wires or catheters. Patients with a "shaggy aorta", characterized by extreme aortic wall thrombus (AWT), have a higher risk of solid organ infarction, acute kidney injury (AKI), and long-term renal dysfunction. They may benefit from a more extensive coverage of the aorta, preferably staged repair. Open surgical repair may also be considered if the patient is suitable for the procedure.[41,42] To avoid arterial thrombosis during the procedure patients, receive an intravenous bolus of heparin (100 units/kg) at the start of surgery, and multiple drips throughout the surgery. The frequency varies between patient's weight, age and overall health status, as well as specific details of the procedure.[42]

Technical Assessment

Technical assessment is an important step in identifying IAEs during EVAR and FB-EVAR. The technical assessment involves evaluating the following aspects: positioning and integrity of the stent-graft, flow through the stent-graft, patency of the renal-mesenteric vessels, and presence of endoleaks. With the increasing complexity of stent design and extent of repair, there are more potential points of failure. These problems are often not easily identified by digital subtraction angiography (DSA), such as the specific location of an endoleak. Additionally, problems in stent architecture, like kinks or compressions are difficult to detect by DSA alone. Several studies have demonstrated that the use of onlay-fusion and CBCT improves both intraoperative and early outcomes. However, it is important to highlight that the use of CBCT comes with increased radiation exposure. Therefore, practitioners must be diligent in their efforts to minimize radiation exposure to both patients and providers, even as technical advances continue to evolve.[5, 43-46] In addition, intravascular ultrasound (IVUS) can be adjunctively used to assess position and orientation of the graft and stents in the vessels. Although, IVUS is frequently used to verify the true lumen in dissected aorta's, it can also help ensure the graft is properly aligned and deployed, which can reduce the risk of migration, endoleaks and other complications. While IVUS sounds promising, more research is required to understand its effectiveness and optimal use.[47-49]

Impact of Intraoperative Adverse Events on Outcomes

In the study of Tenorio and colleagues approximately 64% of the patients with IAEs required additional procedures to treat the complications. Furthermore, IAEs were associated with higher rates of major adverse events (MAEs), lower freedom from secondary intervention, and a three times higher risk of target artery instability. There were no significant differences in freedom from all-cause mortality at 5 years for patients with and without IAEs.[6] The study of Cochennec and colleagues revealed that 30-day mortality was not different for patients with and without IAEs (3.5% vs. 4.4%).[14]

Future

Concurrent with the learning curve of EVAR and FB-EVAR, a significant decrease in adverse events and improved outcomes have been reported. It is important to perform these procedures in high-volume specialized centers to achieve best available outcomes and reduce failure to rescue (**Fig 17**).[49-51] As stent designs become more complex and

the extent of repairs increases, the potential of IAEs also increases. However, one of the major advantages of using CBCT is that it allows for early identification of technical issues that could be resolved before requiring additional procedures.[5]

Conclusions

With the increased adoption and complexity of endovascular aortic procedures, strategies to minimize IAEs should be protocolized and standardized according to the latest evidence. There is a need for robust evidence on this topic, as this would potentially optimize treatment outcomes and durability of the available techniques.

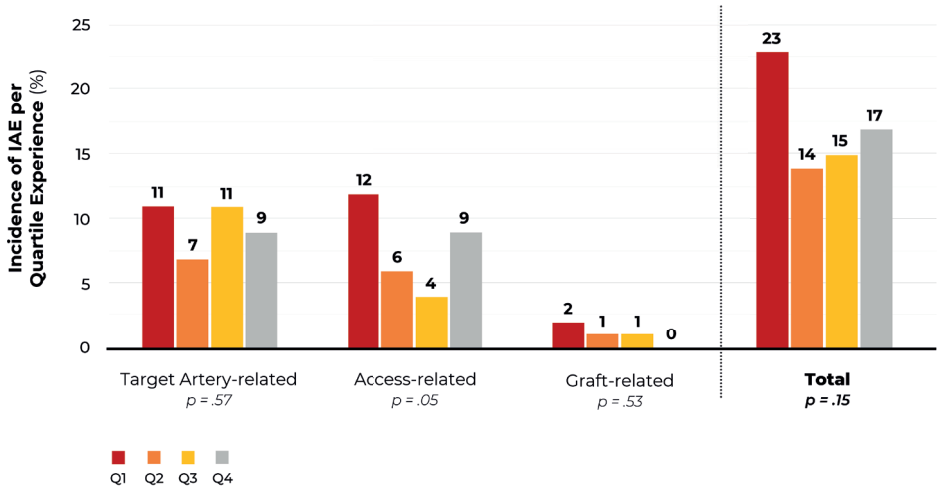

Fig 17. Bar graphs with incidence of intraoperative adverse events (IAEs) by quartile of experience of the single-center study of Tenorio and colleagues6, showing a downward trend in IAEs as the quartile experience increases.

All illustrations in this chapter were drawn by Mr. David Factor. Used with permission.

References

1. Rocha RV, Lindsay TF, Friedrich JO, Shan S, Sinha S, Yanagawa B, et al. Systematic review of contemporary outcomes of endovascular and open thoracoabdominal aortic aneurysm repair. J Vasc Surg. 2020;71(4):1396-412 e12.
2. Eagleton MJ, Follansbee M, Wolski K, Mastracci T, Kuramochi Y. Fenestrated and branched endovascular aneurysm repair outcomes for type II and III thoracoabdominal aortic aneurysms. J Vasc Surg. 2016;63(4):930-42.
3. Resch T, Sonesson B, Malina M. Incidence and management of complications after branched and fenestrated endografting. J Cardiovasc Surg (Torino). 2010;51(1):105-13.
4. Oderich GS, Ribeiro MS, Sandri GA, Tenorio ER, Hofer JM, Mendes BC, et al. Evolution from physician-modified to company-manufactured fenestrated-branched endografts to treat pararenal and thoracoabdominal aortic aneurysms. J Vasc Surg. 2019;70(1):31-42 e7.
5. Tenorio ER, Oderich GS, Sandri GA, Ozbek P, Karkkainen JM, Macedo TA, et al. Impact of onlay fusion and cone beam computed tomography on radiation exposure and technical assessment of fenestrated-branched endovascular aortic repair. J Vasc Surg. 2019;69(4):1045-58 e3.
6. Tenorio ER, Balachandran PW, Marcondes GB, Lima GBB, Boba LM, Mendes BC, et al. Incidence, predictive factors, and outcomes of intraprocedure adverse events during fenestrated-branched endovascular aortic repair of complex abdominal and thoracoabdominal aortic aneurysms. J Vasc Surg. 2022;75(3):783-93 e4.
7. Minion DJ, Davenport DL. Access techniques for EVAR: percutaneous techniques and working with small arteries. Semin Vasc Surg. 2012;25(4):208-16.
8. Buck DB, Karthaus EG, Soden PA, Ultee KH, van Herwaarden JA, Moll FL, et al. Percutaneous versus femoral cutdown access for endovascular aneurysm repair. J Vasc Surg. 2015;62(1):16-21.
9. Nelson PR, Kracjer Z, Kansal N, Rao V, Bianchi C, Hashemi H, et al. A multicenter, randomized, controlled trial of totally percutaneous access versus open femoral exposure for endovascular aortic aneurysm repair (the PEVAR trial). J Vasc Surg. 2014;59(5):1181-93.
10. Malkawi AH, Hinchliffe RJ, Holt PJ, Loftus IM, Thompson MM. Percutaneous access for endovascular aneurysm repair: a systematic review. Eur J Vasc Endovasc Surg. 2010;39(6):676-82.
11. Teh LG, Sieunarine K, van Schie G, Goodman MA, Lawrence-Brown M, Prendergast FJ, et al. Use of the percutaneous vascular surgery device for closure of femoral access sites during endovascular aneurysm repair: lessons from our experience. Eur J Vasc Endovasc Surg. 2001;22(5):418-23.
12. Eisenack M, Umscheid T, Tessarek J, Torsello GF, Torsello GB. Percutaneous endovascular aortic aneurysm repair: a prospective evaluation of safety, efficiency, and risk factors. J Endovasc Ther. 2009;16(6):708-13.
13. Fiorucci B, Tsilimparis N, Rohlffs F, Heidemann F, Debus SE, Kolbel T. Tips and tricks in vascular access for (T)EVAR. J Cardiovasc Surg (Torino). 2017;58(2):194-203.
14. Cochennec F, Kobeiter H, Gohel MS, Majewski M, Marzelle J, Desgranges P, et al. Impact of intraoperative adverse events during branched and fenestrated aortic stent grafting on postoperative outcome. J Vasc Surg. 2014;60(3):571-8.
15. de Souza LR, Oderich GS, Banga PV, Hofer JM, Wigham JR, Cha S, et al. Outcomes of total percutaneous endovascular aortic repair for thoracic, fenestrated, and branched endografts. J Vasc Surg. 2015;62(6):1442-9 e3.
16. Thurston JS, Camara A, Alcasid N, White SB, Patel PJ, Rossi PJ, et al. Outcomes and Cost Comparison of Percutaneous Endovascular Aortic Repair versus Endovascular Aortic Repair With Open Femoral Exposure. J Surg Res. 2019;240:124-9.
17. Hong JC, Yang GK, Delarmente BA, Khera R, Price J, Faulds J, et al. Cost-minimization study of the percutaneous approach to endovascular aortic aneurysm repair. J Vasc Surg. 2020;71(2):444-9.
18. Mirza AK, Oderich GS, Sandri GA, Tenorio ER, Davila VJ, Karkkainen JM, et al. Outcomes of upper extremity access during fenestrated-branched endovascular aortic repair. J Vasc Surg. 2019;69(3):635-43.
19. Meertens M, Laturnus J, Ling A, Atkinson N, Mees B, Wagner T. Percutaneous Axillary Artery Access in Complex Endovascular Aortic Repair. J Vasc Interv Radiol. 2019;30(6):830-5.
20. Rowse JW, Morrow K, Bena JF, Eagleton MJ, Parodi FE, Smolock CJ. Iliac conduits remain safe in complex endovascular aortic repair. J Vasc Surg. 2019;70(2):424-31.

21. Gallitto E, Gargiulo M, Faggioli G, Pini R, Mascoli C, Freyrie A, et al. Impact of iliac artery anatomy on the outcome of fenestrated and branched endovascular aortic repair. J Vasc Surg. 2017;66(6):1659-67.
22. Giannopoulos S, Malgor RD, Sobreira ML, Siada SS, Rodrigues D, Al-Musawi M, et al. Iliac Conduits for Endovascular Treatment of Aortic Pathologies: A Systematic Review and Meta-analysis. J Endovasc Ther. 2021;28(4):499-509.
23. Mendes BC, Oderich GS, Reis de Souza L, Banga P, Macedo TA, DeMartino RR, et al. Implications of renal artery anatomy for endovascular repair using fenestrated, branched, or parallel stent graft techniques. J Vasc Surg. 2016;63(5):1163-9 e1.
24. Karkkainen JM, Tenorio ER, Pather K, Mendes BC, Macedo TA, Wigham J, et al. Outcomes of Small Renal Artery Targets in Patients Treated by Fenestrated-Branched Endovascular Aortic Repair. Eur J Vasc Endovasc Surg. 2020;59(6):910-7.
25. Kapahnke S, Burger M, Torsello GF, Omran S, Hinterseher I, Greiner A, et al. Cannulation of Visceral Vessels Using a Steerable Sheath in Fenestrated and Branched Aortic Endografts. Ann Vasc Surg. 2022;85:305-13.
26. Drury D, Michaels JA, Jones L, Ayiku L. Systematic review of recent evidence for the safety and efficacy of elective endovascular repair in the management of infrarenal abdominal aortic aneurysm. Br J Surg. 2005;92(8):937-46.
27. Fransen GA, Desgranges P, Laheij RJ, Harris PL, Becquemin JP, Collaborators E. Frequency, predictive factors, and consequences of stent-graft kink following endovascular AAA repair. J Endovasc Ther. 2003;10(5):913-8.
28. Coelho A, Nogueira C, Lobo M, Gouveia R, Campos J, Augusto R, et al. Impact of Post-EVAR Graft Limb Kinking in EVAR Limb Occlusion: Aetiology, Early Diagnosis, and Management. Eur J Vasc Endovasc Surg. 2019;58(5):681-9.
29. Schurink GW, Aarts NJ, van Baalen JM, Schultze Kool LJ, van Bockel JH. Stent attachment site-related endoleakage after stent graft treatment: An in vitro study of the effects of graft size, stent type, and atherosclerotic wall changes. J Vasc Surg. 1999;30(4):658-67.
30. Greenberg RK, Chuter TA, Lawrence-Brown M, Haulon S, Nolte L, Zenith I. Analysis of renal function after aneurysm repair with a device using suprarenal fixation (Zenith AAA Endovascular Graft) in contrast to open surgical repair. J Vasc Surg. 2004;39(6):1219-28.
31. Gu N, Grab JG, Moore RD. Rapid endovascular bailout revascularization of the renal arteries with a steerable guiding sheath after endovascular abdominal aortic aneurysm repair. J Vasc Surg Cases Innov Tech. 2021;7(3):572-6.
32. Adu J, Cheshire NJ, Riga CV, Hamady M, Bicknell CD. Strategies to tackle unrecognized bilateral renal artery occlusion after endovascular aneurysm repair. Ann Vasc Surg. 2012;26(8):1127 e1-7.
33. Varetto G, Castagno C, Quaglino S, Garneri P, Trevisan A, Destro M, et al. Bailout Chimney Technique during Endovascular Aneurysm Sealing for Accidental Renal Artery Coverage. J Vasc Interv Radiol. 2016;27(11):1710-2.
34. van Prehn J, Schlosser FJ, Muhs BE, Verhagen HJ, Moll FL, van Herwaarden JA. Oversizing of aortic stent grafts for abdominal aneurysm repair: a systematic review of the benefits and risks. Eur J Vasc Endovasc Surg. 2009;38(1):42-53.
35. Mirza AK, Sandri GA, Tenorio ER, Karkkainen JM, Oderich GS. Severe infolding of fenestrated-branched endovascular stent graft. J Vasc Surg Cases Innov Tech. 2018;4(3):240-3.
36. Oderich GS, Mendes BC, Kanamori KS. Technique of implantation and bail-out maneuvers for endovascular fenestrated repair of juxtarenal aortic aneurysms. Perspect Vasc Surg Endovasc Ther. 2013;25(1-2):28-37.
37. Bertoglio L, Melissano G, Civilini E, Chiesa R. Stent misalignment of the Zenith Dissection Endovascular System. J Vasc Surg. 2013;57(2):515-7.
38. Cochennec F, Becquemin JP, Desgranges P, Allaire E, Kobeiter H, Roudot-Thoraval F. Limb graft occlusion following EVAR: clinical pattern, outcomes and predictive factors of occurrence. Eur J Vasc Endovasc Surg. 2007;34(1):59-65.
39. Patel SR, Roy IN, McWilliams RG, Brennan JA, Vallabhaneni SR, Neequaye SK, et al. Characterising the incidence and mode of visceral stent failure after fenestrated endovascular aneurysm repair (FEVAR). JRSM Cardiovasc Dis. 2021;10:20480040211012503.

40. Ribeiro M, Oderich GS, Macedo T, Vrtiska TJ, Hofer J, Chini J, et al. Assessment of aortic wall thrombus predicts outcomes of endovascular repair of complex aortic aneurysms using fenestrated and branched endografts. J Vasc Surg. 2017;66(5):1321-33.
41. Sandri GA, Oderich GS, Tenorio ER, Ribeiro MS, Reis de Souza L, Cha SS, et al. Impact of aortic wall thrombus on late changes in renal function among patients treated by fenestrated-branched endografts. J Vasc Surg. 2019;69(3):651-60 e4.
42. Chaikof EL, Dalman RL, Eskandari MK, Jackson BM, Lee WA, Mansour MA, et al. The Society for Vascular Surgery practice guidelines on the care of patients with an abdominal aortic aneurysm. J Vasc Surg. 2018;67(1):2-77 e2.
43. Hertault A, Maurel B, Sobocinski J, Martin Gonzalez T, Le Roux M, Azzaoui R, et al. Impact of hybrid rooms with image fusion on radiation exposure during endovascular aortic repair. Eur J Vasc Endovasc Surg. 2014;48(4):382-90.
44. Sailer AM, de Haan MW, Peppelenbosch AG, Jacobs MJ, Wildberger JE, Schurink GW. CTA with fluoroscopy image fusion guidance in endovascular complex aortic aneurysm repair. Eur J Vasc Endovasc Surg. 2014;47(4):349-56.
45. Tenorio ER, Oderich GS, Sandri GA, Ozbek P, Karkkainen JM, Vrtiska T, et al. Prospective nonrandomized study to evaluate cone beam computed tomography for technical assessment of standard and complex endovascular aortic repair. J Vasc Surg. 2020;71(6):1982-93 e5.
46. Resch TA, Tornqvist P, Sonesson B, Dias NV. Techniques to reduce radiation for patients and operators during aortic endografting. J Cardiovasc Surg (Torino). 2016;57(2):178-84.
47. Gennai S, Leone N, Saitta G, Migliari M, Lauricella A, Farchioni L, et al. Intravascular Ultrasound in Branched and Fenestrated Endovascular Aneurysm Repair: Initial Experience in a Single-Center Cohort Study. J Endovasc Ther. 2021;28(6):828-36.
48. Belkin N, Jackson BM, Foley PJ, Damrauer SM, Kalapatapu V, Golden MA, et al. The use of intravascular ultrasound in the treatment of type B aortic dissection with thoracic endovascular aneurysm repair is associated with improved long-term survival. J Vasc Surg. 2020;72(2):490-7.
49. Alberga AJ, von Meijenfeldt GCI, Rastogi V, de Bruin JL, Wever JJ, van Herwaarden JA, et al. Association of Hospital Volume with Perioperative Mortality of Endovascular Repair of Complex Aortic Aneurysms: A Nationwide Cohort Study. Ann Surg. 2021.
50. Mirza AK, Tenorio ER, Karkkainen JM, Hofer J, Macedo T, Cha S, et al. Learning curve of fenestrated and branched endovascular aortic repair for pararenal and thoracoabdominal aneurysms. J Vasc Surg. 2020;72(2):423-34 e1.
51. D'Oria M, Scali S, Mao J, Szeberin Z, Thomson I, Beiles B, et al. Association Between Hospital Volume and Failure to Rescue After Open or Endovascular Repair of Intact Abdominal Aortic Aneurysms in the VASCUNET and International Consortium of Vascular Registries. Ann Surg. 2021;274(5):e452-e9.

Supplemental Material

Supplemental Table 1. Literature covering technical intraoperative adverse events during fenestrated branched endovascular aneurysm repair, including complications related to access, target arteries, and grafts

	Intraoperative adverse events		
Study, first author, year	Access-related	Target arteries-related	Graft-related
Tenorio et al. J Vasc Surg. 2022	✓	✓	✓
Cochennec et al. J Vasc Surg. 2014	✓	✓	✓
Buck et al. J Vasc Surg. 2015	✓		
Malkawi et al. Eur J Vasc Endovasc Surg. 2010	✓		
Teh et al. Eur J Vasc Endovasc Surg. 2001	✓		
De Souza et al. J Vasc Surg. 2015	✓		
Rowse et al. J Vasc Surg. 2019	✓		
Mendes et al. J Vasc Surg. 2016		✓	
Karkkainen et al. Eur J Vasc Endovasc Surg. 2020		✓	
Kapahnke et al. Ann Vasc Surg. 2022		✓	
Fransen et al. J Endovasc Ther. 2003			✓
Coelho et al. Eur J Vasc Endovasc Surg. 2019			✓
Schurink et al. J Vasc Surg. 1999			✓
Gu et al. J Vasc Surg Cases Innov Tech. 2021			✓
Adu et al. Ann Vasc Surg. 2012			✓
Varetto et al. J Vasc Interv Radiol. 2016			✓
Van Prehn et al. Eur J Vasc Endovasc Surg. 2009			✓
Mirza et al. J Vasc Surg Cases Innov Tech. 2018			✓
Oderich et al. Perspect Vasc Surg Endovasc Ther. 2012		✓	✓
Cochennec et al. Eur J Vasc Endovasc Surg. 2007			✓
Patel et al. JRSM Cardiovasc Dis. 2021			✓



Chapter 4

Technical Pitfalls and Proposed Modifications of Instructions for use for Endovascular Aortic Aneurysm Repair Using the Gore Excluder Conformable Device in Angulated and Short Landing Zones

Andrea Vacirca[1,2*], Titia A.L. Sulzer[1,3*], Thomas Mesnard[1], Aidin Baghbani-Oskouei[1], Laura Ocasio[1], Thanila A. Macedo[1], Hence J.M. Verhagen[3], Robert Rhee[4], Gustavo S. Oderich[1]

[1] Department of Cardiothoracic & Vascular Surgery, Advanced Aortic Research Program at the University of Texas Health Science Center at Houston, McGovern Medical School, Houston, TX.
[2] Vascular Surgery, Department of Medical and Surgical Sciences, University of Bologna, Bologna, Italy.
[3] Department of Vascular Surgery, Erasmus Medical Center, Rotterdam, the Netherlands.
[4] Division of Vascular and Endovascular Surgery, Maimonides Medical Center, New York.

* Andrea Vacirca and Titia A.L. Sulzer share the first authorship.

Journal of Vascular Surgery Cases, Innovations, and Techniques. Volume 9, Issue 4, December 2023
DOI: 10.1016/j.jvscit.2023.101339

Abstract

To describe a case of abdominal aortic aneurysm (AAA) and angulated proximal neck treated with Gore Excluder Conformable® and to show relevant technical pitfalls in the deployment of the graft main body. An 82-year-old male presented with a 71 mm asymptomatic AAA with an angulated infrarenal proximal neck (75°) was referred to our unit. The patient was treated with a 26-mm Gore Excluder Conformable® device, which was deployed slightly above the renal arteries after pre-catheterization of the lowest renal artery. The graft was then repositioned with the support of the introducer sheath and a stiff guide wire. The proximal sealing zone was ballooned before the endograft delivery system was retrieved to avoid distal migration. Technical success was achieved. The patient was discharged with no complications. No type 1a Endoleak was present at 6-months CT-Scan. Endovascular treatment of AAA with severe angulated proximal neck can be effective with a conformable stent-graft if technical measures are used during the deployment of the main body to optimize seal.

Introduction

Endovascular aneurysm repair (EVAR) is the treatment of choice for infrarenal abdominal aortic aneurysms (AAA) in patients with suitable anatomy, due to low perioperative morbidity and mortality compared to open surgical repair.[1] Nevertheless, a severely angulated proximal neck (>60°-90°) still represents a serious challenge for stent-graft apposition and deployment increasing the risks of type 1a endoleaks and secondary interventions.[2-6] The Gore Excluder Conformable® stent-graft (WL Gore & Associates) has been designed with proximal active control for optimization of stent-graft apposition and repositioning in tortuous and angulated segments.[7-9] The ability to bend and/or reposition the stent-graft may extend indications to patients with severely angulated proximal necks.[10-13] However, the initial authors experience with the proposed instructions for use (IFU) revealed significant challenges due to risk of malposition and dislodgement of the stent-graft in angulated segments. The aim of this case report was to illustrate a step-by-step modification of the proposed IFU about Gore Excluder Conformable® stent-graft deployment in a patient with a severely angulated proximal neck. The patient of the case presentation agreed to publish his case details and images.

Case Presentation

An 82-year-old male patient presented with enlarging 7.1-cm asymptomatic AAA. His medical history included hypertension, glaucoma and urinary retention due to benign prostatic hypertrophy. Preoperative computed tomography angiography (CTA) confirmed a 7.1-cm infrarenal aortic aneurysm (**Fig 1**) with 20-mm and 15-mm proximal sealing zone diameter and length, 50° suprarenal and 75° infrarenal neck angulation. There was no evidence of thrombus and minimal calcification. Both common iliac arteries were tortuous but had adequate length and diameter sealing zones. Despite the infrarenal neck angulation exceeding 60° in the approved IFU, we recommended EVAR using Gore Excluder Conformable® device with off-label indication.

Surgical technique

The procedure was performed in a hybrid room using GE Allia system and the patient underwent general endotracheal anesthesia. Bilateral percutaneous trans-femoral access with pre-closure technique was established. Cook Lunderquist® extra stiff 0.035 guide wires (Cook Medical, Bloomington, IN) were positioned in the thoracic aorta, in modification of the original Terumo Advantage® wires used in the initial experience. Bilateral 16 French Gore DrySeal® sheaths were advanced to the infrarenal aorta. To

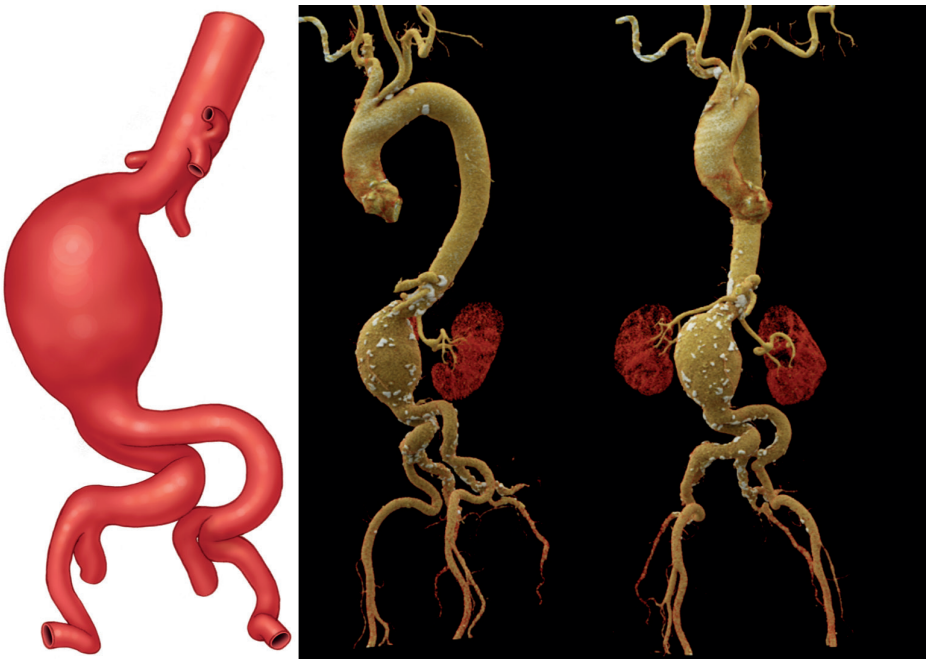

Fig 1. Illustration and three-dimensional model based on preoperative computed tomography angiography.

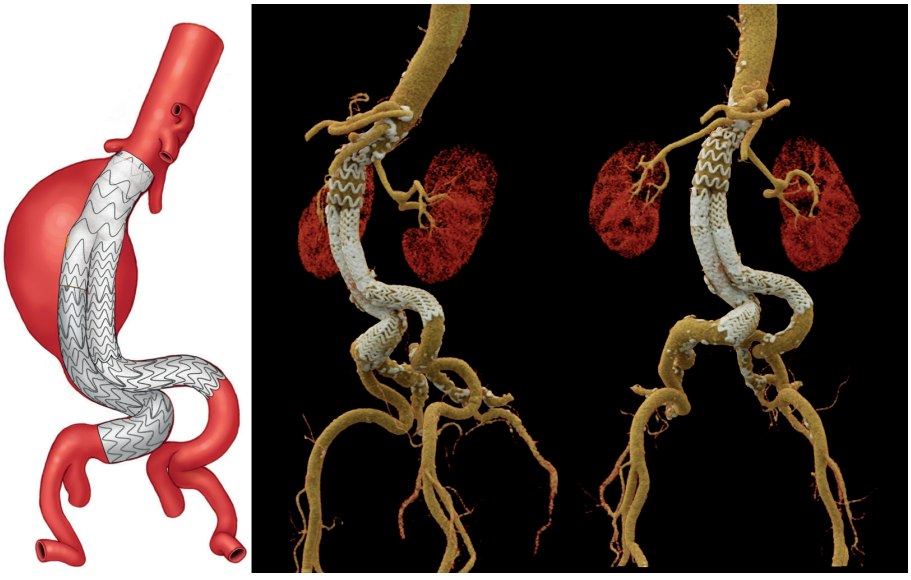

Fig 2. Illustration and three-dimensional model based on postoperative computed tomography angiography after endovascular aortic repair (EVAR) using Gore Excluder conformable endograft.

enhance precision during deployment of the stent-graft, the lowest renal artery was selectively catheterized via the right femoral access using a LIMA guide catheter. The proximal neck anatomy and the origin of the renal arteries were referenced using on-lay fusion. A 26-mm Gore Excluder Conformable® bifurcated aortic stent-graft was oriented extracorporeally, introduced via the left transfemoral approach and advanced to position slightly above the renal arteries. The ipsilateral sheath was retracted just distal to the contralateral gate in modification of the original IFU. The first deployment of the proximal main body was performed slightly above the lowest renal artery. The device was therefore constrained using the repositioning system, the Lunderquist guidewire was partially retrieved and the endograft was bended to adapt to the angulated anatomy. Subsequently, the graft was cautiously pulled downwards a few mm and re-expanded once the level of the lowest renal artery was confirmed by puff angiography. The proximal device mechanism was fully deployed. The contralateral gate was successfully catheterized via the right transfemoral approach. The main body was completely deployed after further withdrawal of the ipsilateral sheath. However, the endograft delivery system was retrieved in modification to the proposed IFU, after inflation of a molding balloon over the Lunderquist wire, to dilate the proximal sealing zone. The repair was extended to both common iliac arteries using iliac extension limbs. A molding balloon was used to dilate again the proximal, distal landing zones and attachment sites. Completion cone beam computed tomography angiography (CBCT) of the aorta and iliac arteries revealed widely patent bilateral renal arteries, main body, iliac limbs, and iliac arteries without evidence of endoleaks. Both femoral artery punctures were closed using the pre-closure technique.

The patient was discharged home on postoperative day 2 with no complications. Follow-up CTA (**Fig 2**) at 6-months showed a patent stent-graft with a stable sac diameter, a type 1b endoleak from inadequate apposition of the right iliac stent-graft limb as well as a type 2 endoleak. The patient underwent successful revision with extension of the right iliac limb and peri-graft embolization of the lumbosacral arteries. There was no residual endoleak on the intraoperative duplex and contrast-enhanced ultrasound.

Discussion

This case shows several modifications of the proposed IFU for accurate deployment of the Gore Excluder Conformable® stent-graft in patients with severely angulated proximal neck. The approved IFU of Gore Excluder Conformable® recommends using the graft in patients with proximal infrarenal neck ≤60° and at least 15 mm in length

and therefore this case represents an off-label indication. Although several series have shown favorable short-term outcomes using the device in angulated proximal necks (>60°), the authors have experienced challenges in their initial experience due to lack of support system using the proposed IFU technique, which may lead to inaccurate deployment.[10-13] Based on the proposed IFU and initial experience, it is recommended to use the Terumo Advantage wire due to more flexible tip and to retract the ipsilateral sheath distal to the edge of the stent-graft limb. However, the lack of stent-graft support with excessive tortuosity and angulation may predispose to distal dislodgement and suboptimal deployment.

Bonvini and associates reported on five patients with severe proximal neck angulation and recommended starting the deployment of the graft above the level of renal arteries. Other authors have also used pre-catheterization of the lowest renal artery, akin to advanced fenestrated stent-graft techniques, for precise deployment in patients with short landing zones.[12] These maneuvers were also applied in our case to improve the accuracy of the deployment. In addition, the approved device IFU recommends that the main body and its integrated ipsilateral leg should be fully unsheathed before starting the deployment. We have modified the technique to keep the sheath at a higher level just distal to the contralateral gate in order to provide support. In addition, our preference for the Lunderquist guidewire over the floppier Terumo Advantage® 0.035 guidewire (Terumo Corp, Somerset, NJ) is also to overcome support and the tendency of the device to migrate distally during deployment in presence of tortuosity and angulation. We recommend the sequence of first deployment, adjustment of parallax, bending the graft and finally moving the constrained graft downwards if needed. Finally, ballooning of the proximal neck prior to removal of the delivery system is also recommended to engage the active fixation and prevent distal movement.

The technique described in this manuscript reflects adjustments to the proposed IFU of Gore Excluder Conformable® deployment steps based on increasing experience with tortuous and angulated anatomy, but caution in patient selection is critical to balance the indication against alternative options such as open repair, fenestrated grafts, and EndoSuture aneurysm repair (Medtronic). Finally, longer follow-up is needed to assess durability of infrarenal repair in patients with excessive angulation.

Conclusion

Use of a Conformable infrarenal stent-graft is feasible in selected patients with angulated infrarenal sealing zones. Modification of the proposed IFU is needed to optimize deploy-

ment and seal due to risk of distal movement. These useful pitfalls are not recommended on routine cases but offer potential advantage in patients with short and angulated necks: pre-catheterization of the lowest renal artery, deployment above intended target, repositioning and bending over support of the introducer sheath and a stiff guide wire, and ballooning prior to retrieval of the delivery system.

All illustrations in this chapter were drawn by Mr. David Factor. Used with permission.

References

1. Lederle FA, Kyriakides TC, Stroupe KT, Freischlag JA, Padberg FT, Jr., Matsumura JS, et al. Open versus Endovascular Repair of Abdominal Aortic Aneurysm. N Engl J Med. 2019;380(22):2126-35.
2. Chaikof EL, Fillinger MF, Matsumura JS, Rutherford RB, White GH, Blankensteijn JD, et al. Identifying and grading factors that modify the outcome of endovascular aortic aneurysm repair. J Vasc Surg. 2002;35(5):1061-6.
3. Hobo R, Kievit J, Leurs LJ, Buth J, Collaborators E. Influence of severe infrarenal aortic neck angulation on complications at the proximal neck following endovascular AAA repair: a EUROSTAR study. J Endovasc Ther. 2007;14(1):1-11.
4. Hoshina K, Akai T, Takayama T, Kato M, Nakazawa T, Okamoto H, et al. Outcomes and morphologic changes after endovascular repair for abdominal aortic aneurysms with a severely angulated neck- a device-specific analysis. Circ J. 2013;77(8):1996-2002.
5. Oliveira NFG, Goncalves FB, Hoeks SE, Josee van Rijn M, Ultee K, Pinto JP, et al. Long-term outcomes of standard endovascular aneurysm repair in patients with severe neck angulation. J Vasc Surg. 2018;68(6):1725-35.
6. Mathlouthi A, Locham S, Dakour-Aridi H, Black JH, Malas MB. Impact of suprarenal neck angulation on endovascular aneurysm repair outcomes. J Vasc Surg. 2020;71(6):1900-6.
7. Rhee R, Peterson B, Moore E, Lepore M, Oderich G. Initial human experience with the GORE EXCLUDER Conformable AAA Endoprosthesis. J Vasc Surg Cases Innov Tech. 2019;5(3):319-22.
8. Rhee R, Oderich G, Han S, Long C, Muck P, Moore E, et al. One-year results of the GORE EXCLUDER Conformable AAA Endoprosthesis system in the United States regulatory trial. J Vasc Surg. 2022;76(4): 951-9 e2.
9. Finotello A, Schuurmann R, Di Gregorio S, Boschetti GA, Chakfe N, Pane B, et al. Initial Clinical Experience With a New Conformable Abdominal Aortic Endograft: Aortic Neck Coverage and Curvature Analysis in Challenging Aortic Necks. J Endovasc Ther. 2021;28(3):407-14.
10. Zuidema R, Bastianon M, Mena Vera JM, S DIG, Mozzetta G, de Vries JP, et al. Single-center results of the Gore Excluder Conformable Endoprosthesis with active control system in endovascular aneurysm repair. J Cardiovasc Surg (Torino). 2023;64(2):150-8.
11. Lee SH, Melvin R, Kerr S, Barakova L, Wilson A, Renwick B. Novel conformable stent-graft repair of abdominal aortic aneurysms with hostile neck anatomy: A single-centre experience. Vascular. 2022:17085381221124990.
12. Bonvini S, Tasselli S, Raunig I, Wassermann V, Piazza M, Antonello M. Endovascular aortic repair with the Gore Excluder Conformable endograft in severe neck angulation: Preliminary experience and technical aspects. Vascular. 2021;29(2):183-9.
13. Mascoli C, Faggioli G, Goretti M, Gallitto E, Pini R, Logiacco AM, et al. Endovascular Treatment of Abdominal Aortic Aneurysm With Severe Angulation of Infrarenal Aortic Neck by Gore Conformable Endograft. J Endovasc Ther. 2022:15266028221083461.

Part II

Sac Dynamics as a Prognostic Marker for Clinical Success



Chapter 5

Aneurysm Sac Shrinkage at 1 Year After Fenestrated-Branched Endovascular Aortic Repair of Complex Aortic Aneurysms Offers Mid-Term Survival Advantage

Thomas Mesnard*[1], Titia A.L. Sulzer*[1,4], Lucas R. Kanamori[1], Dora Babocs[1], Andrea Vacirca[1], Aidin Baghbani-Oskouei[1], Safa Savadi[1], Emanuel R. Tenorio[1], Aleem Mirza[1], Naveed Saqib[1], Bernardo C. Mendes[2], Thanila A. Macedo[3], Hence J.M. Verhagen[4], Ying Huang[1], Gustavo S. Oderich[1]

[1] Department of Cardiothoracic & Vascular Surgery, Advanced Aortic Research Program at the University of Texas Health Science Center at Houston, McGovern Medical School, Houston, TX.
[2] Division of Vascular and Endovascular Surgery, Mayo Clinic, Rochester, MN.
[3] Department of Diagnostic and Interventional Radiology at the University of Texas Health Science Center at Houston, McGovern Medical School, Houston, TX.
[4] Department of Vascular Surgery, Erasmus University Medical Center, Rotterdam, the Netherlands.

* Thomas Mesnard and Titia A.L. Sulzer share the first authorship.

This study was presented at the Society for Clinical Vascular Surgery Annual Symposium, Scottsdale, Arizona, March 2024.

Journal of Vascular Surgery, Volume 80, Issue 4,
October 2024, pages 958-967
DOI: 10.1016/j.jvs.2024.05.054

Abstract

Objective: To investigate the impact of 1-year changes in aneurysm sac diameter on patient survival after fenestrated branched endovascular aortic repair (FB-EVAR) of complex abdominal aortic aneurysms or thoracoabdominal aortic aneurysms.

Methods: We reviewed the clinical data of patients enrolled in a prospective nonrandomized study investigating FB-EVAR (2013-2022). Patients with sequential follow-up computed tomography scans at baseline and 6 to 18 months after FB-EVAR were included in the analysis. Aneurysm sac diameter change was defined as the difference in maximum aortic diameter from baseline measurements obtained in centerline of flow. Patients were classified as those with sac shrinkage (≥5 mm) or failure to regress (<5 mm or expansion) according to sac diameter change. The primary end point was all-cause mortality. Secondary end points were aortic-related mortality (ARM), aortic aneurysm rupture (AAR), and aorta-related secondary intervention.

Results: There were 549 patients treated by FB-EVAR. Of these, 463 patients (71% male, mean age, 74±8 years) with sequential computed tomography imaging were investigated. Aneurysm extent was thoracoabdominal aortic aneurysms in 328 patients (71%) and abdominal aortic aneurysms in 135 (29%). Sac shrinkage occurred in 270 patients (58%) and failure to regress in 193 patients (42%), including 19 patients (4%) with sac expansion at 1 year. Patients from both groups had similar cardiovascular risk factors, except for younger age among patients with sac shrinkage (73±8 years vs.75±8 years; $p<.001$). The median follow-up was 38 months (interquartile range, 18-51 months). The 5-year survival estimate was 69±4.1% for the sac shrinkage group and 46±6.2% for the failure to regress group. Survival estimates adjusted for confounders (age, chronic pulmonary obstructive disease, chronic kidney disease, congestive heart failure, and aneurysm extent) revealed a higher hazard of late mortality in patients with failure to regress (adjusted hazard ratio, 1.72; 95% confidence interval, 1.18-2.52; $p=.005$). The 5-year cumulative incidences of ARM (1.1% vs. 3.1%; $p=.30$), AAR (0.6% vs. 2.6%; $p=.20$), and aorta-related secondary intervention (17.0 ±2.8% vs. 19.0±3.8%) were both comparable between the groups.

Conclusion: Aneurysm sac shrinkage at 1 year is common after FB-EVAR and is associated with improved patient survival, whereas sac enlargement affects only a minority of patients. The low incidences of ARM and AAR indicate that failure to regress may serve as a surrogate marker for nonaortic-related death.

Introduction

Fenestrated-branched endovascular aortic repair (FB- EVAR) has been increasingly used to treat complex abdominal aortic aneurysms (CAAAs) and thoracoabdominal aortic aneurysms (TAAAs), particularly in high-risk patients with suitable anatomy.[1,2] The endovascular treatment aims to exclude the aneurysm and prevent continued aneurysm sac pressurization and enlargement, thus mitigating the risk of aortic aneurysm rupture (AAR). Because these patients require a high rate of secondary interventions, and more than one-half of these are indicated for endoleaks, lifelong imaging surveillance with computed tomography (CT) scans is necessary and recommended.[3,4]

In addition to the assessment of FB-EVAR complications and device integrity issues, follow-up imaging evaluation commonly involves measurements of the maximum aneurysm diameter (MAD). The absence of ongoing aneurysm sac expansion has been regarded as an indicator of sustained clinical success.[5] Persistent and continued aneurysm sac expansion after endovascular repair is related primarily to endoleaks, although alternative mechanisms such as aortic stent graft endotension and infection may also be implicated.[6,7] These situations mandate a comprehensive imaging assessment and the implementation of corrective measures.

Sac remodeling after standard EVAR has been investigated extensively and is regarded as a favorable outcome. Multiple studies have demonstrated positive correlations between sac remodeling after EVAR and patient survival, secondary interventions and complications.[8-10] Additionally, a Vascular Quality Initiative (VQI) analysis of EVAR patients also reported a long-term survival advantage with aneurysm sac regression over sac unchanged or growth, which were referred to as failure to regress.[11] Although the Stanford group has reported similar findings for juxtarenal abdominal aortic aneurysms treated by fenestrated endovascular aneurysm repair, there is paucity of data on more extensive CAAAs and TAAAs.[12] The aim of this study was to investigate the impact of aneurysm sac diameter changes at 1 year on outcomes after FB-EVAR for the treatment of CAAAs and TAAAs.

Methods

Study population and groups

This retrospective review included all consecutive patients enrolled in a prospective nonrandomized physician-sponsored investigational device exemption study (NCT01937949 and NCT02089607) between November 1, 2013, and February 28,

2023, to assess outcomes of FB-EVAR in patients with CAAAs and TAAAs. All FB-EVAR were performed by the same operator (senior author). The study was approved by the Institutional Review Board of the University of Texas Health Science Center at Houston and the Institutional Review Board of Mayo Clinic with a data sharing agreement. All patients provided written informed consent for enrollment in the research study.

Patients were included if they had CT scans of complex aortic aneurysm at 6 to 18 months after FB-EVAR and had been treated >1 year before the end of the inclusion period; otherwise, they were excluded. Aneurysm sac behavior was defined as the difference in MAD measured from CT scans at hospital dismissal and at postprocedural 6 to 18 months. For patients who underwent multiple CT scans within the 6- to 18-month postoperative period, we selected the scan performed closest to the 12-month for defining the study groups. The distribution of the time interval between the operation and the CTA used for group definition is presented in **Supplemental Table 1**. In patients not having predischarge CT angiography (CTA; N=34 [7%]), the MAD measured from preprocedural CTA was used for baseline. Patients were classified as the sac shrinkage group if the aneurysm sac diameter regressed >5 mm; otherwise, they were in the failure to regress group, according to the Society for Vascular Surgery reporting standards for endovascular aortic repair of aneurysms involving the renal-mesenteric arteries.[12] The failure to regress group included patients with sac diameter change of <5 mm, as well as those with significant expansion (>5 mm).

Data collection

Demographics, clinical characteristics, anatomical features, procedural and post-procedural data, and follow-up information were collected prospectively using case report forms and entered into an electronic database (Medidata Rave, New York, NY). Aneurysm extent and MAD were determined according to preprocedural CTA. MADs were assessed using outer- to-outer wall measurements from CT scans at comparable level on a dedicated 3D-workstation (iNuition Aquarius 3D Workstation TeraRecon Inc, San Mateo, CA) using centerline of flow reconstruction. The senior author performed all the CT/CTA measurements. Adverse events were reviewed and adjudicated by an independent clinical event committee and Data Safety Monitoring Board and reported annually to the US Food and Drug Administration.

Device design and procedure

Patient anatomy was evaluated using preprocedural CTA with centerline of flow in the Aquarius iNtuition software (TeraRecon, Foster City, CA). Device options included either

an off-the-shelf multibranch or patient-specific fenestrated-branch stent graft with any combination of reinforced fenestrations or directional branches (Cook Medical Inc., Brisbane, Australia, and Søborg, Denmark). Design selection, sizing, and planning were left to the discretion of the principal investigator.[13] The most common designs for CAAAs were three fenestrations and doublewide celiac scallop or four fenestrations. For TAAAs, the most common designs were four fenestrations for extent IV and combination of directional branches (preferentially for mesenteric arteries) and fenestrations for extent I, II, and III TAAAs. All procedures were performed using general anesthesia in a hybrid operating room, and the implantation technique has been described previously.[13, 14]

Imaging follow-up protocol

Clinical follow-up consisted of physical examination, laboratory studies, duplex ultrasound examination of target arteries, and CTA before discharge and at 3, 6, and 12 months postoperatively with annual surveillance thereafter. In patients with non-dialysis-dependent kidney disease, noncontrast imaging and duplex ultrasound examination were used.

Study end points and definitions

The Society for Vascular Surgery reporting standards for endovascular repair of aortic aneurysms involving the renal- mesenteric arteries were used to define variables and outcomes of interest including postoperative major adverse events (MAEs), including all-cause mortality, myocardial infarction, respiratory failure requiring prolonged mechanical ventilation (>24 hours from anticipated) or reintubation, renal function decline resulting in >50% decrease in baseline the estimated glomerular filtration rate or new-onset dialysis, bowel ischemia requiring surgical resection or not resolving with medical therapy, major stroke, and/or paraplegia.[15] The primary end point was all-cause mortality. Secondary end points were aortic-related mortality (ARM), AAR, and aortic-related secondary interventions. Cause of death was based on clinical diagnosis, death certificate, or, if available, autopsy report. ARM included any 30-day or in- hospital mortality, and late deaths related to AAR, aortic stent graft infection, or within the first 30 days after an aortic-related secondary intervention. Aortic-related secondary interventions included any open or endovascular procedures intending to treat any endoleak, target artery instability (significant stenosis, kink, stent fracture, or endoleak), or proximal or distal aneurysmal degeneration by stent graft extensions.

Statistical analysis

Categorical variables were expressed with number (percent) and continuous variables with mean ± standard deviation. Demographics and early outcomes were compared using Pearson χ^2 test, Student *t* test, or analysis of variance as appropriate. Follow-up durations were calculated using the inverse Kaplan-Meier method and were expressed as median with 25th through 75th interquartile range. Survival rates were estimated by the Kaplan-Meier method, and groups were compared with the log-rank test. A Cox proportional hazard model (entry model at a univariate *p*-value of <.05) were used to derive adjusted hazard ratios (aHRs) for all-cause mortality during mid-term follow-up. The adjusted survival curves presented in the figures were estimated based on the Cox model adjusted for confounders including age, chronic pulmonary obstructive disease, stage III or IV chronic kidney disease, congestive heart failure, and aneurysm extent. The cumulative incidence function was computed for ARM with death from other causes as a competing risk, and AAR and aorta-related secondary interventions with all-cause mortality as a competing risk. Univariable Cox proportional cause-specific hazards regression models were used to evaluate the effect of sac dynamic on secondary end points. To illustrate the changes in MADs at different time points, spaghetti plots were used, overlaid with locally weighted scatter plot smoothing regression lines along with 95% confidence intervals (CI). The locally weighted scatter plot smoothing regression line is a nonparametric regression method that uses local weighted regression to fit a smooth curve through points in a scatterplot.[16] This approach depicted the estimated overall variability of the MAD over time. A subgroup analysis was performed among patients treated for CAAAs, Extent IV TAAAs and extent I, II, and III TAAAs. A *p*-value of <.05 was considered statistically significant. All analyses were performed using the R programming language (version 4.1.2; The R Foundation for Statistical Computing, Vienna, Austria).

Results

Study population

There were 549 patients treated by FB-EVAR during the study period. Of these, 463 patients (84%) with sequential CT imaging were included in this analysis (**Supplemental Fig 1**). There were 327 male (71%) and 136 female (29%) patients with mean age of 74±8 years. A total of 270 patients (58%) had aneurysm sac shrinkage and 193 (42%) had failure to regress. Compared with patients in the failure to regress group, sac shrinkage patients were younger (73.0±7.8 years vs. 75.0±8.1 years; *p*<.001), were less likely to be males (67% [N=181] vs. 76% [N=146]; *p*=.045), but more frequently had

Table 1. Demographics and clinical characteristics of 463 patients undergoing fenestrated-branched endovascular aortic repair (FB-EVAR) stratified by aneurysm sac diameter change

	Overall N=463	Sac shrinkage N=270	Failure to regress N=193	*p*-value
Demographics				
Age, years	74±8.0	73±7.8	75±8.1	**<.001**
Male sex	327 (71)	181 (67)	146 (76)	**.045**
BMI, kg/m^2	27.7 (24.3, 31.3)	27.5 (24.3, 31.3)	28.0 (24.4, 31.3)	.619
Cardiovascular risk factor				
Coronary artery disease	222 (48)	133 (49)	89 (46)	.504
Congestive heart failure	41 (8.9)	20 (7.4)	21 (11)	.195
Hypertension	414 (89)	238 (88)	176 (91)	.294
Hypercholesterolemia	365 (79)	211 (78)	154 (80)	.669
Chronic obstructive pulmonary disease	138 (30)	88 (33)	50 (26)	.129
Chronic kidney disease, stage III-IV	202 (44)	113 (42)	89 (46)	.362
Dialysis	2 (0.4)	1 (0.4)	1 (0.5)	1
Stroke or Transient ischemic attack	46 (10.0)	29 (11)	17 (8.9)	.505
Diabetes mellitus	65 (14)	38 (14)	27 (14)	.979
Peripheral artery disease	72 (16)	42 (16)	30 (16)	.984
Cigarette smoking	360 (78)	215 (80)	145 (75)	.251
Genetically triggered aortic disease	7 (1.5)	5 (1.9)	2 (1.0)	.705
Preoperative risk assessment				
ASA class ≥3	258 (56)	151 (56)	107 (55)	.917
Prior open aortic repair	113 (24)	67 (25)	46 (24)	.809
Prior endovascular aortic repair	166 (36)	104 (39)	62 (32)	.157
Prior EVAR	52 (11)	24 (8.9)	28 (15)	.059
Anatomical characteristic				
Maximum aortic diameter, mm	64.5±10.5	64.7±10.3	64.1±10.7	.370
Chronic aortic dissection	48 (10)	32 (12)	16 (8.3)	.210
Status of the Aneurysm				.811
Asymptomatic	451 (97)	264 (98)	187 (97)	
Symptomatic non ruptured	8 (1.7)	4 (1.5)	4 (2.1)	
Contained rupture	4 (0.9)	2 (0.7)	2 (1.0)	
CAAA (Pararenal)	135 (29)	71 (26)	64 (33)	.109
Extent IV TAAA	144 (31)	76 (28)	68 (35)	.104
Extent I, II, III TAAA	184 (40)	123 (46)	61 (32)	**.002**
Extent I TAAA	24 (5.2)	15 (5.6)	9 (4.7)	
Extent II TAAA	112 (24)	76 (28)	36 (19)	
Extent III TAAA	48 (10)	32 (12)	16 (8.3)	

ASA, American Society of Anesthesiology; *CAAA*, complex abdominal aortic aneurysm; *EVAR*, endovascular aortic repair; *FB-EVAR*, fenestrated-branched endovascular aortic repair; *TAAA*, thoracoabdominal-aortic aneurysm. Categorical variables are presented as count (percentage) and continuous variables as mean ± standard deviation or median (Interquartile range).

extent I, II, or III TAAAs (46% [N=123] vs. 32% [N=61]; *p*=.002). The baseline mean MAD was not significantly different between the two groups (**Table 1**).

A total of 1806 renal-mesenteric arteries were incorporated. Compared with the sac shrinkage group, patients with failure to regress were more likely to have four or more target arteries incorporated (92% [N=177] vs. 81% [N=220]; *p*=.002) and were more often treated with patient-specific or fenestrated devices (each *p*<.05) (**Table 2**). The proportion of patient treated with an iliac branch device was not significantly different between the two groups.

Table 2. Procedure detail and device design for 463 patients undergoing fenestrated-branched endovascular aortic repair (FB-EVAR) stratified by aneurysm sac diameter change

	Overall N=463	Sac shrinkage N=270	Failure to regress N=193	*p*-value
Device design				**.046**
Patient specific device	411 (89)	233 (86)	178 (92)	
Off-the-shelf T-Branch	52 (11)	37 (14)	15 (7.8)	
FB-EVAR configuration				**.043**
Fenestrated repair	271 (59)	145 (54)	126 (65)	
Branched repair	83 (18)	55 (20)	28 (15)	
Fenestrated and branched repair	109 (24)	70 (26)	39 (20)	
Target arteries per patient	3.9±0.5	3.8±0.6	4.0±0.5	**.002**
Target arteries ≥4	397 (86)	220 (81)	177 (92)	**.002**
IBD				.271
Unilateral	29 (6.4)	16 (6.0)	13 (7.0)	
Bilateral	13 (2.9)	5 (1.9)	8 (4.3)	
Bilateral percutaneous femoral approach for main device delivery	364 (79)	205 (76)	159 (82)	.095
Upper extremity access for target artery incorporation	336 (73)	210 (78)	126 (65)	**.003**
Technical success	447 (97)	261 (97)	186 (96)	.865
CBCT	420 (91)	241 (89)	179 (93)	.095
Procedural metrics				
Contrast volume, mL	152±61.5	154±62.7	149±59.7	.517
Procedural time, min	230±81	238±86	219±73	**.007**
Fluoroscopy time, min	79.2±34.9	81.1±38.8	76.5±28.3	.240
Cumulative Air Kerma, Gy	2.0±1.7	2.0±1.7	1.9±1.7	.236

CBCT, come beam computed tomography; *IBD*, iliac branch device; *FB-EVAR*, fenestrated-branched endovascular aortic repair. Categorical variables are presented as count (percentage) and continuous variables as mean ± standard deviation.

Early outcomes

The incidences of MAEs were comparable for sac shrinkage and failure to regress patients (13% vs. 14%, *p*=.943), and there was no significant difference in each of the MAE between two groups (**Supplemental Table 2**).

Survival and ARM

The median follow-up was 38 months (interquartile range, 18-51 months). There were 119 late deaths attributed to malignancy (N=24 [20%]), pulmonary complications (N=19 [16%]), cerebrovascular events (N=14 [12%]), cardiovascular events (N=11 [9%]), aortic-related deaths (N=5 [4.2%]), and other unknown nonaortic-related causes (N=34 [29%]). Cardiovascular mortality accounted for 5% of nonaortic- related late deaths (N=3) in the sac shrinkage group and 14% (N=8) in the failure to regress group (*p*<.05). Of the five late ARMs, three died from AARs, one from aortic stent graft infection, and one from postoperative complications of open surgical aortic arch replacement.

Sac shrinkage patients demonstrated 5-year survival of 69.0±4.1% compared with 46.0±6.2% for patients with failure to regress (**Fig 1**). The multivariable Cox regression model revealed that failure to regress at 1-year negatively affected all-cause mortality adjusted on confounders (aHR, 1.72; 95% CI, 1.18-2.52; *p*=.005) (**Supplemental Table 3**).

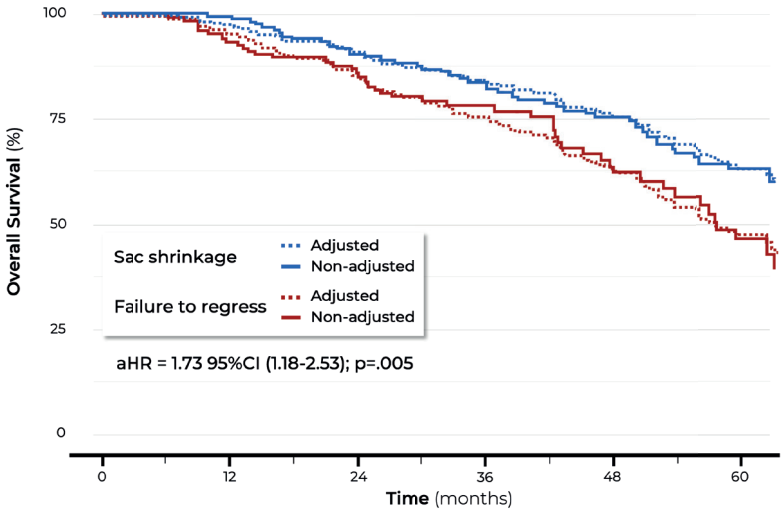

Number at risk	270	255	197	146	100	44
Survival (%) ±SE (%)	100 ± 0.0	99 ± 0.5	91 ± 1.9	83 ± 2.5	75 ± 3.2	69 ± 4.1
Number at risk	193	157	116	65	41	22
Survival (%) ±SE (%)	100 ± 0.0	94 ± 1.9	85 ± 2.9	78 ± 3.6	62 ± 5.2	46 ± 6.2

Fig 1. Nonadjusted and adjusted Kaplan-Meier survival estimates for sac shrinkage and failure to regress groups. Patients in the sac shrinkage had improved survival than those in the failure to regress group. *aHR*, adjusted hazard ratio; *CI*, confidence interval; *SE*, standard error.

The 5-year cumulative incidence of ARM were 1.1±0.8% among patients with 1-year sac shrinkage and 3.1±2.0% among those with failure to regress (**Fig 2**). There was no significant difference in ARM between the two groups (HR, 2.62; 95% CI, 0.44-15.76; *p*=.286).

AAR

Three patients developed aortic rupture during follow-up, and all of them died. The 5-year cumulative incidences of AAR were 0.6±0.6% for patients with sac shrinkage, and 2.6±2.0% for patients who failed to regress, respectively (**Fig 3**). There was no significant difference in AAR between the two groups (HR, 3.84; 95% CI, 0.35-42.46; *p*=.259).

Secondary interventions

A total of 63 patients (14%) required secondary interventions, including 63 aortic-related secondary interventions and 36 (57%) for the treatment of endoleaks.

The 5-year cumulative incidences of aortic-related secondary intervention were 17.0±2.8% among patients with sac shrinkage and 19.0±3.8% among patients with failure to regress, respectively (**Supplemental Fig 2A**). The sac behavior at 1 year had no effect on aorta-related secondary interventions (HR, 3.84; 95% CI, 0.35-42.46; *p*=.259).

The 5-year cumulative incidence of endoleak-related secondary intervention with death from other causes as a competing event were 10.0±2.4% among sac shrinkage patients, and 15.0±3.7% among failure to regress patients, respectively (**Supplemental Fig 2B**). There was no significant difference in endoleak-related secondary interventions between the two groups (HR, 1.56; 95% CI, 0.81-3.00; *p*=.176).

Temporal trend of MAD

Among patients with sac shrinkage, the most substantial aneurysm sac regression occurred within the first year after FB-EVAR, with an estimated reduction of approximately 15 mm, followed by a trend toward stable MADs (**Fig 4A**). Conversely, among patients with sac failure to regress, a delayed sac shrinkage with an approximate reduction of 7 mm was observed between 1 and 3 years after the procedure (**Fig 4B**).

Subgroup analysis

Survival estimates were comparable between the sac shrinkage and failure to regress sub-groups among patients undergoing FB-EVAR for CAAAs (aHR, 1.17; 95% CI, 0.53-2.62; *p*=.698) (**Supplemental Fig 3A**) or extent IV TAAAs (aHR, 1.84; 95% CI, 0.88-3.83;

p=.103) (**Supplemental Fig 3B**). However, among patients with extent I, II, and III TAAAs, those in the failure to regress subgroup had 2.5-fold increased risk of having late mortality (aHR, 2.49; 95% CI, 1.36-4.53; *p*=.003) (**Supplemental Fig 3C**).

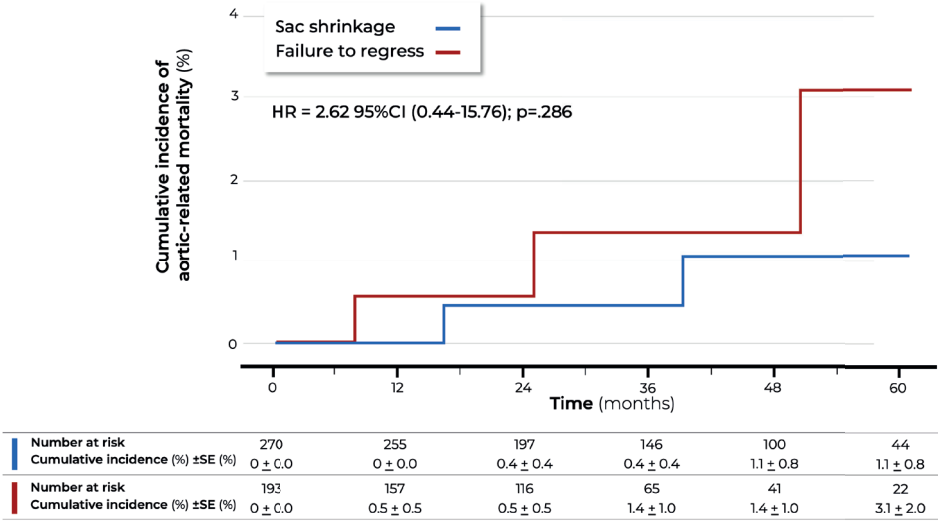

Fig 2. Cumulative incidence of aortic-related mortality (ARM) with death of other causes as the competing risk event for sac shrinkage and failure to regress groups. There was no significant difference between the two groups. *CI*, confidence interval; *HR*, hazard ratio; *SE*, standard error.

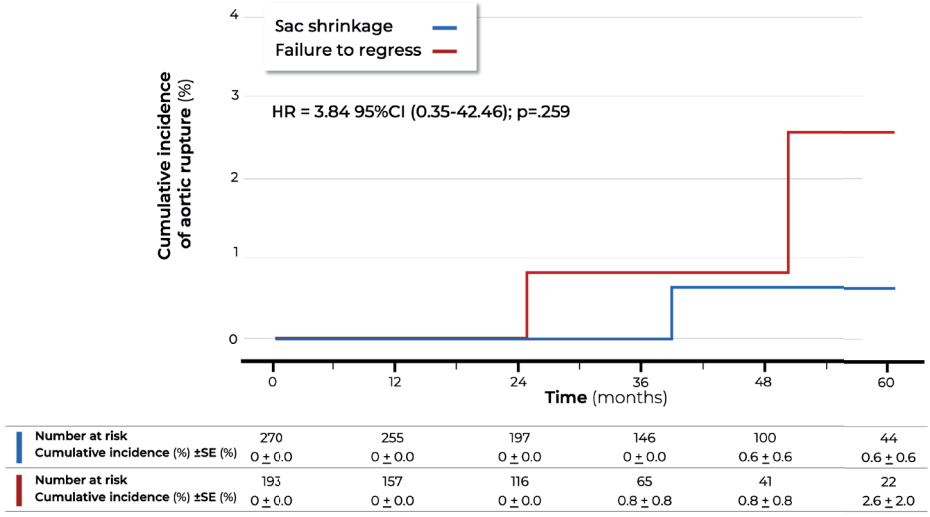

Fig 3. Cumulative incidence function of any aortic rupture with all-cause death as competing risk event for sac shrinkage and failure to regress groups. There was no significant difference between the two groups. *CI*, confidence interval; *HR*, hazard ratio; *SE*, standard error.

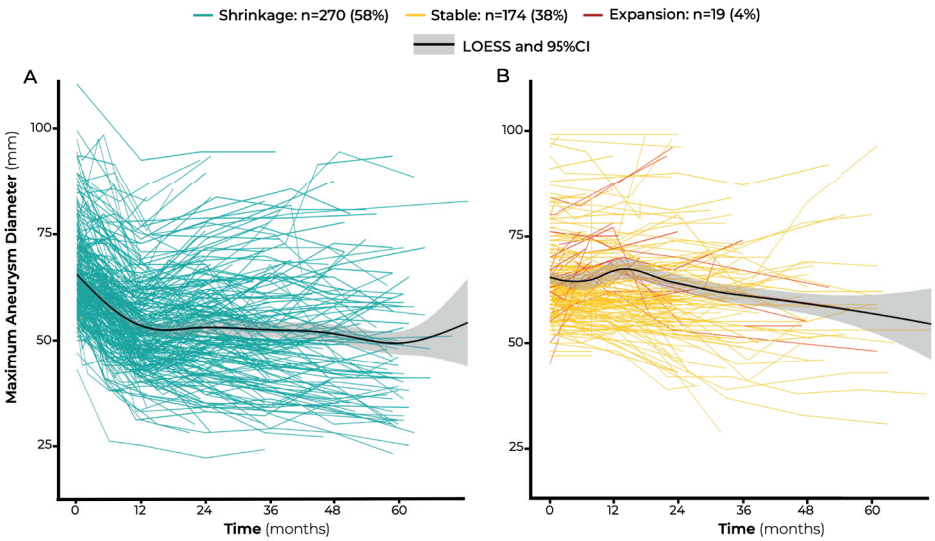

Fig 4. Temporal trends of maximum aneurysm diameter among 463 patients treated by fenestrated-branched endovascular aortic repair (FB-EVAR) in patients with 1-year sac shrinkage **(A)** or with 1-year failure to regress **(B)**. *CI*, confidence interval; *LOESS*, locally weighted scatter plot smoothing regression lines.

Discussion

Aneurysm sac dynamics after standard EVAR have been studied widely, and aneurysm sac shrinkage has been confirmed to be associated with long-term survival benefit.[9-11] However, there are few data on aneurysm sac behavior after FB-EVAR for complex aortic aneurysms or data on differences between patients with CAAAs and TAAAs. This study focused on patients who had CT imaging obtained at baseline and at 6 to 18 months. Our data demonstrated that sac shrinkage at 1 year was common (58%) after FB-EVAR, and it was an important prognostic factor for improved survival at 5 years (69% for the sac shrinkage and 46% for the failure to regress group). This difference was observed among patients with extent I, II, and III TAAAs, but not for CAAAs and extent IV TAAAs. Our results also revealed that the cumulative incidences of ARM and AAR were both low (each <3.2%), irrespective of aneurysm sac dynamics, indicating that late mortality is associated with other nonaortic-related causes. These findings support that 1-year failure to regress may serve as a surrogate marker for nonaortic-related death after FB-EVAR.

Imaging studies, particularly CTA, are important for patients with CAA who undergo FB-EVAR, not only at the planning stage, but also throughout the follow-up to identify device or procedure-related complications. Because the present study investigated the

impact of 1-year aneurysm sac dynamics, which was defined according to the changes in MADs, we also accepted measurements from CT scans during follow-up. We selected MAD measurements from discharge CT scans as the baseline values rather than those from the preprocedural assessments. This strategy was primarily motivated by the standardized CT or CTA protocols performed at our institution, the potential reshaping of the aorta after stent graft implantation, and the availability of the imaging studies in 94% of patients. In addition, we noticed that there was a significant difference in MADs measured from postprocedural CTAs and preprocedural CTAs (>5 mm) in 29% of the patients. Indeed, patients may develop aneurysm growth during a waiting period for a manufactured aortic device, which is not a consideration in standard EVAR, where a commercially available stent graft is ready to use.

Concerning the time frame for defining aneurysm sac dynamic after FB-EVAR, although there is an agreement on a 5-mm cut-off within 6 months defining aneurysm sac shrinkage or expansion, there is no consensus regarding the methodology that should be used to evaluate the impact of sac dynamics on outcomes. Sac behavior is time dependent, and one patient may develop significant aneurysm growth at a time point then exhibit significant sac shrinkage after the underlying cause has been treated. Taken together, comparing the sac diameter from the latest imaging study with the baseline may be inaccurate. In previous investigations of sac dynamics after standard EVAR, a specific time point 1-year after the procedure has often been preferred,[9-11, 17-19] and this concept was also adopted in the present study. Considering that a majority of patients did not undergo their follow-up CTA exactly at 12 months after the procedure, we opted for a broader time frame (6-18 months) to assess the changes in MADs. This definition aligns with an approach taken in a previous study of standard EVAR.[18]

In the setting of standard EVARs, the incidence of 1-year sac regression ranged from 26% to 53%.[9, 11, 17-19] The present study supported that the incidence of early sac shrinkage may be higher in the context of FB-EVAR of CAAAs and TAAAs; 58% of the patients exhibited 1-year sac shrinkage. In a VQI analysis of 30,074 EVAR patients, the incidence of significant aneurysm expansion was 25%[11]; it was 4% in the current study. However, the 1-year sac change was assessed on a postoperative CTA performed before 12 months in 34% of patients (N=164); this factor potentially underestimated the actual sac expansion rate. The VQI analysis study also highlighted that failure to regress at 1 year correlated positively with reinterventions and the development of new endoleaks.[11] In our cohort, the MAD change at 1- year was not predictive of aortic-related secondary intervention or endoleak-related secondary reinterventions. Indeed, the cumulative incidence curves did not reach statistical significance, but we could think reasonably

that the power of this analysis is too weak and this factor could reach statistical significance with a larger cohort of patients.

Consistent with the previous reports dealing with standard EVAR,[9, 11] we demonstrated a survival benefit in patients with 1-year sac regression compared with those with failure to regress. We also found this was applicable to extent I, II, and III TAAAs, but not CAAAs or extent IV TAAAs, possibly because of comparable characteristics within the aneurysms. The Stanford group assessed the evolution of the aneurysm sac of 132 patients with juxtarenal AAAs treated with Zenith fenestrated (Cook Medical) devices. The authors revealed that patients with sac shrinkage had a lower hazard of late death compared with those with failure to regress. It is worth noting that 33% of the 67 failure to regress patients underwent adjunct target artery parallel grafting at the time of index procedure, compared with only 14% among sac regression patients. Although the authors reported a low incidence of gutter type IA endoleaks among patients having concomitant chimney grafting, it is likely that this adjunct may bias the outcomes when comparing two groups. We also found failure to regress had an increased risk of having late all-cause mortality, but our study cohort received fenestrated-branched investigational aortic devices, which differs from that study.

Several hypotheses potentially explain the association between failure of sac shrinkage and late mortality. Intuitively, patients with persistent aneurysm could be more prone to aortic rupture, related to the loss of stent graft seal or component separation. However, the annual incidence of aortic rupture has been reported as low as 0.9%.[8] Accordingly, we reported the absence of a significant association between failure to regress and ARM or aneurysm rupture, and the major causes of death of our study cohort were comparable with those reported for EVAR patients.[20] Additionally, we found that failure to regress patients had a delayed sac regression at 1 to 3 years after the procedure. However, a Japanese group analyzed 553 EVAR patients with a 55-month median follow-up period.[19] The authors revealed that patients with 1-year failure to regress were more likely to present fatal adverse events, including aneurysm-related death, aneurysm sac rupture, open conversion, or secondary type I or III endoleaks. The median time interval to ARM was 52.4 months; thus, it could be inferred that the incidence of ARM is underestimated given the shorter follow-up period in the present study.

Other authors have brought evidence that sac dynamics is a reflection of the patient's inflammatory status. Although the exact underlying mechanism remains unclear, potentially involving dysregulated immune response, chronic systemic inflammation may lead to persistent aortic wall inflammation affecting post-EVAR remodeling.[21] It

has been assumed that more frail patients would not have the physiological reserve to overcome the increased metabolic demand after endovascular aneurysm repair.[11] To corroborate, we found that patients with 1-year failure to regress were more likely to be older, consistent with previous reports.[11, 12, 18] Elderly patients may be less prone to overcome the energetic demand necessary for sac regression.

There are several limitations in this study. First, the refinement of the surgical technique and improvements in device design over the past decade could impact outcomes related to the likelihood of sac regression, which could alter generalizability. Second, follow-up information may be incomplete in some patients who lost follow-up, and type II errors are very likely. Additionally, the diameters were not double read in a blinded fashion by two experienced surgeons, which could lead potentially to inaccurate measurements. Last, all procedures were performed using IDEs by an experienced operator in two high-volume centers; therefore, the results of this study may not be generalizable to patients treated in other centers and those that used physician-modified stent grafts.

Conclusion

Aneurysm sac shrinkage at 1 year is common (58%) after FB-EVAR and is associated with improved patient survival; sac enlargement affects only a minority of patients (4%). The 5-year all-cause mortality rates were 69% and 46%, respectively, for sac shrinkage and failure to regress patients, but the cumulative incidences of ARM and AAR were 1.1% and 3.1%, respectively, and 0.6% and 2.6%, respectively. The low incidence of ARM indicates that failure to regress may serve as a surrogate marker for nonaortic-related death. Failure to regress does not affect aortic-related secondary interventions.

References

1. Oderich GS, Farber MA, Schneider D, et al. Final 5-year results of the United States Zenith Fenestrated prospective multicenter study for juxtarenal abdominal aortic aneurysms. J Vasc Surg. 2021;73: 1128-38.e2.
2. Isselbacher EM, Preventza O, Hamilton Black J, et al. 2022 ACC/AHA guideline for the diagnosis and management of aortic disease: a report of the American Heart Association/American College of Car- diology Joint Committee on clinical practice guidelines. Circulation. 2022;146:e334-e482.
3. Schanzer A, Oderich GS. Management of abdominal aortic aneu- rysms. N Engl J Med. 2021;385:1690-8.
4. Zettervall SL, Tenorio ER, Schanzer A, et al. Secondary interventions after fenestrated/branched aneurysm repairs are common and nondetrimental to long-term survival. J Vasc Surg. 2022;75: 1530-8.e4.
5. Chaikof EL, Blankensteijn JD, Harris PL, et al. Reporting standards for endovascular aortic aneurysm repair. J Vasc Surg. 2002;35:1048-60.
6. EVAR trial participants. Endovascular aneurysm repair versus open repair in patients with abdominal aortic aneurysm (EVAR trial 1): randomised controlled trial. Lancet. 2005;365:2179-86.
7. Lyons OT, Baguneid M, Barwick TD, et al. Diagnosis of aortic graft infection: a case definition by the management of aortic graft infection collaboration (MAGIC). Eur J Vasc Endovasc Surg. 2016; 52:758-63.
8. Antoniou GA, Alfahad A, Antoniou SA, Torella F. Prognostic signifi cance of aneurysm sac shrinkage after endovascular aneurysm repair. J Endovasc Ther. 2020;27:857-68.
9. Deery SE, Ergul EA, Schermerhorn ML, et al. Aneurysm sac expansion is independently associated with late mortality in patients treated with endovascular aneurysm repair. J Vasc Surg. 2018;67:157-64.
10. Soler RJ, Bartoli MA, Mancini J, et al. Aneurysm sac shrinkage after endovascular repair: predictive factors and long-term follow-up. Ann Vasc Surg. 2015;29:770-9.
11. O'Donnell TFX, Deery SE, Boitano LT, et al. Aneurysm sac failure to regress after endovascular aneurysm repair is associated with lower long-term survival. J Vasc Surg. 2019;69:414-22.
12. Li M, Stern JR, Tran K, Deslarzes-Dubuis C, Lee JT. Predictors of sac regression after fenestrated endovascular aneurysm repair. J Vasc Surg. 2022;75:433-8.
13. Oderich GS, Ribeiro M, Reis de Souza L, Hofer J, Wigham J, Cha S. Endovascular repair of thoracoabdominal aortic aneurysms using fenestrated and branched endografts. J Thorac Cardiovasc Surg. 2017;153:S32-S41.e7.
14. Tenorio ER, Dias-Neto MF, Lima GBB, Estrera AL, Oderich GS. Endo- vascular repair for thoracoabdominal aortic aneurysms: current sta- tus and future challenges. Ann Cardiothorac Surg. 2021;10:744-67.
15. Oderich GS, Forbes TL, Chaer R, et al. Reporting standards for endovascular aortic repair of aneurysms involving the renal- mesenteric arteries. J Vasc Surg. 2021;73:4S-52S.
16. Cleveland WS. Robust locally weighted regression and smoothing scatterplots. J Am Stat Assoc. 1979;74:829-36.
17. Fujimura N, Matsubara K, Takahara M, et al. Early sac shrinkage is a good surrogate marker of durable success after endovascular aneurysm repair in Japanese patients. J Vasc Surg. 2018;67:1410-8.e1.
18. Bastos Goncalves F, Baderkhan H, Verhagen HJ, et al. Early sac shrinkage predicts a low risk of late complications after endovascular aortic aneurysm repair. Br J Surg. 2014;101:802- 10.
19. Ikeda S, Sato T, Kawai Y, et al. One-year sac regression is associated with freedom from fatal adverse events after endovascular aneurysm repair. J Vasc Surg. 2023;77:136-42.e2.
20. Boer GJ, Schroder LBW, Disli MC, Kuijper TM, van de Luijtgaarden KM, Fioole B. A stable aneurysm sac after endovascular aneurysm repair as a predictor for mortality: an in-depth analysis. J Vasc Surg. 2022;76:445-53.
21. Shalaby SY, Foster TR, Hall MR, et al. Systemic inflammatory disease and its association with type II endoleak and late interventions after endovascular aneurysm repair. JAMA Surg. 2016;151:147-53.

Supplemental Material

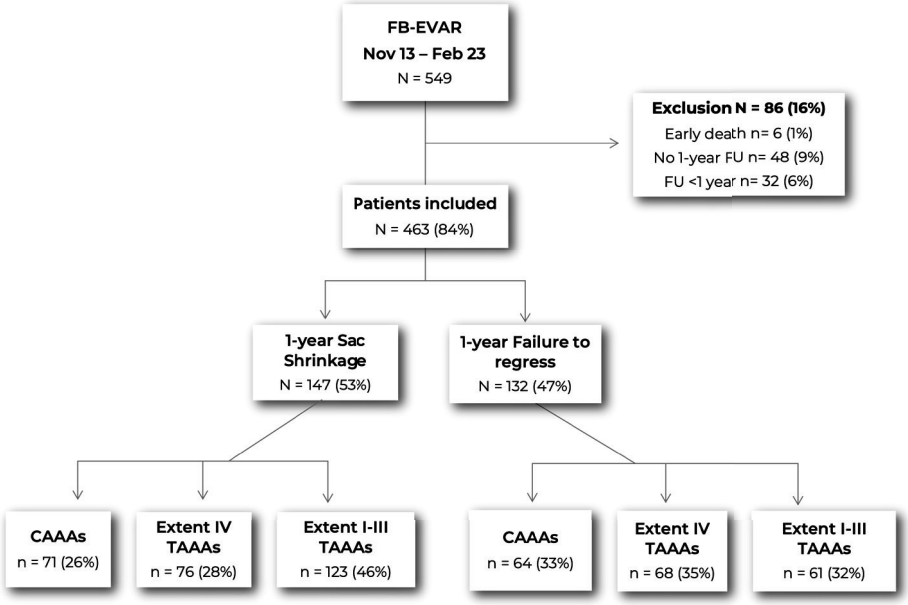

Supplemental Fig 1. Patient screening flow chart. *CAAA*, complex abdominal aortic aneurysm; *FBEVAR*, fenestrated-branched endovascular aortic repair; *FU*, follow-up; *TAAA*, thoracoabdominal aortic aneurysm.

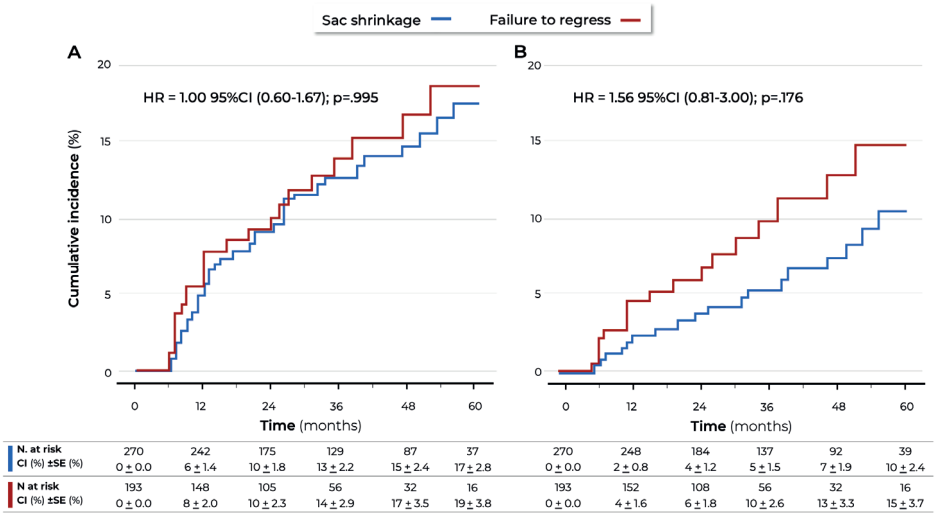

Supplemental Fig 2. (A) Cumulative incidence function of any aortic-related secondary intervention with all-cause death as competing risk for sac shrinkage and failure to regress groups. **(B)** Cumulative incidence function of any endoleak-related secondary intervention with all-cause death as competing risk for sac shrinkage and failure to regress groups. There was no significant difference between the two groups. *CI*, confidence interval; *HR*, hazard ratio.

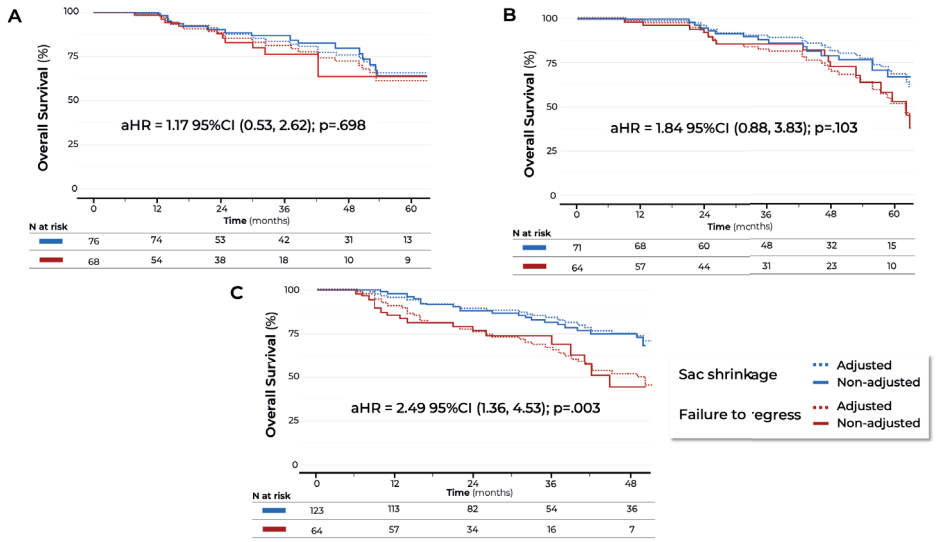

Supplemental Fig 3. Nonadjusted and adjusted Kaplan-Meier survival estimates for sac shrinkage and failure to regress among patients undergoing fenestrated-branched endovascular aortic repair (FB-EVAR) for **(A)** complex abdominal aortic aneurysm (CAAAs), **(B)** extent IV thoracoabdominal aortic aneurysm (TAAAs), or **(C)** extent I, II, or III TAAAs. *aHR*, adjusted hazard ratio; *CI*, confidence interval.

Supplemental Table 1. Distribution of the time interval between the operation and the CTA used for group definition

Time (month)	Overall N=463	Sac shrinkage N=270	Failure to regress N=193
6 to 9 months	56 (12)	25 (9)	31 (16)
10 to 13 months	205 (44)	167 (62)	38 (20)
14 to 18 months	202 (44)	87 (32)	115 (60)

Supplemental Table 2. Thirty-day outcomes of 463 patients undergoing fenestrated-branched endovascular aortic repair (FB-EVAR) stratified by aneurysm sac diameter change

	Overall N=463	Sac shrinkage N=270	Failure to regress N=193	*p*-value
Any major adverse event	63 (14)	37 (14)	26 (13)	.943
Myocardial infarction	10 (2.2)	6 (2.2)	4 (2.1)	>.999
Respiratory failure	10 (2.2)	6 (2.2)	4 (2.1)	>.999
Major stroke	6 (1.3)	3 (1.1)	3 (1.6)	.697
Paraplegia	15 (3.2)	9 (3.3)	6 (3.1)	.893
AKI by RIFLE criteria	34 (7.3)	17 (6.3)	17 (8.8)	.307
Bowel ischemia requiring resection	5 (1.1)	3 (1.1)	2 (1.0)	>.999
Access vessel-related complication	19 (4.1)	14 (5.2)	5 (2.6)	.165
Early reintervention	53 (11)	33 (12)	20 (10)	.536
Length of hospital stay, days	6.7±7.6	6.8±8.4	6.6±6.4	.083

AKI, Acute kidney injury; *RIFLE*, Risk, Injury, Failure, Loss of kidney function, and End-stage kidney disease. Categorical variables are presented as count (percentage) and continuous variables as mean ± standard deviation.

Supplemental Table 3. Multivariable Cox regression analysis of factors associated with late mortality after fenestrated-branched endovascular aortic repair (FB- EVAR)

	aHR (95% CI)	*p*-value
Age (per year increment)	1.04 (1.02, 1.07)	**<.001**
Chronic pulmonary disease at baseline	1.58 (1.18, 2.52)	**.023**
Chronic heart failure at baseline	1.55 (0.88, 2.74)	.131
Chronic kidney disease at baseline	1.10 (0.76, 1.60)	.607
Extent IV TAAA (vs. CAAA)	1.14 (0.68, 1.90)	.616
Extent I, II, III TAAA (vs. CAAA)	2.18 (1.39, 3.42)	**<.001**
1-year failure to regress (vs. 1-year sac shrinkage)	1.72 (1.18, 2.52)	**.005**

aHR, Adjusted hazard ratio; *CAAA*, complex abdominal aortic aneurysm; *CI*, confidence of interval; *TAAA*, thoracoabdominal aortic aneurysm.



Chapter 6

Aneurysm Sac Dynamics and its Prognostic Significance Following Fenestrated and Branched Endovascular Aortic Aneurysm Repair

Vinamr Rastogi[1], Titia A.L. Sulzer[1], Jorg L. de Bruin[1], José Oliveira-Pinto[1,2], Anna J. Alberga[1], Sanne E. Hoeks[3], Frederico Bastos Goncalves[4,5], Sander ten Raa[1], Marie Josee van Rijn[1], George P. Akkersdijk[6], Bram Fioole[6], Hence J.M. Verhagen[1]

[1] Department of Vascular Surgery, Erasmus University Medical Centre, Rotterdam, the Netherlands.
[2] Department of Angiology and Vascular Surgery, Centro Hospitalar São João, Porto, Portugal.
[3] Department of Anaesthetics, Erasmus University Medical Centre, Rotterdam, the Netherlands.
[4] NOVA Medical School - Faculdade de Ciências Médicas (NMS|FCM), Universidade Nova de Lisboa, Lisbon, Portugal.
[5] Hospital CUF Tejo, Lisbon, Portugal.
[6] Department of Vascular Surgery, Maasstad Hospital, Rotterdam, the Netherlands.

Part of this study was presented as an international poster at the Annual Meeting of the Society for Vascular Surgery (San Diego, CA, the United States, August 2021).

European Journal of Vascular and Endovascular Surgery, Volume 67, Issue 5, May 2024, pages 728-736
DOI: 10.1016/j.ejvs.2023.11.033

Abstract

Objective: This study aimed to assess aneurysm sac dynamics and its prognostic significance following fenestrated and branched endovascular aneurysm repair (FB-EVAR).

Methods: Patients undergoing FB-EVAR for degenerative complex aortic aneurysm from 2008 to 2020 at two large vascular centers with two imaging examinations (30 day and one-year) were included. Patients were categorized as regression and non-regression, determined by the proportional volume change (>5%) at one-year compared with 30 days. All-cause mortality and freedom from graft related events were assessed using Kaplan-Meier methods. Factors associated with non-regression at one-year and aneurysm sac volume over time were examined for FEVAR and BEVAR independently using multivariable logistic regression and linear mixed effects modelling.

Results: One hundred and sixty-five patients were included: 122 FEVAR, of whom 34% did not regress at one-year imaging (20% stable, 14% expansion); and 43 BEVAR, of whom 53% failed to regress (26% stable, 28% expansion). Following FB-EVAR, after risk adjusted analysis, non-regression was associated with higher risk of all-cause mortality within five years (hazard ratio [HR] 2.56, 95% confidence interval [CI] 1.09-5.37; *p*=.032) and higher risk of graft related events within five years (HR 2.44, 95% CI 1.10-5.26; *p*=.029). Following multivariable logistic regression, previous aortic repair (odds ratio [OR] 2.56, 95% CI 1.11-5.96; *p*=.029) and larger baseline aneurysm diameter (OR/mm 1.04, 95% CI 1.00-1.09; *p*=.037) were associated with non-regression at one-year, whereas smoking history was inversely associated with non-regression (OR 0.21, 95% CI 0.04-0.96; *p*=.045). Overall following FEVAR, aneurysm sac volume decreased significantly up to two years (baseline vs. two-year, 267 [95% CI 250-285] cm^3 vs. 223 [95% CI 197-248] cm^3), remaining unchanged thereafter. Overall following BEVAR, aneurysm sac volume remained stable over time.

Conclusion: Like infrarenal EVAR, non-regression at one-year imaging is associated with higher five-year all-cause mortality and graft related events risks after FB-EVAR. Following FEVAR for juxtarenal aortic aneurysm, aneurysm sacs generally displayed regression (66% at one-year), whereas after BEVAR for thoraco-abdominal aortic aneurysm, aneurysm sacs displayed a concerning proportion of growth at one-year (28%), potentially suggesting a persistent risk of rupture and consequently requiring intensified surveillance following BEVAR. Future studies will have to elucidate how to improve sac regression following complex EVAR, and whether the high expansion risk after BEVAR is due to advanced disease extent.

Introduction

Numerous publications have reported the technical feasibility and short-term benefits of fenestrated and branched endovascular aneurysm repair (FB-EVAR) compared with complex open repair.[1, 2] However, several studies report that these short-term benefits regarding mortality diminish in the midterm, followed by higher reintervention rates.[2-6, 7, 8]

Like infrarenal endovascular aneurysm repair (EVAR), successful treatment with FB-EVAR is achieved by full exclusion of the aneurysm sac, leading to sac regression or stability.[9] Stable aneurysm sac size, and particularly sac regression, are important prognostic markers for improved mid to long term outcomes, including reduced reintervention rates, after infrarenal EVAR.[10, 11] Moreover, a previous study by O'Donnell et al. also demonstrated that sac regression is associated with greater long term survival compared with a stable sac.[10] However, the literature regarding early sac changes and its prognostic effect in the context of FB-EVAR is scarce.[12] At present, there is little evidence regarding the optimal surveillance strategy after successfully excluding the aneurysm sac following FB-EVAR.[13] Gaining insights into sac dynamics following FB-EVAR may provide a better understanding of its success and help optimizing a personalized imaging follow-up scheme for these patients.

The aim of this study was (1) to evaluate one-year sac dynamics following FB-EVAR to determine its prognostic significance and (2) to identify factors associated with non-regression. Finally, aneurysm sac dynamics were assessed over the first five postoperative years by measuring aneurysm sac volumes for FEVAR and BEVAR independently.

Methods

Study design and patient population

All consecutive patients undergoing FB-EVAR for degenerative aortic aneurysm in two large teaching hospitals in the Netherlands (Erasmus University Medical Centre and Maasstad Hospital, Rotterdam) from 2008 to 2020 were included and studied retrospectively (N=229). The study protocol was approved by the institutional and ethical review board of both hospitals, which waived the need for informed consent due to its retrospective design (MEC-2017-243 and L2018103). Follow-up ended in December 2022. Sizing of stent grafts was performed by an experienced vascular surgeon in collaboration with the manufacturers (Cook's European planning center, London, UK, or Vascutek Ltd.) with final approval by the surgeon.

Data collection and image measurements

Baseline patient demographics, anatomical characteristics of the aneurysm, and clinical success including all individual components were collected for each patient from the hospital's electronic patient database (HiX; ChipSoft, Amsterdam, the Netherlands) following the recommendations of the Society for Vascular Surgery (SVS).[14]

All measurements were obtained by computed tomography (CT) imaging using semi-automatically generated center lumen line reconstructions performed on dedicated reconstruction software (3mensio Vascular 4.2; Pie Medical, Bilthoven, the Netherlands). A previous study of aneurysm volumes has previously been validated for inter- and intra-observer variability by the authors' group in infrarenal abdominal aortic aneurysm (AAA).[15, 16] Three measurement protocols were performed depending on the anatomical variants of complex aneurysmal aortic disease in order to maximize detection of proportional aneurysm sac volume change over time. In the first group, which included juxtarenal AAA, suprarenal AAA, and type IV (Crawford classification) thoracic AAA (TAAA), the volume was measured between 10 mm proximal to the upper renal artery to 10 mm proximal to the aortic bifurcation. In the second group, which consisted of types I and V TAAA, the volume was measured from 10 mm distal to the left subclavian artery to 10 mm proximal to the upper renal artery. Finally, the third group included types II and III TAAA which were measured from 10 mm distal to the left subclavian artery to 10 mm above the iliac bifurcation.

Definitions and outcomes

Sac changes were determined at one-year (to allow a grace period, the CT image between six-24 months was used) and at last imaging follow-up. Sac regression and sac growth were considered to have occurred when the volume decreased or increased, respectively, by >5% from baseline value (first postoperative CT angiogram [CTA] as per SVS reporting guidelines).[17] In the case of staged repair, baseline imaging was defined as the first CTA after full exclusion of the aorta was achieved, or after verification of an occlusion of the remaining open branch on CTA or angiography. Chronic kidney disease was defined as an estimated glomerular filtration rate <60 mL/kg/m^2. Patients treated with an endograft that included both fenestrations and branches were included in the BEVAR group. Scallops were not included as fenestrations. Patients were categorized depending on the occurrence of sac regression at one-year imaging as regression or non-regression. Performance of a graft related reintervention before one-year imaging was defined as early reintervention.

The primary outcome was five-year all-cause mortality. Secondary outcomes included occurrence of a graft related event following one-year imaging, which was a composite outcome of a graft related complication (type I/III endoleak, migration, graft infection, secondary rupture, visceral patency loss) or procedure (proximal cuff, distal extension, visceral percutaneous transluminal angioplasty, visceral stent).[12, 13] Furthermore, factors associated with non-regression at one-year imaging were assessed. Finally, aneurysm sac dynamics over time were examined for FEVAR and BEVAR independently.

Statistical analysis

Categorical variables were presented as counts and percentages. Continuous variables were presented either as mean ± standard deviation or median and interquartile range (IQR) depending on whether the results were normally distributed. Normal distribution was tested with visual aid and the Shapiro-Wilk test. When comparing categorical variables between two groups, Pearson's χ^2 test or Fisher's exact test (in case of counts <8) was used. For comparison of continuous variables, independent Student's t test or Mann-Whitney *U* test was used, for parametric and non-parametric data, respectively. Statistical significance was defined as a *p*-value of <.050.

To examine the prognostic effect of regression and non-regression at one-year imaging, Kaplan-Meier methods were used to estimate the five-year mortality and graft related event risks following FB-EVAR. Multivariable Cox regression analysis was performed to adjust for confounding. Covariables that were included in the multivariable Cox regression model were age, sex, smoking history, previous aortic repair, aneurysm diameter at baseline, endograft configuration (FB-EVAR), and early reintervention.

Multivariable logistic regression was performed to determine factors associated with non-regression at one-year imaging among the FB-EVAR cohort. Factors in the model were pre-defined and were the same as those entered in the Cox regression model.

To investigate the aneurysm sac volume over time, two longitudinal mixed effects models were made for FEVAR and BEVAR independently owing to heterogeneity in disease extent between the respective treatment modalities. In these models, time was entered as the independent variable and aneurysm volume as the dependent variable, assuming random intercepts and slopes to allow individual variation per patient (fixed: time + time^2 [+ time^3]; random: ~time) (**Supplemental Table 1**). To compare the time sensitivity of the models, the models were run with and without different polynomial terms for time, and the difference in likelihood ratios was calculated.[18]

All statistical analyses were performed using IBM SPSS Statistics version 25.0.0.1 (IBM Corp., Armonk, NY, USA) and R version 4.0.3 (http://www.r-project.org).

Results

Patient population

Initially, 229 patients were included. Patients with less than two postoperative CTAs (N=64; 27.9%) were excluded. Of these, 21 patients (9.2%) did not have adequate (at least two postoperative CTAs) imaging follow-up due to death before one-year, and 19 patients (8.3%) were excluded as they received their CTA imaging outside of the imaging grace period. Five patients (2.2%) received follow-up with duplex ultrasound, thus no aneurysm volume could be measured. Finally, 19 patients (8.3%) were excluded as they did not have complete CTAs, thus aneurysm volumes could not be measured, or because they were lost in follow-up.

Baseline characteristics

A total of 165 patients were included for analysis, of whom 64 patients (38.8%) displayed non-regression at one-year imaging (fenestrated EVAR, 34%; branched EVAR, 53%). Of these, 35 patients (21.2%) had a stable sac (fenestrated EVAR, 20%; branched EVAR, 26%) and 29 patients (17.6%) had sac expansion (fenestrated EVAR, 14%; branched EVAR, 28%).

The non-regression cohort was significantly older (76 [IQR 71, 81] years vs. 72 [IQR 69, 77] years; p=.006), was less likely to have a history smoking (80% vs. 93%; p=.034) but was more likely to have undergone previous aortic repair (58% vs. 23%; p<.001) (**Table 1**). Specifically, the non-regression cohort was more likely to have undergone previous endovascular AAA repair (41% vs. 7.9%; p<.001). Furthermore, patients in the non-regression cohort had a larger aortic diameter at baseline (63.8 [IQR 58.7, 73.0] mm vs. 59.5 [IQR 56.8, 63.7] mm; p<.001) as well as a larger aneurysm volume at baseline (264 [IQR 191, 337] cm^3 vs. 233 [IQR 193, 281] cm^3; p=.001). Patients who displayed non-regression were significantly more likely to have undergone branched EVAR (36% vs. 20%; p=.034) but did not have a significantly higher rate of more proximal disease (suprarenal/TAAA, 41% vs. 26%; p= .11) or a higher number of target vessels (four vessel device, 56% vs. 42%; p=.23). Between groups, no differences were found in endoleaks on 30-day imaging. Finally, there was no difference in early reintervention rate between groups (23% vs. 12%; p=.082).

Table 1. Baseline characteristics of imaging cohort undergoing fenestrated and branched endovascular aneurysm repair (FB-EVAR) (N=165) stratified by occurrence of sac regression (>5%) within one-year

	Fenestrated/branched endovascular aneurysm repair (N=165)		
Characteristics	Non-regression 38.8% (N=64)	Regression 61.2% (N=101)	*p*-value
Stable sac	35/165 (21.1)	NA	
Sax expansion	29/165 (17.6)	NA	
Age, years	76 [71-81]	72 [69,77]	**.006**
Female sex	13 (20)	25 (24.8)	.64
Smoking history	52 (81)	94 (93.1)	**.034**
Hypertension	56 (88)	84 (83.2)	.54
PAOD	25 (39)	42 (41.6)	.94
Myocardial infarction	17 (27)	26 (25.7)	1.0
COPD	24 (38)	35 (34.7)	.94
Prior CKD (eGFR<60 mL/kg/m^2)	24 (38)	36 (35.6)	.80
Prior aortic repair	37 (58)	23 (22.8)	**<.001**
Open AAA repair	3 (5)	7 (6.9)	
Endovascular AAA repair	26 (41)	8 (7.9)	
Thoracic endovascular aortic repair	2 (3)	8 (7.9)	
Multiple procedures	3 (5)	0 (0.0)	
Proximal aneurysm extent			.11
Juxtarenal	38 (59)	75 (74.3)	
Suprarenal/TAAA Type IV	8 (13)	10 (9.9)	
TAAA Type II/III	11 (17)	13 (12.9)	
TAAA Type I/V	7 (11)	3 (3.0)	
Baseline aneurysm diameter (mm)	63.8 [58.7-73.0]	59.5 [56.8-63.7]	**<.001**
Baseline aneurysm volume (cm^3)	264 [191-337]	233 [193-281]	**.001**
Branched EVAR	24 (38)	20 (19.8)	**.034**
Target vessels (fenestration/branch)			.23
1- vessel	1 (2)	1 (1.0)	
2- vessel	4 (6)	17 (16.8)	
3- vessel	23 (36)	41 (40.6)	
≥4- vessel	36 (56)	42 (41.6)	
30-day endoleak	9 (14)	12 (11.9)	.87
Type IA	1 (2)	2 (2.0)	.69
Type IB	0 (0.0)	0 (0.0)	NA
Type IC	3 (5)	7 (6.9)	.87
Type II	8 (13)	6 (5.9)	.24
Type IIIA	0 (0.0)	1 (1.0)	1.0
Early reintervention*	15 (23)	12 (11.9)	.082

Data are presented as N (%) or median (interquartile range). Due to rounding, numbers may not add up. *NA*, not applicable; *PAOD*, peripheral arterial occlusive disease; *COPD*, chronic obstructive pulmonary disease; *CKD*, chronic kidney disease; *eGFR*, estimated glomerular filtration rate; *AAA*, abdominal aortic aneurysm; *TAAA*, thoracic abdominal aortic aneurysm.

* Before one-year imaging.

Five-year all-cause mortality

Of all 165 patients, 33 patients (20.0%) had five years of follow-up.

After risk adjustment, non-regression was associated with a significantly higher five-year all-cause mortality risk (34% vs. 26%; hazard ratio [HR] 2.56, 95% confidence interval [CI] 1.09-5.37; *p*=.032) (**Fig 1**).

Following multivariable Cox regression analysis, no other factors were found to be associated with five-year mortality, including branched device (HR 0.93, 95% CI 0.35-2.25; *p*=.88) and early reintervention (HR 0.46, 95% CI 0.11-1.89; *p*=.28).

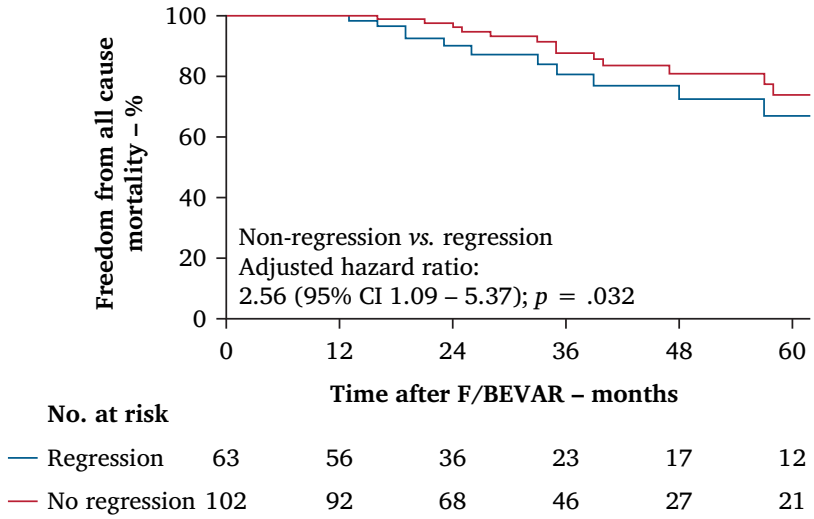

Fig 1. Cumulative Kaplan-Meier estimate of freedom from all-cause mortality stratified by occurrence of aneurysm volume regression (>5%) within the first year following fenestrated and branched endovascular aneurysm repair (FB-EVAR), adjusted for age, sex, endograft configuration (FB-EVAR), baseline aneurysm diameter, previous aortic repair, smoking history, and early reintervention. The unadjusted hazard ratio is given in **Supplemental Table 2**.

Five-year graft related events

Non-regression was associated with a significantly higher risk of five-year graft related events (50% vs. 25%; HR 2.44, 95% CI 1.10-5.26; *p*=.029) (**Fig 2**). The details of the graft related events are shown in **Table 2**. Furthermore, female sex was found to be associated with a higher risk of graft related events (HR 2.53, 95% CI 1.11-5.78; *p*=.027). Other factors, including branched device (HR 0.83, 95% CI 0.37-1.90; *p*=.67) and early reintervention (HR 0.57, 95% CI 0.17-2.00; *p*=.38) were not associated with a higher risk of graft related events.

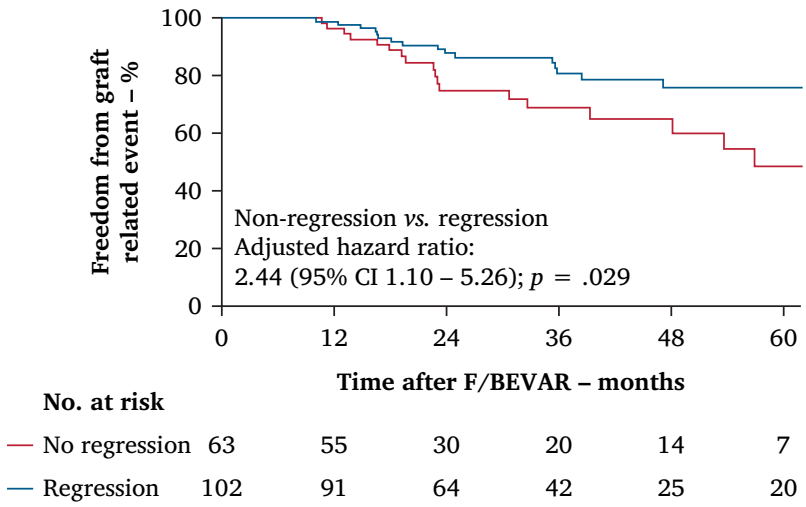

Fig 2. Cumulative Kaplan-Meier estimate of freedom from graft related events stratified by occurrence of aneurysm volume regression (>5%) within the first year following fenestrated and branched endovascular aneurysm repair (FB-EVAR), adjusted for age, sex, endograft configuration (FB-EVAR), baseline aneurysm diameter, previous aortic repair, smoking history, and early reintervention. The unadjusted hazard ratio is given in **Supplemental Table 2**.

Factors associated with non-regression at one-year imaging

Factors that were associated with non-regression at one-year imaging included previous aortic repair (odds ratio [OR] 2.56, 95% CI 1.11-5.96; *p*=.029) and larger aneurysm diameter at baseline (OR/mm 1.04, 95% CI 1.00-1.09; *p*=.037). Smoking history was inversely associated with non-regression (OR 0.21, 95% CI 0.04-0.96; *p*=.045) (**Table 3**). In contrast, procedural characteristics, such as endograft configuration, were not associated with non-regression at one-year imaging (branched vs. fenestrated EVAR, OR 1.52, 95% CI 0.57-4.12; *p*=.41). Furthermore, early reintervention following FB-EVAR was also not significantly associated with non-regression (OR 1.76, 95% CI 0.62-5.00; *p*=.28).

Aneurysm sac dynamics over time

Overall following FEVAR, aneurysm sac volume decreased significantly up to two years: two years vs. baseline, 223 (95% CI 197-248) cm^3 vs. 267 (95% CI 250-285) cm^3, remaining unchanged thereafter (**Fig 3**).

Overall following BEVAR, in the full population, aneurysm sac volume remained stable over the five-year time period (**Fig 3**). It must be noted that this is an average and that independent volume trajectories may be variable.

Table 2. Details of graft related events following fenestrated and branched endovascular aneurysm repair (FB-EVAR) (N=165) stratified by occurrence of sac regression (>5%) within one-year

	Fenestrated/branched endovascular aneurysm repair (N=165)		
	No regression 39% (N=64)	Regression 61% (N=101)	*p*-value
Median follow-up (months)	35 [20-67]	41 [25-66]	**<.001**
Graft-related events, No. of patients	19	18	**.029***
Graft-related complications, No. of patients	13	14	.23*
Post-implant rupture	1	2	
Secondary endoleaks			
Type IA	1	2	
Type IB	2	1	
Type IC	0	2	
Type II	6	3	
Type IIIa	1	0	
Migration	0	0	
Graft thrombosis	0	0	
Endograft infection	0	1	
Visceral occlusion	1	3	
Permanent paraplegia	1	0	
Secondary interventions, No. of patients	11	10	.098*
Secondary interventions			
Proximal cuff	2	3	
Distal extension	3	2	
Visceral PTA	1	2	
Visceral restenting	1	1	
Coiling/gluiing/embolization	2	1	
Open/laparoscopic ligation of collaterals	1	0	
Surgical intervention**	1	1	

Data are presented as N or median (interquartile range). Due to rounding, numbers may not add up. *PTA*, percutaneous transluminal angioplasty. * Calculated using log rank analysis. ** Surgical interventions included explantation for graft infection and laparoscopic ligation of type II endoleak.

Table 3. Multivariable logistic regression of factors associated with aneurysm sac non-regression at one-year following fenestrated and branched endovascular aneurysm repair (FB-EVAR) and FEVAR in 64 patients

Factors	Odds ratio (95% CI)	*p*-value
Age (per year)	1.04 (0.98-1.11)	.17
Female sex	0.62 (0.22-1.61)	.34
Smoking history	0.21 (0.04-0.96)	**.045**
Prior aortic repair	2.56 (1.11-5.96)	**.029**
Aneurysm diameter at baseline (per mm)	1.04 (1.00-1.09)	**.037**
Branched device (ref: Fenestrated)	1.52 (0.57-4.12)	.41
Reintervention before 1-year imaging	1.76 (0.62-5.00)	.28

OR, odds ratio; *CI*, confidence interval.

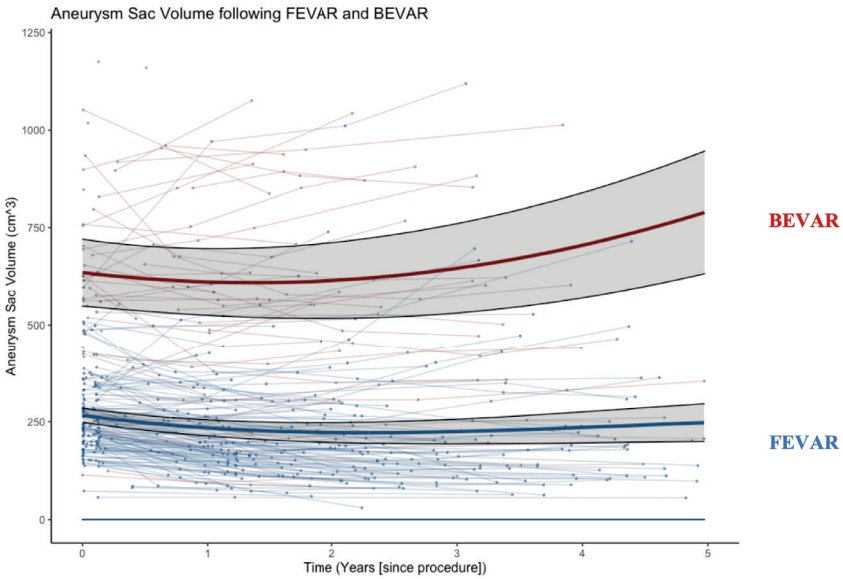

	Baseline	1 year	2 years	3 years	4 years	5 years
BEVAR Aneurysm volume – cm^3 (95% CI)	635 (549 – 721)	611 (525 – 696)	614 (517 – 712)	646 (531 – 760)	704 (570 – 839)	794 (635 – 949)
FEVAR Aneurysm volume, cm^3 (95% CI)	267 (250 – 285)	234 (214 – 255)	**223 (197 – 248)**	225 (193 – 257)	236 (196 – 275)	248 (200 – 296)

Fig 3. Linear mixed effects model displaying aneurysm sac volume (cm3) over time for 165 patients undergoing (A) fenestrated endovascular aneurysm repair (FEVAR) patients and (B) branched endovascular aneurysm repair (BEVAR). *CI*, confidence interval.

Discussion

The present study shows that, like infrarenal EVAR, absence of aneurysm sac regression at one-year was associated with higher five-year all-cause mortality and graft related event risks following FB-EVAR. Disease specific factors such as previous aortic repair and aneurysm diameter at baseline were associated with non-regression, while early reintervention (before one-year imaging) was not associated with a higher likelihood of non-regression or a higher five-year mortality or graft related event risk. Finally, it was found that patients who underwent FEVAR generally regress up to the two-year time point, remaining unchanged thereafter up to five years. Following BEVAR, aneurysm sac volume on average remained unchanged over the course of five years postoperatively, although a significant proportion displayed sac expansion at the one-year time point (28%).

The finding of an association between one-year aneurysm sac dynamics after FB-EVAR and all-cause mortality corroborates previous findings in the context of infrarenal EVAR.[10, 19] Initially, Deery et al. demonstrated the association between expansion and mortality using data from a regional registry (N=2,437).[19] Thereafter, using a large national database (N=14,817), O'Donnell et al. demonstrated that sac regression is associated with better survival, even when compared with a stable sac.[10] Interestingly, a similar association between one-year aneurysm sac dynamics and mortality following FB-EVAR was also found in a much smaller sample size. Given the present authors' finding in this smaller sample size, it may be hypothesized that the association between one-year aneurysm sac dynamics and mortality is stronger in the context of FB-EVAR, although future studies will need to confirm these findings. There are various theories explaining the reason for the association between one-year aneurysm sac dynamics and mortality, as a potential increase in rupture in patients with non-regression, though attributable, does not fully capture the mortality difference that is found between the regression and non-regression groups. Non-regression has previously been shown to be associated with an inflammatory cascade.[20-22] Based on these findings, it has been suggested that this association between non-regression and systemic inflammation may secondarily lead to higher atherothrombosis and cardiovascular mortality. However, recently Boer et al. published a single center series in which they compared causes of death between patients with a stable sac and sac regression at one-year but found no statistically significant difference between groups.[23]

The current results also demonstrate that, just as following infrarenal EVAR, sac regression at one-year imaging is also prognostically favorable after FB-EVAR, given its association with the occurrence of graft related events.[24] Antoniou et al. performed a meta-analysis regarding the prognostic significance of early sac regression following infrarenal EVAR, suggesting that patients with different sac dynamics may require different surveillance strategies.[11] Again, due to the lack of any customized FB-EVAR surveillance strategy, most FB-EVAR patients may follow a regimen similar to their infrarenal counterparts. Although an association was found between one-year aneurysm sac dynamics and graft related events, this study population was limited to assess individual outcomes adequately. Furthermore, it will be of the utmost importance to gain insights into long-term sac dynamics in those patients who regress effectively in order to eliminate any concerns of potential late sac expansion. On these grounds, this study alone does not provide enough evidence to suggest any relaxation in surveillance in patients who demonstrate regression, but this remains an interesting topic for future research.

It was also found that disease specific variables, such as previous aortic repair and baseline aneurysm diameter, were associated with non-regression. Previous studies have elucidated the increased technical challenges that are associated with salvage of previous endovascular repair.[25, 26] It could be hypothesized that this is due to an aggressive continuous disease process in these patients. Similarly, it could be suggested that aneurysm diameter may also be a proxy for disease severity, potentially explaining the reduced likelihood of regression in larger aneurysms. Due to a lack of factors that could be included in the model, proximal disease extent was not accounted for, although it is believed that the previously mentioned disease specific factors are also a proxy for this variable, and future studies with larger numbers will have to investigate this further. Another variable that could not be studied independently due to the limited number of variables that could be added to the model was the type of previous aortic repair. However, the data suggest that patients who underwent previous endovascular AAA repair might be driving this difference. Future studies will have to identify whether this is due to, e.g., a high proportion of persistent endoleaks, biological factors of these aneurysms, or another cause. Moreover, it was found that smoking history was inversely associated with non-regression, and these findings are in line with findings from previous studies in the context of infrarenal EVAR.[11] For infrarenal AAA, other factors that have been theoretically linked to sac regression are use of a statin, diabetic status, and use of calcium channel blockers.[27, 28] Determining other factors associated with non-regression remains an interesting point for future research, as adding a large number of factors to the models was limited due to limited sample size.

Interestingly, it was found that early reintervention (before one-year imaging) was not significantly associated with non-regression, which contrasts with previous findings in infrarenal EVAR.[10] Previous studies have reported that early reintervention after infrarenal EVAR is associated with higher mortality, although this is not the case after FEVAR.[29-31] The current findings also confirm the lack of an association between early reintervention following FB-EVAR and mortality. It may be suggested that early reinterventions following FB-EVAR are inherently different from those performed following infrarenal EVAR, as large parts of the reinterventions following FB-EVAR are probably related to technical failure of the fenestrations and branches. Future studies will have to confirm these findings in larger sample sizes and independently assess which specific reinterventions or types of endoleaks may be associated with non-regression of the aneurysm sac.

The observations regarding postoperative aneurysm sac behavior may support adequate midterm effectiveness of FEVAR, as the majority of FEVAR patients displayed aneurysm sac regression (66%) at one-year imaging. This is higher than previously

observed in infrarenal EVAR (40-52%).[10,24] There is a paucity of data regarding aneurysm sac dynamics after FB-EVAR, highlighting the importance of the present findings. Furthermore, aneurysm sac dynamics were determined by aneurysm volume, and this metric has previously been shown to be more sensitive in detection of subtle sac changes in follow-up compared with aneurysm diameter.[32] Hypothetically, the importance of measuring aneurysm sac volume for postoperative sac change detection may be of increased importance in the FB-EVAR population because, due to the increased disease extent, the aneurysm sac could regress or expand above or below the diameter measurement plane. Despite the satisfactory sac dynamics following FEVAR, patients undergoing BEVAR displayed more concerning sac dynamics, with a significant proportion of 28% displaying sac expansion at one-year. To the authors' knowledge, this study is the first to report one-year aneurysm sac dynamics following BEVAR, and future studies will have to confirm these findings. It is hypothesized that the high risk of expansion at one-year following BEVAR is due to the increased disease extent rather than due to treatment effectiveness, as BEVAR generally has longer sealing zones compared with FEVAR. Moreover, the prior argument is supported by the data regarding the associations between disease specific variables (previous aortic repair and baseline diameter) and non-regression, thus these data do not directly suggest that BEVAR is an ineffective therapy. Otherwise, this difference could be secondary to a difference in type II endoleaks in BEVAR patients owing to the increased aortic coverage in BEVAR vs. FEVAR. Although a higher rate of type II endoleaks on the baseline CTA scan in the non-regression group was not seen, this may be secondary to the smaller population. Nevertheless, due to the current lack of a customized FB-EVAR surveillance strategy, FB-EVAR patients frequently undergo similar surveillance to infrarenal EVAR patients. The current results may potentially suggest intensified monitoring of BEVAR patients, but this will have to be elucidated in future larger studies.

This study needs to be interpreted within the context of its retrospective design. Only patients with adequate imaging follow-up were included as no imaging analyses could have been performed otherwise. Furthermore, this study was prohibited in assessing aneurysm related mortality as autopsies are not routinely done in the Netherlands, limiting cause of death diagnostic accuracy. Although aneurysm sac volume methodologies are more accurate and sensitive, these usually remain time consuming and laborious. Furthermore, as volumes were measured based upon the extent of the specific pathology, this might have led to slight variability within the cohorts, although these mostly remained uniform within the respective endograft configurations. Thus, preoperative aneurysm volume could not be factored in multivariable adjustment, but preoperative

aneurysm diameter was used instead. As aneurysm sac volumes were used for analyses, it was not possible to use measurements from duplex ultrasound, which was one reason to extend the grace period of the one-year imaging scan to 6-24 months (compared with 6-18 months as previously used in the context of infrarenal EVAR). Furthermore, an extended grace period was used for the first postoperative scan after FB-EVAR as an early reintervention frequently did not fall within the grace period of 6-18 months. However, sensitivity analyses were performed with the 6-18-month grace period, displaying similar trends in outcomes. Another limitation was the population size, especially in the BEVAR group with relatively low numbers. Subsequently, low event rates could have led to the presence of type II errors. Furthermore, as the inclusion was done over a 12-year period, this could have led to treatment heterogeneity, and thus future studies will be required to validate the findings. Moreover, due to a limited sample size, it was not possible to account for variables such as endograft type (Zenith COOK Fenestrated AAA Graft vs. Vascutek Fenestrated Anaconda Custom AAA Stent Graft System) and preoperative statin use, although this remains an important subject for future research. Furthermore, granularity such as family history or timing of smoking was not included, although these may also be important factors for future research. Granularity regarding preoperative antithrombotic therapy (i.e., antiplatelet or anti-coagulation) was also not included, but this remains an important factor for future studies, as a recent study by Stern and Lee reported an association between anticoagulation use and persistent type II endoleak.[33] Finally, registration of complications was mainly dependent on the number and timing of postoperative CTAs. An attempt to correct for this using a composite outcome was made, but this limitation remains a lead for information bias.

Conclusion

Just as following infrarenal EVAR, non-regression at one-year imaging is associated with higher five-year all-cause mortality and graft related event risk after FB-EVAR. Furthermore, disease specific variables such as previous aortic repair and baseline aneurysm diameter were associated with non-regression at one-year imaging, whereas early reintervention before one-year imaging was not. Following FEVAR for juxtarenal aortic aneurysm, aneurysm sacs generally displayed regression (one-year, 66%), whereas after BEVAR for thoraco-abdominal aortic aneurysm, a concerning proportion displayed growth at one-year (28%), potentially suggesting an increased or persistent risk of rupture and requiring intensified surveillance following BEVAR. Future studies will have to elucidate how to improve sac regression following complex EVAR, and whether the high expansion risk after BEVAR is due to advanced disease extent.

References

1. Varkevisser RRB, O'Donnell TFX, Swerdlow NJ, Liang P, Li C, Ultee KHJ, et al. Fenestrated endovascular aneurysm repair is associated with lower perioperative morbidity and mortality compared with open repair for complex abdominal aortic aneurysms. J Vasc Surg 2019;69:1670-8.
2. O'Donnell TFX, Boitano LT, Deery SE, Schermerhorn ML, Schanzer A, Beck AW, et al. Open versus fenestrated endovascular repair of complex abdominal aortic aneurysms. Ann Surg 2020;271:969-77.
3. Arnaoutakis DJ, Scali ST, Beck AW, Kubilis P, Huber TS, Martin AJ, et al. Comparative outcomes of open, hybrid, and fenestrated branched endovascular repair of extent II and III thoracoabdominal aortic aneurysms. J Vasc Surg 2020;71:1503-14.
4. DeerySE,LancasterRT,BarilDT,IndesJE,BertgesDJ,ConradMF, et al. Contemporary outcomes of open complex abdominal aortic aneurysm repair. J Vasc Surg 2016;63:1195-200.
5. Chinsakchai K, Prapassaro T, Salisatkorn W, Hongku K, Moll FL, Ruangsetakit C, et al. Outcomes of open repair, fenestrated stent grafting, and chimney grafting in juxtarenal abdominal aortic aneurysm: is it time for a randomized trial? Ann Vasc Surg 2019;56:114-23.
6. Tinelli G, Crea MA, de Waure C, Di Tanna GL, Becquemin JP, Sobocinski J, et al. A propensity-matched comparison of fenestrated endovascular aneurysm repair and open surgical repair of pararenal and paravisceral aortic aneurysms. J Vasc Surg 2018;68:659-68.
7. Jones AD, Waduud MA, Walker P, Stocken D, Bailey MA, Scott DJA. Meta-analysis of fenestrated endovascular aneurysm repair versus open surgical repair of juxtarenal abdominal aortic aneurysms over the last 10 years. BJS Open 2019;3:572-84.
8. Antoniou GA, Juszczak MT, Antoniou SA, Katsargyris A, Haulon S. Editor's Choice e Fenestrated or branched endovascular versus open repair for complex aortic aneurysms: meta-analysis of time to event propensity score matched data. Eur J Vasc Endovasc Surg 2021;61:228-37.
9. Lee JT, Aziz IN, Lee JT, Haukoos JS, Donayre CE, Walot I, et al. Volume regression of abdominal aortic aneurysms and its relation to successful endoluminal exclusion. J Vasc Surg 2003;38:1254-63.
10. O'Donnell TFX, Deery SE, Boitano LT, Siracuse JJ, Schermerhorn ML, Scali ST, et al. Aneurysm sac failure to regress after endovascular aneurysm repair is associated with lower long-term survival. J Vasc Surg 2019;69:414-22.
11. Antoniou GA, Alfahad A, Antoniou SA, Torella F. Prognostic significance of aneurysm sac shrinkage after endovascular aneurysm repair. J Endovasc Ther 2020;27:857-68.
12. Li M, Stern JR, Tran K, Deslarzes-Dubuis C, Lee JT. Predictors of sac regression after fenestrated endovascular aneurysm repair. J Vasc Surg 2022;75:433-8.
13. Wanhainen A, Verzini F, Van Herzeele I, Allaire E, Bown M, Cohnert T, et al. Editor's Choice e European Society for Vascular Surgery (ESVS) 2019 clinical practice guidelines on the management of abdominal aorto-iliac artery aneurysms. Eur J Vasc Endovasc Surg 2019;57:8-93.
14. Oderich GS, Forbes TL, Chaer R, Davies MG, Lindsay TF, Mastracci T, et al. Reporting standards for endovascular aortic repair of aneurysms involving the renal-mesenteric arteries. J Vasc Surg 2021; 73(1S):4S-52S.
15. Van Prehn J, Van Der Wal MBA, Vincken K, Bartels LW, Moll FL, Van Herwaarden JA. Intra- and interobserver variability of aortic aneurysm volume measurement with fast CTA postprocessing software. J Endovasc Ther 2008;15:504-10.
16. Bastos Gonçalves F, van de Luijtgaarden KM, Hoeks SE, Hendriks JM, ten Raa S, Rouwet EV, et al. Adequate seal and no endoleak on the first postoperative computed tomography angiography as criteria for no additional imaging up to 5 years after endovascular aneurysm repair. J Vasc Surg 2013;57:1503-11.
17. Chaikof EL, Blankensteijn JD, Harris PL, White GH, Zarins CK, Bernhard VM, et al. Reporting standards for endovascular aortic aneurysm repair. J Vasc Surg 2002;35:1048-60.
18. Laird NM, Ware JH. Random-effects models for longitudinal data. Biometrics 1982;38:963-74.
19. Deery SE, Ergul EA, Schermerhorn ML, Siracuse JJ, Schanzer A, Goodney PP, et al. Aneurysm sac expansion is independently associated with late mortality in patients treated with endovascular aneurysm repair. J Vasc Surg 2018;67:157-64.
20. Aday AW, Ridker PM. Antiinflammatory therapy in clinical care: the CANTOS trial and beyond. Front Cardiovasc Med 2018;5:62.

21. Ridker PM, Danielson EMIA, Fonseca F, Genest J, Gotto AM, Kastelein JJP, et al. Rosuvastatin to prevent vascular events in men and women with elevated C-reactive protein. N Engl J Med 2008;359:2195-207.
22. Ridker PM, Everett BM, Thuren T, MacFadyen JG, Chang WH, Ballantyne C, et al. Antiinflammatory therapy with canakinumab for atherosclerotic disease. N Engl J Med 2017;377:1119-31.
23. Boer GJ, Schröder LBW, Disli MC, Kuijper TM, van de Luijtgaarden KM, Fioole B. A stable aneurysm sac after endovascular aneurysm repair as a predictor for mortality: an in-depth analysis. J Vasc Surg 2022;76:445-53.
24. Bastos Gonçalves F, Baderkhan H, Verhagen HJM, Wanhainen A, Björck M, Stolker RJ, et al. Early sac shrinkage predicts a low risk of late complications after endovascular aortic aneurysm repair. Br J Surg 2014;101:802-10.
25. Katsargyris A, Yazar O, Oikonomou K, Bekkema F, Tielliu I, Verhoeven ELG. Fenestrated stent-grafts for salvage of prior endovascular abdominal aortic aneurysm repair. Eur J Vasc Endovasc Surg 2013;46:49-56.
26. Falkensammer J, Taher F, Uhlmann M, Hirsch K, Strassegger J, Assadian A. Rescue of failed endovascular aortic aneurysm repair using the fenestrated Anaconda device. J Vasc Surg 2017;66:1334-9.
27. Lalys F, Daoudal A, Gindre J, Göksu C, Lucas A, Kaladji A. Influencing factors of sac shrinkage after endovascular aneurysm repair. J Vasc Surg 2017;65:1830-8.
28. Bailey MA, Sohrabi S, Flood K, Griffin KJ, Rashid ST, Johnson AB, et al. Calcium channel blockers enhance sac shrinkage after endovascular aneurysm repair. J Vasc Surg 2012;55:1593-9.
29. Deery SE, O'Donnell TFX, Bodewes TCF, Dalebout BA, Pothof AB, Shean KE, et al. Early reintervention after open and endovascular abdominal aortic aneurysm repair is associated with high mortality. J Vasc Surg 2018;67:433-40.
30. Dossabhoy SS, Sorondo SM, Tran K, Stern JR, Dalman RL, Lee JT. Reintervention does not impact long-term survival after fenestrated endovascular aneurysm repair. J Vasc Surg 2022;76:1180-8.
31. Zettervall SL, Tenorio ER, Schanzer A, Oderich GS, Timaran CH, Schneider DB, et al. Secondary interventions after fenestrated/ branched aneurysm repairs are common and nondetrimental to long-term survival. J Vasc Surg 2022;75:1530-8.
32. Oliveira-Pinto J, Soares-Ferreira R, Oliveira NFG, Bouwens E, Bastos Gonçalves FM, Hoeks S, et al. Aneurysm volumes after endovascular repair of ruptured vs intact aortic aneurysms: a retrospective observational study. J Endovasc Ther 2021;28:146-56.
33. Stern JR, Lee JT. Factors associated with sac regression after F/BEVAR for complex abdominal and thoracoabdominal aneurysms. Semin Vasc Surg 2022;35:306-11.

Supplemental Material

Supplemental Table 1. Predicted values of the fixed portion of mixed effects model for patients undergoing fenestrated endovascular aneurysm repair (FEVAR) and branched endovascular aneurysm repair (BEVAR) independently

FEVAR aneurysm sac volume (cm^3)	Coefficient	Standard Error	t-value	*p*-value
Fixed portion				
Time (years)	-44.5	7.41	-6.01	**<.001**
[Time]^2 (years)	13.3	2.94	4.53	**<.001**
[Time]^3 (years)	-1.03	0.30	-3.39	**<.001**
Constant	267	9.37	28.5	**<.001**

BEVAR aneurysm sac volume (cm^3)	Coefficient	Standard Error	t-value	*p*-value
Fixed portion				
Time	-37.9	17.9	-2.11	**.037**
(Time)^2	13.9	2.55	5.44	**<.001**
Constant	634	44.1	14.4	**<.001**

Supplemental Table 2. Unadjusted hazard ratios for all-cause mortality and graft related events for 1-year non-regression versus regression patients following fenestrated/branched endovascular aneurysm repair (FB-EVAR)

Non-regression vs. regression	Hazard ratio	95% confidence interval	*p*-value
All-cause mortality	1.80	0.94-3.48	.079
Graft-related events	2.14	1.12-4.11	**.022**



Chapter 7

Midterm Outcomes and Aneurysm Sac Dynamics Following Fenestrated Endovascular Aneurysm Repair After Previous Endovascular Aneurysm Repair

Titia A.L. Sulzer[1], Jorg L. de Bruin[1], Vinamr Rastogi[1], Gert Jan Boer[2], Thomas Mesnard[3], Bram Fioole[2], Marie Josee van Rijn[1], Marc L. Schermerhorn[4], Gustavo S. Oderich[3], Hence J.M. Verhagen[1]

[1] Department of Vascular Surgery, Erasmus University Medical Center, Rotterdam, the Netherlands.
[2] Department of Vascular Surgery, Maasstad Hospital Rotterdam, the Netherlands. Division of Vascular and Endovascular Surgery, Mayo Clinic, Rochester, MN.
[3] Department of Cardiothoracic & Vascular Surgery, Advanced Aortic Research Program at the University of Texas Health Science Center at Houston, McGovern Medical School, Houston, TX.
[4] Beth Israel Deaconess Medical Center, Harvard Medical School, Boston, MA.

This study was presented at the Dutch Vascular Society Meeting (Noordwijkerhout, the Netherlands, April 2023); The Young Surgeon Competition of the Vascular Annual Meeting of the Society for Vascular Surgery (National Harbor, MD, the United States, June 2023); and the Fast Track session of the European Society for Vascular Surgery Annual Meeting (Belfast, Northern Ireland, September 2023).

European Journal of Vascular and Endovascular Surgery, Volume 67, Issue 6, June 2024, pages 886-893
DOI: 10.1016/j.ejvs.2024.01.070

Abstract

Objective: Fenestrated endovascular aneurysm repair (FEVAR) represents a feasible option for aortic repair after EVAR, due to improved perioperative outcomes compared to open conversion. However, little is known regarding the durability of FEVAR as treatment of failed EVARs. Since aneurysm-sac evolution is an important marker for success after aneurysm repair, the aim of our study was to examine mid-term outcomes and aneurysm-sac dynamics of FEVAR after prior EVAR.

Methods: We included patients undergoing FEVAR for complex abdominal aortic aneurysms from 2008-2021 at two hospitals in the Netherlands. Patients were categorized into primary FEVAR and FEVAR after EVAR. Outcomes included five-year mortality, one-year aneurysm-sac dynamics (regression/stable/expansion), sac dynamics over time and five-year aortic-related procedures. Analyses were done using Kaplan-Meier methods, multivariable cox-regression analysis, Chi-square tests and linear mixed effect models.

Results: We identified 196 FEVAR patients of which 27% (N=53) had a prior EVAR. Patients with prior EVAR were significantly older (78 years [±6.7] vs. 73 years [±5.9], $p<.001$). There were no significant differences in mortality. FEVAR after EVAR was associated with higher risk of aortic-related procedures within 5 years (HR: 2.6; [95%CI: 1.1-6.5], $p=.037$). Sac dynamics were assessed in 154 patients with available imaging. Patients with a prior EVAR showed lower rates of sac regression and higher rates of sac expansion at one-year compared to primary FEVAR (sac expansion: (48% (N=21/44) vs. 8 % (N=9/110), $p<.001$)). Sac dynamics over time showed similar results, sac growth for FEVAR after EVAR and sac shrinkage for primary FEVAR ($p<.001$).

Conclusion: FEVAR after EVAR showed high rates of sac expansion and needed more secondary procedures than primary FEVAR patients, although this did not affect mid-term survival. Future studies will have to assess whether FEVAR after EVAR is a valid intervention, and the underlying process that drives aneurysm-sac growth following successful FEVAR after EVAR.

Introduction

In the last decade, endovascular aneurysm repair (EVAR) has become the preferred treatment for infrarenal abdominal aortic aneurysms (AAAs). Nevertheless, high rates of reintervention after EVAR remains a concern.[1, 2] Failure of sealing due to progression of disease causes the most complications over time, and can result in type 1 endoleaks and rupture.[3, 4] For that reason, an intervention to treat inadequate sealing is highly recommended. Fenestrated endovascular aneurysm repair (FEVAR) allows extension of the proximal sealing zone towards the visceral aortic segment, while providing blood flow to mesenteric and renal arteries.[5, 6] Additionally, FEVAR has been used to treat inadequate sealing after EVAR, due to better perioperative outcomes and lower mortality compared with open repair and conversion.[7-13]

In the literature, low perioperative morbidity and mortality rates are reported for FEVAR as salvation treatment for prior EVAR, despite the technical challenges of implantation due to the previous endograft.[12, 14] Moreover, low rates of mid-term aneurysm-related mortality are described.[8, 15-17] Still, there is a paucity of evidence in durability of FEVAR as a reintervention method.

This study sets out to investigate the durability of FEVAR after prior EVAR. We aimed to explore mid-term outcomes and aneurysm-sac dynamics of FEVAR after prior EVAR compared with primary FEVAR.

Methods

Design and population

All consecutive patients undergoing FEVAR between 2008 and 2021 at two large hospitals in the Netherlands (Erasmus University Medical Center, Rotterdam, and Maasstad Hospital Rotterdam) were included in this retrospective cohort study. Exclusion criteria were patients with previous thoracic endovascular aortic repair (TEVAR) or prior open AAA repair in their medical history (**Fig 1**). This study complies with the Declaration of Helsinki in research ethics and was approved by the institutional and ethical review board of both hospitals.[18]

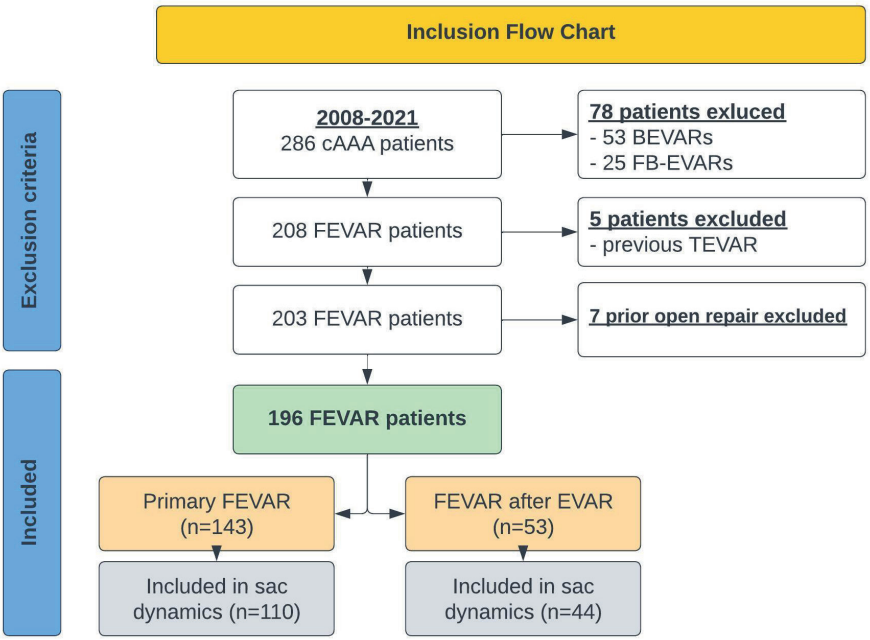

Fig 1. Inclusion flow chart for patients undergoing fenestrated endovascular aneurysm repair (FEVAR) and FEVAR after prior endovascular aneurysm repair (EVAR).

Data collection and definitions

To determine outcomes of patients with a FEVAR after a previous EVAR, we used a reference group, consisting of patients who underwent primary FEVAR. The two groups were assessed independently. Scallops were not included as fenestrations. Patient demographics, comorbidities medication, and aneurysm related mortality were reported according to the Society for Vascular Surgery reporting standards for complex abdominal aortic aneurysm repair.[19] The maximum perioperative aneurysm diameter was determined using computed tomography angiography (CTA) within 30 days of the surgery. For the aneurysm-sac dynamics, patients were required to have both 30-day CTA and one-year CTA to be included (to allow a grace period the CT image between 6-18 months was used). One-year CTAs were compared with 30-day CTAs for one-year aneurysm-sac dynamics, defined following: sac regression ≥5% volume decrease; stable sac <5% volume change; sac expansion ≥5% volume increase. For the aneurysm-sac dynamics over time, we used all available follow-up CTAs of the patients. All aneurysm-sac measurements were obtained using image-processing software (3-mensio Medical Imaging, Bilthoven, the Netherlands). Our group has previously validated a study on aneurysm volumes for both intra-and interobserver variability in infrarenal AAA.[20] The measurement protocol was made depending on the anatomical

variants of complex aneurysmal aortic disease to maximize detection of proportional aneurysm sac volume change over time. Our study included complex abdominal aortic aneurysms. The volumes were measured between 10 mm proximal to the upper-renal artery to 10 mm proximal to the aortic bifurcation.[21] The outcome 'five-year aortic-related procedures' included use of proximal cuff, limb extension, iliac percutaneous transluminal angioplasty (PTA), conversion to aorto-uni-iliac configuration (AUI), coiling, gluing, embolization, endoleak treatment, open or laparoscopic ligation of collateral, and other surgical intervention. Finally, the type of treatment for patients with prior EVAR was categorized as either total relining (fenestrated cuff and bifurcated graft), or solely a proximal fenestrated cuff. All were Custom-Made devices.

Study endpoints

The primary outcome was five-year mortality. Secondary outcomes included five-year aortic-related procedures, one-year aneurysm-sac dynamics and sac dynamics over time.

Statistical analysis

Categorical variables were presented as number (%) and were compared using Pearson's χ^2 test or Fisher's exact tests. Continuous variables were tested for normal distribution using Q-Q plots, histograms and Shapiro-Wilk test and presented as mean plus standard deviation (SD) if normally distributed. If not normally distributed, they were presented as median plus interquartile range (IQR). T-tests and Mann-Whitney U tests were used to test continuous variables based on their parametric or non-parametric nature.

For five-year mortality and five-year aortic-related procedures we used multivariable Cox-regression analyses and Kaplan-Meier. Furthermore, we adjusted for age, gender, and supraceliac sealing zone. To investigate the aneurysm-sac volume over time, two longitudinal mixed effects model were made for primary FEVAR and FEVAR after EVAR. In these models, time was entered as the independent variable and aneurysm volume as the dependent variable, assuming random intercepts and slopes to allow individual variation per patient (fixed: time + [time^2]; random: ~time). To compare the time-sensitivity of the models, we ran the models with and without different polynomial terms for time and calculated the difference in likelihood ratios.[22] To adjust for perioperative aneurysm diameter in one-year sac dynamics we used logistic regression. Confidence intervals (CI) of 95% were used, and statistical significance was defined as $p<.05$.

All statistical analyses were performed using RStudio (version 4.2.2. Foundation for Statistical Computing, Institute for Statistics and Mathematics, Vienna, Austria).

Results

Patient characteristics

A total of 196 patients treated with FEVAR between 2008 and 2021 were included, with a median follow-up time of 27 months (IQR, 12-54). Out of all, fifty-three patients had a prior EVAR in their medical history (27%) (female, 15% (N=8/54)), and hundred-forty-three patients underwent primary FEVAR (73%) (female, 20% (N=28/143)) (**Table 1**). Indications for FEVAR after EVAR were type 1a endoleaks, accounting for 80% of the cases, while 20% had a dilatation of the infrarenal aorta with virtually no proximal seal left. The median follow-up was 27 months [IQR, 13-55] for the primary FEVAR group and 26 months [IQR, 10-54] for the FEVAR after EVAR group. Patients in the prior EVAR group were significantly older (78 (±5.9) vs. 73 (±6.7), $p<.001$). The proportion of current smokers was lower in the FEVAR after prior EVAR group compared with the primary FEVAR group (11% (N=6/53) vs. 35% (N=50/143), $p=.002$). In the FEVAR after prior EVAR group, most patients were treated with four-fenestrations (47%, N=25/53), followed by three-fenestrations (42%, N=22/53), and two-fenestrations (11% N=6/53). In the primary FEVAR group, most patients were treated with three-fenestrations (45% N=65/143), followed by four-fenestrations (34% N=48/143), two-fenestrations (17% N=24/143), one-fenestration (4% N=5/143) and five-fenestrations (1% N=1/143). However, none of these differences in the number of fenestrations were found to be statistically significant. In the FEVAR after EVAR group, 36 patients underwent complete relining, while 17 patients received only a proximal cuff. Finally, the maximum perioperative aneurysm diameter was significantly larger in the FEVAR after prior EVAR group compared with the primary FEVAR group (67 mm (±10) vs. 62 mm (±10), $p=.003$). The median duration after failed EVAR to FEVAR intervention was 70 months [IQR, 47-98]. Further demographic information, comorbidities, medication, and anatomic characteristics are reported in **Table 1**.

Perioperative mortality

There were no cases of perioperative mortality in the FEVAR after EVAR group. However, five patients in the primary FEVAR group deceased within 30 days after surgery ($p=.48$) (**Table 2**).

Table 1. Baseline clinical, anatomical, and device-related variables for primary fenestrated endovascular aneurysm repair (FEVAR) and FEVAR after prior endovascular aneurysm repair (EVAR)

	Primary FEVAR (N=143)	Prior EVAR (N=53)	
	N (percent, SD)		*p*-value
Age (at surgery), years	73 ±6.7	78 ±5.9	**<.001**
Gender, female	28 (20)	8 (15)	.61
Cardiovascular risk factors			
Hypertension	112 (78)	47 (89)	.30
DM	20 (14)	10 (19)	.54
Current smoking	50 (35)	6 (11)	**.002**
PAOD	53 (37)	20 (38)	1
Myocardial infarct	43 (30)	18 (34)	.82
COPD	48 (34)	14 (26)	.42
Preoperative eGFR*			.088
eGFR >60 mL/min/1.73m^2	91 (64)	32 (60)	
eGFR 30-60 mL/min/1.73m^2	46 (32)	16 (30)	
eGFR <30 mL/min/1.73m^2	2 (1.4)	4 (7.5)	
ASA III or IV	87 (61)	43 (81)	**.012**
Medication			
Beta blockers	73 (51)	31 (58)	.53
Statins	117 (82)	46 (87)	.67
Antiplatelets	101 (71)	38 (72)	1
Anticoagulants	25 (17)	14 (26)	.25
Antihypertensives	103 (72)	42 (79)	.58
Device modality			**.042**
Cook	128 (90)	40 (75)	
Anaconda	12 (8.4)	11 (21)	
Other	3 (2.1)	2 (3.8)	
No. of fenestrations			.76
1	5 (3.5)	0 (0)	
2	24 (17)	6 (11)	
3	65 (45)	22 (42)	
4	48 (34)	25 (47)	
5	1 (0.7)	0 (0)	
Sealing zone			.22
Supraceliac	68 (48)	38 (72)	
Infraceliac	75 (52)	15 (28)	
Aneurysm type			.55
TAAA IV	8 (5.6)	1 (1.9)	
Supra/pararenal	8 (5.6)	3 (5.7)	
Juxtarenal	127 (89)	49 (92)	
Maximum perioperative aneurysm diameter, mm	62 ±10	67 ±10	**.003**

SD, standard deviation; *DM*, Diabetes Mellitus; *PAOD*, peripheral arterial occlusive disease; *COPD*, chronic obstructive pulmonary disease; *eGFR*, estimated glomerular filtration rate; *ASA*, American society of Anesthesiologists; *TAAA*, thoracoabdominal aortic aneurysm; Boldface entries indicate statistical significance. *Preoperative eGFR if available. Due to rounding, numbers may not add up.

Table 2. Specification of graft-related events and one-year sac dynamics following primary fenestrated endovascular aneurysm repair (FEVAR) and FEVAR after prior endovascular aneurysm repair (EVAR)

	Primary FEVAR (N=143)	FEVAR after EVAR (N=53)
	N (percent, IQR)	
Median follow-up (months)	27 [13, 55]	26 [10, 54]
Perioperative mortality (%)	5 (3.5)	0
Aneurysm related mortality (%)	6 (4.2)	0
Graft-related events, No. of patients (%)	25 (18)	13 (25)
Proximal graft-related events	4 (2.8)	2 (3.8)
Type 1a endoleaks	2 (1.4)	2 (3.8)
Migration	0	0
Proximal cuff	2 (1.4)	0
Bridging stent-related events	22 (15)	15 (28)
Type 3a endoleaks	8 (5.6)	7 (13)
Visceral PTA	3 (2.1)	4 (7.5)
Visceral occlusion	4 (2.8)	2 (3.8)
Visceral restenting	7 (4.9)	2 (3.8)
Distal graft-related events	4 (2.8)	5 (9.4)
Type 1b endoleaks	1 (0.7)	1 (1.9)
Distal extension	3 (2.1)	4 (7.5)
Type 2 endoleaks	20 (14)	10 (19)
Conservative management	16 (11)	9 (17)
Coiling/gluing/embolization	4 (2.8)	0
Open/laparoscopic ligation of collaterals	0	1 (1.9)
One-year sac dynamics*	Primary FEVAR (N=110)	FEVAR after EVAR (N=44)
Sac regression (≥5% volume decrease)	85 (77)	10 (23)
Stable sac (<5% volume change)	16 (15)	13 (29)
Sac expansion (≥5% volume increase)	9 (8.2)	21 (48)

IQR, interquartile range; *PTA*, percutaneous transluminal angioplasty. *p-value <.001.
Due to rounding, numbers may not add up.
*Patients included for aneurysm-sac dynamics were required to have both a 30-day CTA and one-year CTA to be included.

Five-year mortality

After risk-adjusted analysis there were no significant differences in five-year mortality between the groups (Hazard Ratio (HR): 0.7; [95%CI: 0.3-1.5], p=.328) (**Fig 2**).

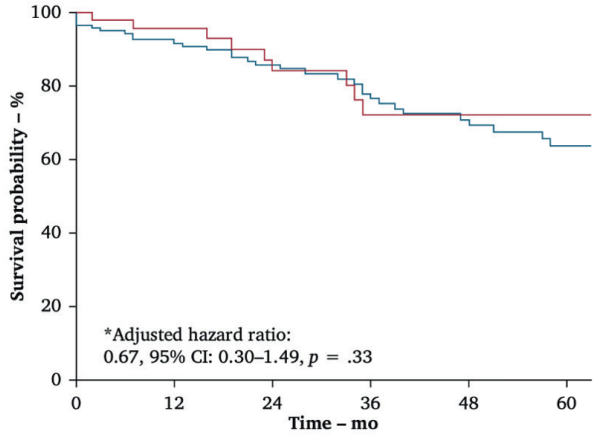

No. at risk						
Primary FEVAR	143	108	78	56	45	33
Kaplan–Meier estimate survival rates – %	100	91.7	85.7	76.6	69.2	63.6
Standard error – %	0	2.4	3.3	4.4	5.1	5.6
Prior EVAR	53	39	28	18	14	13
Kaplan–Meier estimate survival rates – %	100	95.6	84.0	72.2	72.2	72.2
Standard error – %	0	3.1	6.1	8.2	8.2	8.2

Fig 2. Cumulative Kaplan-Meier estimate of five-year mortality rate following primary fenestrated endovascular aneurysm repair (FEVAR) and FEVAR after prior endovascular aneurysm repair (EVAR). *CI*, confidence interval. *Adjusted for prior EVAR vs. primary FEVAR, sex (male/female), age at surgery, and supraceliac sealing vs. infraceliac sealing zone.

One-year aneurysm-sac dynamics

One-year sac regression, expansion, and stability data are presented in **Table 2**. Our analysis included 78% (N=154/196) of all the patients. Patients who underwent prior EVAR had a considerably lower rate of sac regression at one-year when compared to those who had primary FEVAR (23% (N=10/44) vs. 77% (N=85/110), $p<.001$). In fact, the prior EVAR group showed higher rates of sac expansion than the primary FEVAR group (48% (N=21/44) vs. 8% (N=9/110), $p<.001$). After adjusting for perioperative aneurysm diameter, patients with prior EVAR had a significantly lower odds of sac regression, with an odds ratio of 0.01 (95% CI: 0.1-0.3, $p<.001$). In **Supplemental Table 1**, an overview of patients who underwent FEVAR after EVAR is showing that those who received total relining and those who received only a proximal fenestrated cuff, show similar results of sax expansion after one-year, moreover not statistically significant (48% (N=14/29) vs. 47% (N=7/15), $p=.89$).

Five-year aortic-related procedures

After risk-adjusted analysis, prior EVAR was associated with a higher risk of developing aortic-related procedures within five years (HR: 2.6; [95% CI: 1.1-6.5], $p=.037$) (**Fig 3**).

For FEVAR after prior EVAR and primary FEVAR, most five-year aortic-related procedures were related to bridging stent events (28% (N=15/53) and 15% (N=22/143)) and type 2 endoleaks (19% (N=10/53) and 14% (N=20/143)). More details on graft-related complications and procedures are demonstrated in **Table 2**.

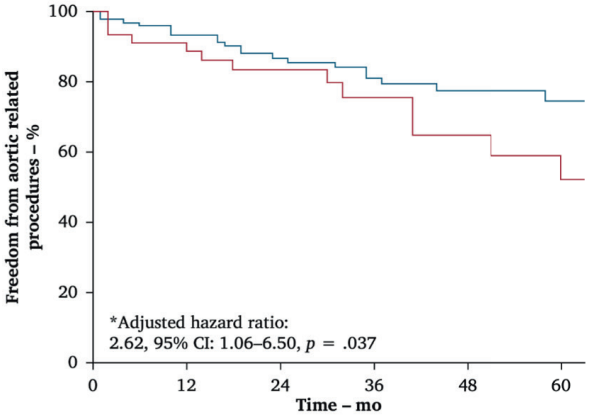

No. at risk						
Primary FEVAR	143	103	71	50	38	25
Kaplan–Meier estimate re-intervention rates – %	100	93.4	86.9	81.1	77.5	74.6
Standard error – %	0	2.3	3.3	4.2	4.7	5.3
Prior EVAR	53	37	25	15	11	9
Kaplan–Meier estimate re-intervention rates – %	100	88.9	83.6	75.6	64.8	52.4
Standard error – %	0	4.7	5.7	7.2	9.5	11.0

Fig 3. Cumulative Kaplan-Meier estimate of five-year secondary aortic related procedures for primary fenestrated endovascular aneurysm repair (FEVAR) and FEVAR after prior endovascular aneurysm repair (EVAR). *CI*, confidence interval. *Adjusted for prior EVAR vs. primary FEVAR, sex (male/female), age at surgery, and supraceliac sealing zone vs. infraceliac sealing zone.

Aneurysm-sac dynamics over time

In **Fig 4**, the longitudinal mixed effect models show aneurysm-sac volumes since the moment of FEVAR as function of time (in months), for both the FEVAR after EVAR group and the primary FEVAR group. Our model demonstrates that FEVAR after EVAR was associated with an increased aneurysm-sac volume over time, where primary FEVAR was associated with a decreased aneurysm-sac volume ($p<.001$). The occurrence of endoleaks did not differ significantly between the FEVAR after EVAR group and the primary FEVAR group. Details are shown in **Table 2**.

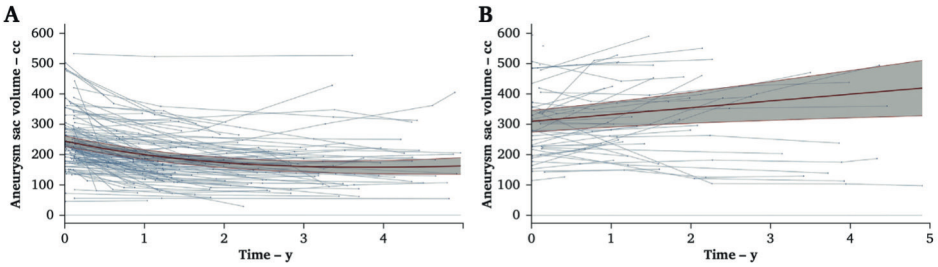

Fig 4. Linear mixed effects models for aneurysm sac-dynamics following **(A)** primary fenestrated endovascular aneurysm repair (FEVAR) and **(B)** FEVAR after prior endovascular aneurysm repair (EVAR). $p<.001$ between panels A and B.

Discussion

The aim of the present study was to examine durability of FEVAR as rescue treatment for failure after EVAR. We found that the risk of five-year mortality was similar between the two groups (HR: 0.7; [95% CI: 0.3-1.5], $p=.328$). Furthermore, FEVAR after EVAR had lower rates of sac regression at one-year compared with primary FEVAR (23% (N=10/44) vs. 77% (N=85/110) and higher rates of sac expansion (48% (N=21/44) vs. 8% (N=9/110). The same trend was observed in our linear mixed effect models, where patients treated with FEVAR after prior EVAR showed an increase in aneurysm-sac volume over time, and patients treated with primary FEVAR showed a decrease in aneurysm-sac volume over time. Finally, FEVAR after EVAR was associated with a higher risk of aortic-related procedures after five years (HR: 2.6; [95% CI: 1.1-6.5], $p=.037$).

The five-year mortality rates were comparable between patients who underwent FEVAR after EVAR and those who underwent primary FEVAR. It is worth noting that we corrected for the age at surgery, as patients with prior EVAR were approximately five years older than patients with primary EVAR. These results are surprising because patients with FEVAR after EVAR showed higher rates of aortic-related procedures. Thus, it appears that in our study, aortic-related procedures over a five-year period do not necessarily have an impact on survival. This finding is consistent with the study of Zetterval and colleagues, in which patients who underwent aortic-related procedures following FB-EVAR showed improved long-term survival.[23] It is likely that patients who underwent aortic-related-procedures have lower mortality, because the interventions are performed in response to certain complications (e.g. endoleaks, stent migration), which can lead to higher mortality if left untreated.

In the literature, low rates of perioperative mortality were reported for FEVAR after prior EVAR.[12, 14] In our study, there were no cases of perioperative mortality in the FEVAR after

EVAR group. However, five patients with primary FEVAR deceased within 30 days after surgery. It is relevant to highlight that our study included patients treated from 2008 to 2021, and the cases of perioperative mortality occurred in the earlier years when FEVAR was a novel procedure in our hospitals. The operator experience could be a contributing factor to the higher perioperative mortality rates observed in the primary FEVAR group and potentially conceal survival differences compared with FEVAR after EVAR.

Patients treated with FEVAR after EVAR showed significantly less sac regression after one-year, and higher rates of sac expansion in comparison with primary FEVAR. To account for the potential confounding effect of perioperative aneurysm diameter, which was larger in patients with prior EVAR, we included it as a covariate in our logistic regression model, as larger aneurysm-sacs could have a lower rate of sac regression at one-year. Despite this adjustment, the results remained significant. We stratified one-year sac dynamics for patients who had undergone FEVAR after EVAR using two different techniques: total relining and the use of a fenestrated proximal cuff only. Our findings seem to indicate that total relining was associated with similar rates of sac expansion compared to the fenestrated cuff, moreover the differences were not statistically significant. Conceptually, it seems to make more sense to advocate total relining in patients with failed EVAR as other, usually undetectable, potential causes for sac growth like graft porosity, graft sweating or small stich holes bleeding are treated simultaneously. However, our data does not proof this hypothesis. There is a lack of literature on the durability of either total relining or fenestrated cuffs, and our results are indicating the need for more research on this topic.

Similar to the one-year sac dynamics, we found an increase of aneurysm-sac volume over time in patients treated with FEVAR after EVAR. Recent evidence has shown that after EVAR, not only sac expansion but any failure of the sac to regress is associated with higher long-term mortality, and higher risk of long-term reinterventions.[24, 25] A more recent study suggest that non-regression at one-year imaging is associated with higher risk of five-year all-cause mortality and graft related events after FB-EVAR.[21] For that reason, it may be assumed that FEVAR after EVAR is a less durable treatment. Nonetheless, the limited availability of literature on aneurysm-sac regression after FEVAR for complex abdominal aortic aneurysms emphasizes the significance of our findings. In low-risk patients, explantation of the graft can be considered, however this is associated with higher mortality in older high-risk patients.[16] Therefore, such patients might benefit from relining with FEVAR. Whether this holds true in longer-term, follow-up remains to be elucidated, especially while half of the aneurysm sacs keep growing.

It is important to mention that the failure of the aneurysm-sac to regress in the prior EVAR group could be attributed to the presence of type 2 endoleaks (19%, N=10/53) in this group. Although it is unlikely to be the sole reason, as their presence was not higher than in the primary FEVAR group, nor is it known why patients with prior EVAR would develop more frequent or severe type 2 endoleaks compared to patients with primary FEVAR. Primary FEVAR treatment, however, is showing good results and high rates of aneurysm-sac regression both after one-year and over time, despite presence of type 2 endoleaks in 14% (N=20/143) of the patients, indicating successful aneurysm-sac exclusion. Furthermore, treating type 2 endoleaks to stop aneurysm-sac growth after EVAR has shown to be highly ineffective with 93% of patients showing continuous sac growth after so called successful treatment.[26] Ultimately, there may be other underlying reasons for non-sac regression after infrarenal EVAR, such as unknown familial or genetically triggered aneurysm disease or unknown biological processes, which is an important subject for further research.

In addition, we found a higher risk of five-year aortic-related procedures for patients treated for FEVAR after prior EVAR, this is in line with the results of Hostalrich et al. and Martin et al. where respectively 33% and 37% of patients treated with fenestrated and branched endovascular aneurysm repair (FB-EVAR) for a failed EVAR showed secondary aortic-related reinterventions.[10, 27] The five-year aortic-related procedures in our study were mostly related to bridging stent events and type 2 endoleaks. Specifically, the occurrence of type 3a endoleaks was more prevalent in patients with FEVAR after EVAR. Potentially because of placement of proximal cuffs in these patients, as it can be hypothesized that the stent graft did not completely conform to the previous EVAR in the distal region, leading to blood flow between the two components. As mentioned above, further studies need to evaluate the durability of proximal cuffs and total relining. Conversely, Hostalrich and colleagues reported predominantly stent-related events and distal graft-related secondary procedures.[10] A study by Schanzer and colleagues showed that after one-year, patients who underwent FB-EVAR after previous EVAR, had slightly lower freedom from reintervention compared to those who had primary FB-EVAR (83% vs. 87%; p=.09), even though the technical success rates were similar.[11] Given our prolonged follow-up period, it is plausible that reinterventions for prior EVAR patients may occur later during the follow-up. Patients who had prior EVAR may have comorbidities or other risk factors that increase the likelihood of complications and reinterventions. A clinical implication could be to conduct more thorough monitoring of patients with failed EVAR during follow-up to prevent the need for reintervention. Our low rates of type 1a endoleaks indicate that FEVAR after EVAR patients experience

sac growth along with satisfactory sealing. We intend to conduct future research to investigate the long-term outcomes and durability within this study population.

The decision to perform direct FEVAR for infrarenal aneurysms as a more durable treatment is a topic of discussion, as sac regression after infrarenal EVAR occurs in only 50%.[24] FEVAR could probably be suggested for patients who have a marginal proximal sealing zone and a large aneurysm diameter. Although EVAR would be a feasible option in these cases, there is a higher chance of failure over time.[28, 29] Performing FEVAR after failed EVAR can be technically challenging, which may be another reason to treat patients with FEVAR directly. However, immediate FEVAR treatment for infrarenal aneurysms does come with potential disadvantages, including technical complexity, higher costs, longer procedure times leading to increased radiation exposure, and logistically problems. The decision of whether to use FEVAR or EVAR should be evaluated on an individual basis.

Our study has certain limitations that should be considered. Firstly, its retrospective nature and the fact that our study only included patients with at least one-year of CTA follow-up for aneurysm-sac dynamic, potentially resulting in selection bias as patients with early mortality were not captured. When interpreting our results, it is important to consider that we allowed for a grace period of 6-18 months for the one-year CTA-scan. Another aspect related to selection bias pertains to the comparison between patients who underwent FEVAR for failed EVAR and those who had primary FEVAR, as there were probably underlying factors in the prior EVAR group that led to adverse outcomes, e.g. type 3 endoleaks (stich hole bleedings) or type 1 endoleaks (either static or dynamic) not visible as endoleaks on CTA imaging. On average, patients in the FEVAR after EVAR group were five years older and had similar mortality outcomes, indicating a strict selection among these patients. However, this suggests a potential selection bias, although it also reflects a real-life cohort of patients.

Given that both hospitals involved in this study functioned as referral centers, we encountered limitations in accessing original pre-EVAR anatomical data for many patients. Additionally, the relatively small sample size, especially in the FEVAR after EVAR group, may have resulted in type 2 errors within our study.

Conclusion

Despite successful proximal extension and relining, FEVAR after EVAR patients had higher rates of aneurysm sac expansion and needed more secondary procedures than

primary FEVAR patients. However, this did not seem to affect five-year survival. Future studies will have to assess whether FEVAR after EVAR is a durable intervention following failed infrarenal EVAR, and if a fenestrated cuff needs to be completed with total relining of the EVAR graft. Furthermore, the underlying process that drives aneurysm-sac growth following FEVAR after EVAR needs further clarification.

References

1. Li B, Khan S, Salata K, Hussain MA, de Mestral C, Greco E, et al. A systematic review and meta-analysis of the long-term outcomes of endovascular versus open repair of abdominal aortic aneurysm. J Vasc Surg. 2019;70:954-69 e30.
2. Patel R, Sweeting MJ, Powell JT, Greenhalgh RM, investigators Et. Endovascular versus open repair of abdominal aortic aneurysm in 15-years' follow-up of the UK endovascular aneurysm repair trial 1 (EVAR trial 1): a randomised controlled trial. Lancet. 2016;388:2366-74.
3. Patel SR, Allen C, Grima MJ, Brownrigg JRW, Patterson BO, Holt PJE, et al. A Systematic Review of Predictors of Reintervention After EVAR: Guidance for Risk-Stratified Surveillance. Vasc Endovascular Surg. 2017;51:417-28.
4. Schermerhorn ML, Buck DB, O'Malley AJ, Curran T, McCallum JC, Darling J, et al. Long-Term Outcomes of Abdominal Aortic Aneurysm in the Medicare Population. N Engl J Med. 2015;373:328-38.
5. Verhoeven EL, Prins TR, Tielliu IF, van den Dungen JJ, Zeebregts CJ, Hulsebos RG, et al. Treatment of short-necked infrarenal aortic aneurysms with fenestrated stent-grafts: short-term results. Eur J Vasc Endovasc Surg. 2004;27:477-83.
6. Greenberg RK, Sternbergh WC, 3rd, Makaroun M, Ohki T, Chuter T, Bharadwaj P, et al. Intermediate results of a United States multicenter trial of fenestrated endograft repair for juxtarenal abdominal aortic aneurysms. J Vasc Surg. 2009;50:730-7 e1.
7. Vourliotakis G, Bos WT, Beck AW, Van Den Dungen JJ, Prins TR, Verhoeven EL. Fenestrated stent-grafting after previous endovascular abdominal aortic aneurysm repair. J Cardiovasc Surg (Torino). 2010;51:383-9.
8. Katsargyris A, Yazar O, Oikonomou K, Bekkema F, Tielliu I, Verhoeven EL. Fenestrated stent-grafts for salvage of prior endovascular abdominal aortic aneurysm repair. Eur J Vasc Endovasc Surg. 2013;46:49-56.
9. Manunga J, Stanberry LI, Alden P, Alexander J, Skeik N, Stephenson E, et al. Technical approach and outcomes of failed infrarenal endovascular aneurysm repairs rescued with fenestrated and branched endografts. CVIR Endovasc. 2019;2:34.
10. Hostalrich A, Mesnard T, Soler R, Girardet P, Kaladji A, Jean Baptiste E, et al. Prospective Multicentre Cohort Study of Fenestrated and Branched Endografts After Failed Endovascular Infrarenal Aortic Aneurysm Repair with Type Ia Endoleak. Eur J Vasc Endovasc Surg. 2021;62:540-8.
11. Schanzer A, Beck AW, Eagleton M, Farber MA, Oderich G, Schneider D, et al. Results of fenestrated and branched endovascular aortic aneurysm repair after failed infrarenal endovascular aortic aneurysm repair. J Vasc Surg. 2020;72:849-58.
12. Gallitto E, Gargiulo M, Freyrie A, Bianchini Massoni C, Mascoli C, Pini R, et al. Fenestrated and Branched Endograft after Previous Aortic Repair. Ann Vasc Surg. 2016;32:119-27.
13. Makaloski V, Tsilimparis N, Panuccio G, Spanos K, Wyss TR, Rohlffs F, et al. Perioperative Outcome of Fenestrated and Branched Stent Grafting after Previous Open or Endovascular Abdominal Aortic Repair. Ann Vasc Surg. 2021;74:229-36.
14. Juszczak M, Vezzosi M, Nasr H, Claridge M, Adam DJ. Fenestrated-Branch Endovascular Repair After Prior Abdominal Aortic Aneurysm Repair. Eur J Vasc Endovasc Surg. 2021;62:728-37.
15. Adam DJ, Fitridge RA, Berce M, Hartley DE, Anderson JL. Salvage of failed prior endovascular abdominal aortic aneurysm repair with fenestrated endovascular stent grafts. J Vasc Surg. 2006;44:1341-4.
16. Doumenc B, Mesnard T, Patterson BO, Azzaoui R, De Preville A, Haulon S, et al. Management of Type IA Endoleak After EVAR by Explantation or Custom Made Fenestrated Endovascular Aortic Aneurysm Repair. Eur J Vasc Endovasc Surg. 2021;61:571-8.
17. Dias AP, Farivar BS, Steenberge SP, Brier C, Kuramochi Y, Lyden SP, et al. Management of failed endovascular aortic aneurysm repair with explantation or fenestrated-branched endovascular aortic aneurysm repair. J Vasc Surg. 2018;68:1676-87 e3.
18. World Medical A. World Medical Association Declaration of Helsinki: ethical principles for medical research involving human subjects. JAMA. 2013;310:2191-4.
19. Oderich GS, Forbes TL, Chaer R, Davies MG, Lindsay TF, Mastracci T, et al. Reporting standards for endovascular aortic repair of aneurysms involving the renal-mesenteric arteries. J Vasc Surg. 2021;73:4S-52S.

20. Bastos Goncalves F, van de Luijtgaarden KM, Hoeks SE, Hendriks JM, ten Raa S, Rouwet EV, et al. Adequate seal and no endoleak on the first postoperative computed tomography angiography as criteria for no additional imaging up to 5 years after endovascular aneurysm repair. J Vasc Surg. 2013;57:1503-11.
21. Rastogi V, Sulzer TAL, de Bruin JL, Oliveira-Pinto J, Alberga AJ, Hoeks SE, et al. Aneurysm Sac Dynamics and its Prognostic Significance Following Fenestrated and Branched Endovascular Aortic Aneurysm Repair. Eur J Vasc Endovasc Surg. 2023.
22. Laird NM, Ware JH. Random-effects models for longitudinal data. Biometrics. 1982;38:963-74.
23. Zettervall SL, Tenorio ER, Schanzer A, Oderich GS, Timaran CH, Schneider DB, et al. Secondary interventions after fenestrated/branched aneurysm repairs are common and nondetrimental to long-term survival. J Vasc Surg. 2022;75:1530-8 e4.
24. Bastos Goncalves F, Baderkhan H, Verhagen HJ, Wanhainen A, Bjorck M, Stolker RJ, et al. Early sac shrinkage predicts a low risk of late complications after endovascular aortic aneurysm repair. Br J Surg. 2014;101:802-10.
25. O'Donnell TFX, Deery SE, Boitano LT, Siracuse JJ, Schermerhorn ML, Scali ST, et al. Aneurysm sac failure to regress after endovascular aneurysm repair is associated with lower long-term survival. J Vasc Surg. 2019;69:414-22.
26. Mulay S, Geraedts ACM, Koelemay MJW, Balm R, group Os. Type 2 Endoleak With or Without Intervention and Survival After Endovascular Aneurysm Repair. Eur J Vasc Endovasc Surg. 2021;61:779-86.
27. Martin Z, Greenberg RK, Mastracci TM, Eagleton MJ, O'Callaghan A, Bena J. Late rescue of proximal endograft failure using fenestrated and branched devices. J Vasc Surg. 2014;59:1479-87.
28. Rastogi V, de Bruin JL, Varkevisser RRB, Oliveira NFG, Bouwens E, Hoeks SE, et al. Proximal seal dilatation following fenestrated endovascular repair for complex abdominal aortic aneurysms. J Vasc Surg. 2022;75:1521-9 e1.
29. Oliveira NFG, Oliveira-Pinto J, van Rijn MJ, Baart S, Raa ST, Hoeks SE, et al. Risk Factors, Dynamics, and Clinical Consequences of Aortic Neck Dilatation after Standard Endovascular Aneurysm Repair. Eur J Vasc Endovasc Surg. 2021;62:26-35.

Supplemental Material

Supplemental Table 1. Specification of patients with FEVAR after EVAR with total relining (fenestrated cuff and bifurcated graft with or without inverted limb) versus patients with solely a proximal fenestrated cuff

	Total relining (N=36)	Fenestrated cuff (N=17)	
Bifurcated with inverted limb (%)	27 (75)	NA	
One-year sac dynamics*	(N=29)	(N=15)	*p*=.89
Sac regression (%)	6 (21)	4 (26.5)	
Stable sac (%)	9 (31)	4 (26.5)	
Sac expansion (%)	14 (48)	7 (47)	

* Patients included for aneurysm-sac dynamics were required to have both a 30-day CTA and one-year CTA to be included.

Part III

Duplex Ultrasound Surveillance After Complex Aortic Aneurysm Repair



Chapter 8

Changes in Renal-Mesenteric Duplex Ultrasound Velocities After Fenestrated and Branched Endovascular Aortic Aneurysm Repair

Titia A.L. Sulzer[1,4], Thanila A. Macedo[1], Nicole Strissel[2], Gina K. Hesley[2], Alexander Lekah[2], Tiziano Tallarita[3], Marina Dias-Neto[1], Ying Huang[1], Emanuel R. Tenorio[1], Andrea Vacirca[1], Thomas Mesnard[1], Aidin Baghbani-Oskouei[1], Safa Savadi[1], Jorg L. de Bruin[4], Hence J.M. Verhagen[4], Bernardo Mendes[5], Gustavo S. Oderich[1]

[1] Department of Cardiothoracic & Vascular Surgery, Advanced Aortic Research Program at the University of Texas Health Science Center at Houston, McGovern Medical School, Houston, TX.
[2] Department of Radiology, Mayo Clinic, Rochester, MN.
[3] Department of Vascular Surgery, Mayo Clinic, Eau Claire, WI.
[4] Department of Vascular Surgery, Erasmus University Medical Center, Rotterdam, the Netherlands.
[5] Department of Vascular and Endovascular Surgery, Mayo Clinic, Rochester, MN.

Journal of Vascular Surgery, Volume 78, Issue 5,
November 2023, pages 1162-1169
DOI: 10.1016/j.jvs.2023.06.106.

Abstract

Objective: Stenting of renal and mesenteric vessels may result in changes in velocity measurements due to arterial compliance, potentially giving rise to confusion about presence of stenosis during follow-up. The aim of our study was to compare preoperative and postoperative changes in peak systolic velocity (PSV, cm/sec) following placement of the celiac axis (CA), superior mesenteric artery (SMA) and renal artery (RAs) bridging stent-grafts during fenestrated-branched endovascular aortic repair (FB-EVAR) for treatment of complex abdominal aortic aneurysms (cAAAs) and thoracoabdominal aortic aneurysms (TAAAs).

Methods: Patients were enrolled in a prospective, non-randomized single-center study to evaluate FB-EVAR for treatment of CAAAs and TAAAs between 2013-2020. Duplex ultrasound (DUS) of renal-mesenteric vessels were obtained prospectively preoperatively and at 6-8 weeks following the procedure. DUS was performed by a single vascular laboratory team using a pre-defined protocol including PSV measurements obtained with <60° angles. All renal-mesenteric vessels incorporated by bridging stent-grafts using fenestrations or directional branches were analyzed. Target vessels with significant stenosis in the preoperative exam were excluded from the analysis. The endpoint was variations in PSV post-stent placement at the origin, proximal and mid segments of the target vessels for fenestrations and branches.

Results: There were 419 patients (292 male, mean age 74±8 years old) treated by FB-EVAR with 1,411 renal-mesenteric targeted vessels, including 260 CAs, 409 SMAs and 742 RAs. No significant variances in the mean PSVs of all segments of the CA, SMA and RAs at 6-8 weeks after surgery were found as compared to the preoperative values (CA: 135 cm/sec vs. 141 cm/sec, p=.056; SMA: 128 cm/sec vs. 125 cm/sec, p=.624; RAs: 90 cm/sec vs. 83 cm/sec, p=.654). Compared with baseline preoperative values, the PSV of the targeted vessels showed no significant difference in the origin and proximal segment of all vessels. However, PSV significantly increased in the mid segment of all target vessels following stent placement.

Conclusion: Stent placement in nonstenotic renal and mesenteric vessels during FB-EVAR is not associated with significant increase in PSVs at the origin and proximal segments of the target vessels. While there is a modest but significant increase in velocity measurements in the mid segment of the stented vessel, this is not clinically significant. Furthermore, PSVs in stented renal and mesenteric arteries were well below the threshold for significant stenosis in native vessels. These values provide a baseline or benchmark for expected PSVs following renal-mesenteric stenting during FB-EVAR.

Introduction

Endovascular aortic aneurysm repair (EVAR) has become the primary method of treatment of abdominal aortic aneurysms (AAA) worldwide. Fenestrated and branched endovascular aortic aneurysm repair (FB-EVAR) allowed the expansion of endovascular techniques to treat complex abdominal aortic aneurysms (cAAAs) and thoracoabdominal aortic aneurysms (TAAAs) with durable outcomes.[1-3] These procedures require incorporation of the renal and mesenteric vessels with placement of stents. Lifelong surveillance is required to detect complications, and prompt secondary interventions.[4, 5] Although computed tomographic angiography (CTA) remains the cornerstone for surveillance after FB-EVAR, duplex ultrasound (DUS) is a valuable, non-invasive imaging modality which provides complementary information to identify hemodynamic changes in stents most frequently associated with significant stenosis.[6, 7] This is especially helpful in small stented vessels, where metallic artifact limits accurate CTA evaluation.

Ultrasound is a desirable modality because of low cost, wide availability, no need for iodinated contrast and absence of ionizing radiation.[8] On the other hand, it is operator dependent and dependent on experience. DUS examination after FB-EVAR involves detailed assessment of the stented renal and mesenteric target vessels. The examination requires qualified sonographers, preferentially trained in vascular imaging to maximize success and accuracy of results. Although the ability to detect vessel stenosis or occlusion is a valuable advantage of DUS, morphologic complications such as migration and stent fracture remains a limitation of current ultrasound techniques.[8, 9] Velocity criteria for detection of renal and mesenteric arterial stenosis has been defined for native vessels but not for stented vessels.[10, 11] Some authors believe that velocity criteria for in-stent stenosis should be higher due to decreased vessel wall compliance, flow turbulence and shear stress following stent placement, but the extent of expected changes, if any, is not well defined and confounded by the underlying obstructive disease.[6, 12-14] Patients treated by FB-EVAR, present an optimal group to study changes isolated to stent placement. The expected changes in PSV of renal and mesenteric arteries have not been reported. The aim of this study was to describe patterns of velocity changes associated with the implantation of bridging stent-grafts after FB-EVAR.

Methods

Study design and population

This study involved a prospective non-randomized physician-sponsored investigational device exemption protocol (Clinical Trial number: NCT02089607) to evaluate patients undergoing FB-EVAR between October 2013 and May 2020. The study was approved by the Institutional Review Board and all patients signed informed consent. DUS of renal-mesenteric vessels was obtained prospectively prior to the procedure, at 6-8 weeks after the procedure, six months, one-year and yearly thereafter for the first five years. The examinations were all performed in a single ultrasound laboratory by registered vascular technicians (RVT) using standardized protocols (**Supplemental Table 1**). We analyzed all renal and mesenteric target vessels before and after stent placement by reinforced fenestration or directional branch. Vessels with significant stenosis defined preoperatively by DUS using established criteria for >60% stenosis in the renal arteries (RAs) (200 cm/s) and >70% stenosis in the celiac axis (CA) and superior mesenteric artery (SMA) (200 and 275 cm/s respectively) were excluded from the analysis.[10, 11, 15] Patient demographics, comorbidities, cardiovascular risk factors, medication status, aortic history, procedural outcomes, anatomic and device characteristics were collected in case report forms and entered in an electronic database. Definitions were based on the Society for Vascular Surgery (SVS) reporting standards for endovascular repair of aneurysms involving the renal and mesenteric arteries.[16]

Endovascular technique

The stent graft design was left at the discretion of the principal investigator and was based on target vessel anatomical features including the extent of the aneurysm, inner aortic luminal diameter and vessel orientation. Patients received either a patient-specific stent-graft with any combination of reinforced fenestrations and/or directional branches or an off-the-shelf multi-branch stent-graft manufactured by Cook Medical (Bloomington, IN, USA) (**Fig 1**). Bridging stent diameter, length and type were selected preoperatively by the treating operator. Fenestrations were aligned with balloon-expandable covered stents and branches with either balloon-expandable covered stent or self-expandable covered stents depending on anatomical considerations and operators' preferences. The procedural steps of FB-EVAR have been described in detail elsewhere.[17] Postoperatively, patients were immediately continued on aspirin and Clopidogrel was started two weeks after surgery.

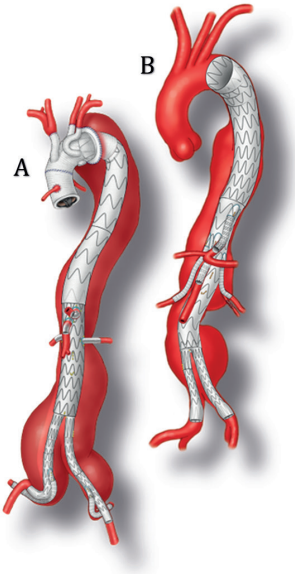

Fig 1. (A) A fenestrated stent grafts. **(B)** Branched stent graft.

Duplex ultrasound protocol

DUS was performed using pre-defined protocols prospectively and included peak systolic velocity (PSV, cm/sec) measurements obtained with <60° angles at the origin, proximal, mid and distal segments of the CA, SMA and RAs (**Supplemental Table 1**). DUS scans were performed using a GE E9 scanner by experienced vascular sonographers. Prior to the examination, patients were asked to fast for 4-6 hours to minimize bowel gas. The preoperative CTA and surgical procedure notes were reviewed and when available post procedure CTA was also reviewed prior to ultrasound examination. Most often, images were obtained with the patient in supine position or lateral oblique when necessary. The CI-5 curved transducer was most frequently used (**Supplemental Fig 1**). The Doppler angle of insonation was invariably less than 60°, and preferably 50° or less.

Study endpoints and statistical analysis

The endpoint was to assess changes in PSV (cm/sec) for each segment (origin, proximal and mid) measured prior and after stenting of the CA, SMA and RAs in patients who underwent FB-EVAR. For the demographics, baseline comorbidities, anatomic and device characteristics we used descriptive statistics (mean and standard deviation). Furthermore, target vessels were evaluated independently. We performed subanalyses to differentiate the variances in PSV for reinforced fenestrations and directional branches at 6-8 weeks. Additionally, we compared balloon expandable stents to self-expandable

stents for the target vessels incorporated by directional branches. It is worth noting that all fenestrated vessels used balloon-expandable stents. The continuous PSV variables were tested for normal distribution using histograms, Q-Q plots and Shapiro-Wilk test and presented as mean ± standard deviation (SD). Paired T-tests were used to test the continuous variables. A *p*-value of less than .05 was considered statistically significant. The data analysis was performed using R version 4.0.3 (http://www.r-project.org).

Results

Patient characteristics

There were 419 patients (292 male, mean age 74±8 years) enrolled in the study and treated by FB-EVAR from October 2013 to May 2020. A significant stenosis was identified in 161 targeted vessels preoperatively and were excluded from the study to eliminate confounding factors in the evaluation of velocity changes related to stent placement. The remaining 1,411 targeted vessels (260 CAs, 409 SMAs, and 742 RAs) were deemed widely patent without stenosis and were included in our analysis. A total of 220 vessels (13%) were not able to be visualized with DUS due to technique limitations, including body habitus and overlying bowel gas. Among these vessels, 100 were preoperative, and 120 were postoperative. The most challenging vessel to visualize was the celiac artery, accounting for 42 vessels (42%) preoperatively, and 62 vessels (52%) post-operatively, largely explained by their deep location in the upper abdomen and/or presence of overlying bowel gas. Most patients were treated for a thoracoabdominal aortic aneurysm with Crawford extent IV in 313 patients (31%). The mean number of renal-mesenteric vessels targeted per patient was 3.9±0.5. Demographic information, baseline comorbidities, and anatomic details are listed in **Table 1**.

DUS findings

Compared to the preoperative values, the PSV of the target vessels showed no significant differences in the origin and proximal segment when all vessels were considered. However, the mid segment of all target vessels showed a significant increase in PSV compared to preoperative measurements (**Table 2**). **Fig 2** illustrates increase in PSV in the mid segments of the CA, SMA and RAs 6-8 weeks after FB-EVAR. Furthermore, no significant variances in the mean PSVs of all segments of the CA, SMA and RAs at 6-8 weeks after surgery were found as compared to the preoperative values (CA: 135 cm/sec vs. 141 cm/sec, p=.056; SMA: 128 cm/sec vs. 125 cm/sec, p=.624; RAs: 90 cm/sec vs. 83 cm/sec, p=.654) as shown in **Fig 3** and **Supplemental Table 2**.

Table 1. Demographics and anatomical characteristics of 419 patients treated by fenestrated-branched endovascular repair (FB-EVAR) for thoracoabdominal aortic aneurysm or pararenal aortic aneurysms

Demographics	N=419	
Gender, male	292	69.7
Age, years	74.2 (8.05)	
BMI	28.1 (5.52)	
Comorbidities		
Coronary artery disease	207	49.4
CHF	37	8.8
Diabetes	57	13.6
Hypertension	371	88.5
Hypercholesterolemia	331	79.0
COPD	127	30.3
Tobacco use	330	78.8
PAD	65	15.5
Stroke/TIA	42	10.0
CKD	195	46.5
Anatomical characteristics		
Maximum aortic aneurysm diameter	65.1 (10.9)	
No. of target vessels per patient	3.89 (0.52)	
Crawford extent		
Extent I	20	4.8
Extent II	97	23.2
Extent III	43	10.3
Extent IV	131	31.3
Pararenal	128	30.5
Aneurysm status		
Asymptomatic	411	98.1
Symptomatic non-ruptured	6	1.4
Contained rupture	2	0.5

BMI, body mass index; *CHF*, congestive heart failure; *COPD*, chronic obstructive pulmonary disease; *PAD*, peripheral arterial disease; *TIA*, transient ischemic attack; *CKD*, chronic kidney disease.
Categorical variables are presented as number (%) and continuous variables as mean (SD).

In a subanalysis we distinguished target vessels incorporated by either reinforced fenestrations or directional branches. Our findings revealed a significant increase in PSV for most segments of the fenestrated vessels, while there was a significant decrease in PSV for most branched vessels. Additionally, we observed that post-procedurally, fenestrated vessels had higher PSV values, although they remained below the stenosis threshold (**Table 3**).

We compared balloon-expandable stents and self-expandable stents in target vessels incorporated by directional branches. For the mesenteric arteries, most target vessels

had balloon-expandable stents (65%). For the renal arteries both balloon-expandable and self-expandable stents were equally used. For the mesenteric arteries the mean PSV for all segments was 135±36 cm/sec for balloon-expandable stents and 105±33 cm/sec for self-expandable stents, $p<.001$. For the renal arteries there was no significant difference in PSV comparing the type of stents (balloon-expandable 79±36 cm/sec vs. self-expandable 73±23 cm/sec, $p=.29$).

Table 2. Mean peak systolic velocity (PSV) at baseline and 6 and 8 weeks after fenestrated-branched endovascular repair (FB-EVAR) for branched and fenestrated vessels

Mean (SD)	Vessels	Preoperative (cm/sec)	6/8 weeks (cm/sec)	*p*-value
CA (N=260)	Origin	130 (50)	132 (53)	.67
	Proximal	135 (55)	142 (56)	.35
	Mid	126 (47)	145 (53)	**.03**
SMA (N=409)	Origin	128 (58)	125 (44)	.57
	Proximal	140 (54)	137 (48)	.45
	Mid	126 (48)	134 (48)	**.01**
RRA (N=379)	Origin	96 (62)	87 (34)	.09
	Proximal	95 (45)	95 (37)	.97
	Mid	83 (31)	93 (42)	**.003**
LRA (N=363)	Origin	89 (56)	84 (35)	.57
	Proximal	91 (52)	93 (38)	.42
	Mid	82 (41)	92 (39)	**<.001**

PSV, peak systolic velocity; *CA*, celiac axis; *SMA*, superior mesenteric artery; *RRA*, right renal artery; *LRA*, left renal artery.

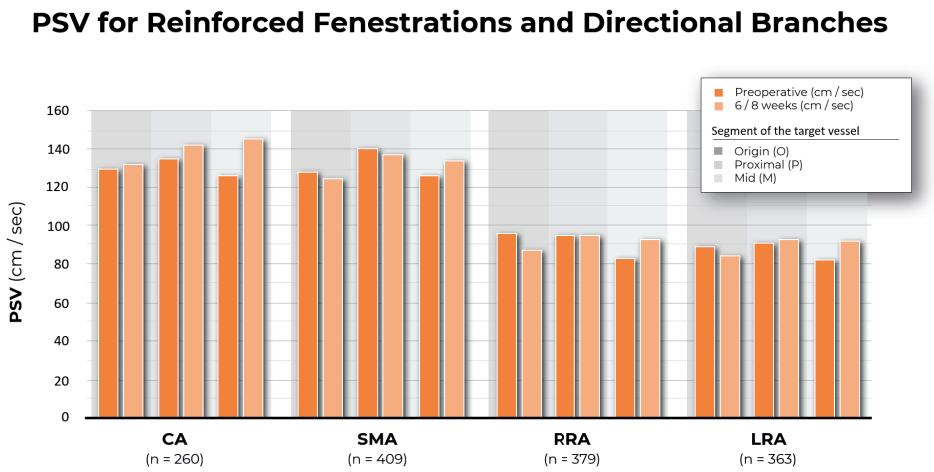

Fig 2. Mean peak systolic velocity (PSV) at baseline and at 6 and 8 weeks after fenestrated and branched endovascular aneurysm repair (FB-EVAR) for branched and fenestrated vessels. *CA*, celiac axis; *LRA*, left renal artery; *RRA*, right renal artery; *SMA*, superior mesenteric artery.

Table 3. Mean peak systolic velocity (PSV) at baseline and at 6 and 8 weeks after fenestrated-branched endovascular repair (FB-EVAR) for **(A)** fenestrated targeted vessels and **(B)** branched targeted vessels after FB-EVAR

A Mean (SD)	Vessels	Preoperative (cm/sec)	6/8 weeks (cm/sec)	*p*-value
CA (N=148)	Origin	129 (50)	141 (56)	.19
	Proximal	135 (55)	153 (59)	**.05**
	Mid	127 (50)	155 (54)	**.009**
SMA (N=267)	Origin	125 (52)	134 (42)	**.04**
	Proximal	135 (47)	148 (45)	**.008**
	Mid	123 (43)	143 (46)	**<.001**
RRA (N=302)	Origin	91 (55)	89 (33)	.91
	Proximal	93 (43)	98 (36)	.22
	Mid	83 (31)	95 (44)	**.002**
LRA (N=292)	Origin	88 (53)	87 (34)	.61
	Proximal	90 (51)	97 (37)	**.05**
	Mid	82 (41)	94 (36)	**<.001**

B Mean (SD)	Vessels	Preoperative (cm/sec)	6/8 weeks (cm/sec)	*p*-value
CA (N=112)	Origin	132 (51)	113 (41)	.19
	Proximal	137 (56)	116 (38)	.08
	Mid	125 (41)	124 (43)	.94
SMA (N=142)	Origin	134 (72)	99 (38)	**.002**
	Proximal	152 (67)	107 (42)	**<.001**
	Mid	132 (60)	113 (44)	.12
RRA (N=77)	Origin	121 (88)	76 (38)	**.01**
	Proximal	105 (51)	81 (41)	**.02**
	Mid	84 (36)	83 (33)	.99
LRA (N=71)	Origin	97 (72)	63 (30)	**.04**
	Proximal	98 (59)	71 (36)	.06
	Mid	86 (40)	82 (51)	.95

SD, standard deviation; *CA*, celiax axis; *SMA*, superior mesenteric artery; *RRA*, right renal artery; *LRA*, left renal artery.

Discussion

DUS is widely used for surveillance of renal and mesenteric target vessels following FB-EVAR according to local protocols within each institution, but few studies outlined the expected changes in velocity measurements after placement of bridging stents or what constitutes a normal velocity to describe patent vessels. It has been previously speculated that differences in compliance with rigid stents may result in velocity elevation among patients undergoing FB-EVAR or stenting for other indications.[14, 18, 19]

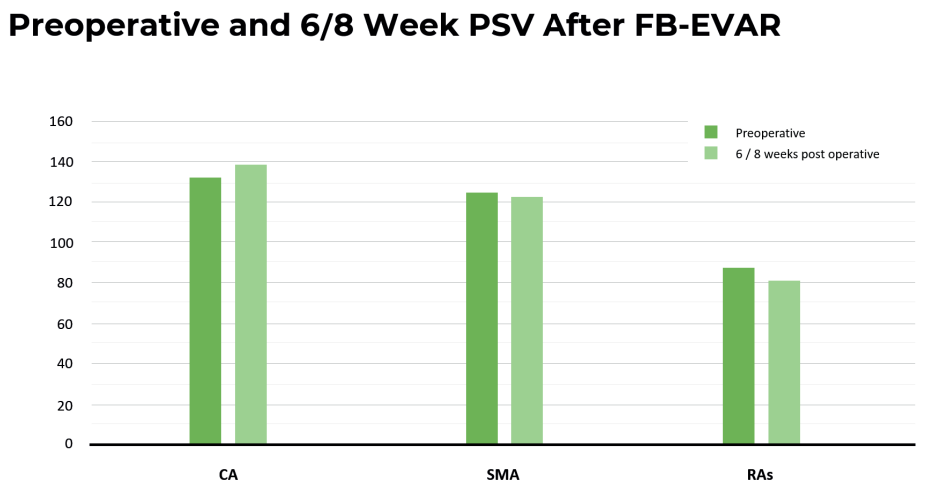

Fig 3. Mean peak systolic velocity (PSV) of all segments (origin, proximal and mid) for the celiac axis (CA), superior mesenteric artery (SMA), and renal arteries (RAs) preoperatively and postoperative after 6 and 8 weeks.

This study shows that renal and mesenteric vessels without native arterial stenosis have PSV measurements well within normal limits to the criteria that has been established for patients with occlusive disease. In addition, stenting of vessels without native stenosis has not resulted in major changes in PSV measurements, with only a modest increase in PSV observed in the mid segment of the stented celiac, SMA and renal artery. Although this increased velocity is statistically significant, this is still well below the threshold used to diagnose a significant stenosis in native arteries and therefore not clinically relevant.

In our subanalyses we found differences in fenestrated and branched target vessels, with fenestrated vessels showing an increase in PSV, and branched target vessels showing a decrease in PSV after 6-8 weeks. The observed differences align with the findings of Tran and colleagues, who utilized computational fluid analysis and reported an increase in peak renal artery pressure after incorporation of reinforced fenestrations.[20] Another study of Tran and associates, on DUS after renal stenting using reinforced fenestrations, reported that the postoperative proximal PSVs could serve as a strong classifier for stenosis when greater than 215 cm/sec.[6] Our hypothesis suggests that these differences could potentially be linked to the gradual change in flow for directional branches, as they commence from a higher level. And the presence of sharp angles in reinforced fenestrations, which can contribute to an increase in PSVs.

Furthermore, we differentiated between balloon-expandable and self-expandable stents for target vessels with directional branches, finding a higher mean PSV in

mesenteric arteries with balloon-expandable stents compared to self-expandable stents (135±36 cm/sec vs. 105±33 cm/sec, $p<.001$). However, the effect of both reinforced fenestrations and directional branches, and type of stents should be further investigated in a longitudinal study.

Soult and associates analyzed the effect of stent placement on velocity measurements among patients with mesenteric arterial occlusive disease.[14] In that study, stented mesenteric vessels without significant residual stenosis had increased PSV measurements, which averaged 302 cm/sec for the CA and 367 cm/sec for the SMA. The higher than expected baseline velocity was attributed to a decrease in vessel compliance due to placement of rigid balloon expandable stents. Our results do not corroborate the theory that presence of stents is solely responsible for higher velocities leading to different criteria for stenosis, and post-stent velocity measurements in patients with atherosclerotic disease should not be extrapolated to those who undergo endovascular incorporation for aneurysms. There was no difference in velocity in the origin and proximal stent segments with only modest elevation in the mid segment below threshold criteria for significant stenosis. Baseline velocities averaged below 150 cm/sec for all the three vessel targets.

The effect of stent placement on velocity measurements has been more extensively studied in the carotid territory. After carotid artery stenting, studies have shown that the same velocity criteria that is used to identify stenosis in native vessels does not apply to a stented carotid artery. The reasons for the higher velocity criteria is thought to be related to altering biomechanical properties and stiffness of the stented arteries. Reduction of compliance will lead to elevation of velocity.[18, 19] Furthermore, the type of stent should also be considered, as the study of Spies and colleagues showed that differences were seen between open and closed cell self-expandable stents and fluctuations in PSV in an in-vitro model.[21] Therefore development of a customized threshold for stented vessels needs to be addressed.

Results of a study by Tran and colleagues investigating the effect of stenting fenestrations using computational flow modelling may offer an explanation for our slight increase in PSV measurements.[20] Hemodynamic changes were observed after FEVAR, and renal fenestrations were associated with a small increase of mean peak proximal aortic arterial pressure and an increase of peak renal artery pressure. Also, there was an increase in blood flow to the renal arteries after the fenestrated repair. Nevertheless, stenting did not induce wall shear stress in the proximal and distal renal artery.[20]

Our findings are similar to the study by Zierler and associates, where stented non-stenotic renal arteries showed no significant change in PSV after 30 days and most

patients had a velocity below the threshold for native renal arteries. They reported a median velocity at baseline of 121 cm/s and 109 cm/s at 30 days. In our study group the baseline median velocity was 73 cm/s and 79 cm/s at 6-8 weeks. The SMA velocities were also similar despite the fact that, in their study, the SMA was not stented. The mean velocity was 128 cm/s at baseline and 115 cm/s at 30 days compared to our results with mean velocity of 128 cm/sec at baseline and 125 cm/sec at 6-8 weeks.[7]

This study is the first to analyze changes in PSV on various arterial segments of the targeted vessels after stenting related to FB-EVAR. Limitations to address include the fact that we prioritized and focused on PSV reflecting our clinical practice, and did not collect renal to aortic ratios and resistive indices, or other criteria to define renal artery stenosis using DUS.[10] Further research should be conducted to investigate these parameters after FB-EVAR. We have chosen to include in the analysis only arterial segments that would be affected by the presence of the newly placed stent whether directly (origin and proximal) or indirect velocity jet (mid). The distal segment was excluded from the analysis as additional factors such as vessel tapering and branching may account for higher velocities and could be a confounding factor. A total of 220 vessels (13%) were not able to be visualized with DUS, due to body habitus and overlying bowel gas. It's important to note that these limitations are inherent to ultrasound imaging. Our study strengths include the prospective design, large number of patients and the standard protocol performed by experienced sonographers. Our study design did not address the much needed criteria for target vessel stenosis and future studies are planned to answer that question. Additionally, it is recommended to conduct a longitudinal study to examine the variances in reinforced fenestrations and directional branches, along with the type and quantity of bridging stents used.

Conclusion

In this study, we have found no significant increase in the overall velocities after stenting of non-stenotic renal and mesenteric arteries following FB-EVAR. There was a statistically significant modest increase of velocity in the mid segment, however this was not clinically significant. Peak systolic velocities in stented renal and mesenteric arteries were well below the threshold for significant stenosis in native vessels with mean PSV of 141 cm/s in the CA, 125 cm/s in the SMA and 83 cm/s in the renal arteries. These values can be used as a baseline or benchmark for expected PSVs following renal-mesenteric stenting during FB-EVAR.

Fig 1 and Supplemental Fig 1 in this chapter were reproduced from Endovascular Aortic Repair: Current Techniques with Fenestrated, Branched, and Parallel Stent-Grafts (text by G.S. Oderich; illustrations by Mr. David Factor), used with permission.

References

1. Anderson JL, Adam DJ, Berce M, Hartley DE. Repair of thoracoabdominal aortic aneurysms with fenestrated and branched endovascular stent grafts. J Vasc Surg. 2005;42(4):600-7.
2. Chuter TA. Branched and fenestrated stent grafts for endovascular repair of thoracic aortic aneurysms. J Vasc Surg. 2006;43 Suppl A:111A-5A.
3. Greenberg RK, Haulon S, Lyden SP, Srivastava SD, Turc A, Eagleton MJ, et al. Endovascular management of juxtarenal aneurysms with fenestrated endovascular grafting. J Vasc Surg. 2004;39(2):279-87.
4. Dossabhoy SS, Simons JP, Diamond KR, Flahive JM, Aiello FA, Arous EJ, et al. Reinterventions after fenestrated or branched endovascular aortic aneurysm repair. J Vasc Surg. 2018;68(3):669-81.
5. Schanzer A, Oderich GS. Management of Abdominal Aortic Aneurysms. N Engl J Med. 2021;385(18): 1690-8.
6. Tran K, McFarland G, Sgroi M, Lee JT. Duplex ultrasound surveillance of renal branch grafts after fenestrated endovascular aneurysm repair. J Vasc Surg. 2019;70(4):1048-55.
7. Zierler RE. Duplex ultrasound follow-up after fenestrated and branched endovascular aneurysm repair (FEVAR and BEVAR). Semin Vasc Surg. 2020;33(3-4):60-4.
8. Karthikesalingam A, Al-Jundi W, Jackson D, Boyle JR, Beard JD, Holt PJ, et al. Systematic review and meta-analysis of duplex ultrasonography, contrast-enhanced ultrasonography or computed tomography for surveillance after endovascular aneurysm repair. Br J Surg. 2012;99(11):1514-23.
9. Wilmink AB, Forshaw M, Quick CR, Hubbard CS, Day NE. Accuracy of serial screening for abdominal aortic aneurysms by ultrasound. J Med Screen. 2002;9(3):125-7.
10. Olin JW, Piedmonte MR, Young JR, DeAnna S, Grubb M, Childs MB. The utility of duplex ultrasound scanning of the renal arteries for diagnosing significant renal artery stenosis. Ann Intern Med. 1995; 122(11):833-8.
11. Hoffmann U, Edwards JM, Carter S, Goldman ML, Harley JD, Zaccardi MJ, et al. Role of duplex scanning for the detection of atherosclerotic renal artery disease. Kidney Int. 1991;39(6):1232-9.
12. Zhou W, Felkai DD, Evans M, McCoy SA, Lin PH, Kougias P, et al. Ultrasound criteria for severe in-stent restenosis following carotid artery stenting. J Vasc Surg. 2008;47(1):74-80.
13. AbuRahma AF, Maxwell D, Eads K, Flaherty SK, Stutler T. Carotid duplex velocity criteria revisited for the diagnosis of carotid in-stent restenosis. Vascular. 2007;15(3):119-25.
14. Soult MC, Wuamett JC, Ahanchi SS, Stout CL, Larion S, Panneton JM. Duplex ultrasound criteria for in-stent restenosis of mesenteric arteries. J Vasc Surg. 2016;64(5):1366-72.
15. Moneta GL, Yeager RA, Dalman R, Antonovic R, Hall LD, Porter JM. Duplex ultrasound criteria for diagnosis of splanchnic artery stenosis or occlusion. J Vasc Surg. 1991;14(4):511-8; discussion 8-20.
16. Oderich GS, Forbes TL, Chaer R, Davies MG, Lindsay TF, Mastracci T, et al. Reporting standards for endovascular aortic repair of aneurysms involving the renal-mesenteric arteries. J Vasc Surg. 2021; 73(1S):4S-52S.
17. Oderich G. Endovascular Aortic Repair; current Techniques with Fenestrated, Branched and Parallel Stent-Grafts. Cham, Switserland: Springer Nature; 2017. 757 p.
18. Lal BK, Hobson RW, 2nd, Goldstein J, Chakhtoura EY, Duran WN. Carotid artery stenting: is there a need to revise ultrasound velocity criteria? J Vasc Surg. 2004;39(1):58-66.
19. Lal BK, Hobson RW, 2nd, Tofighi B, Kapadia I, Cuadra S, Jamil Z. Duplex ultrasound velocity criteria for the stented carotid artery. J Vasc Surg. 2008;47(1):63-73.
20. Tran K, Yang W, Marsden A, Lee JT, Stanford C. Patient-specific computational flow modelling for assessing hemodynamic changes following fenestrated endovascular aneurysm repair. JVS Vasc Sci. 2021;2:53-69.
21. Spies C, Doshi R, Spoon J, Snell RJ. Carotid artery stent type influences duplex ultrasonography derived peak systolic velocity: findings of an in-vitro model. Catheter Cardiovasc Interv. 2007; 70(2):309-15.

Supplemental Material

Supplemental Table 1. Detailed pre-procedural and postprocedural protocol of the duplex ultrasound (DUS) measurements for fenestrated and branched endovascular aneurysm repair (FB-EVAR)

Images	Label
1. Mesenteric arteries	
Celiac Artery	
CA Origin	CAO
CA Proximal	CAP
CA Mid	CAM
CA Distal	CAD
Superior mesenteric artery	
SMA Origin	SMAO
SMA Proximal	SMAP
SMA Mid	SMAM
SMA Distal	SMAD
2. Renal arteries	
RRA/LRA Origin	RRO/LRO
RRA/LRA Proximal	RRP/LRP
RRA/LRA Mid	RRM/LRM
RRA/LRA Distal	RRD/LRD

PSV, peak systolic velocity; *CA*, celiac axis; *SMA*, superior mesenteric artery; *RRA*, right renal artery; *LRA*, left renal artery.

Supplemental Table 2. Results of mean peak systolic velocity (PSV) of all segments (origin, proximal, mid) preoperative and postoperative (6/8 weeks) for the celiac axis (CA), superior mesenteric artery (SMA) and renal arteries (RAs)

Vessels	Preoperative (cm/sec) Mean (SD)	6/8 weeks (cm/sec) Mean (SD)	*p*-value
CA (N=260)	135	141	.056
SMA (N=409)	128	125	.62
RAs (N=742)	90	83	.65
(RRA) (N=379)	97	87	.47
(LRA) (N=363)	90	83	.99

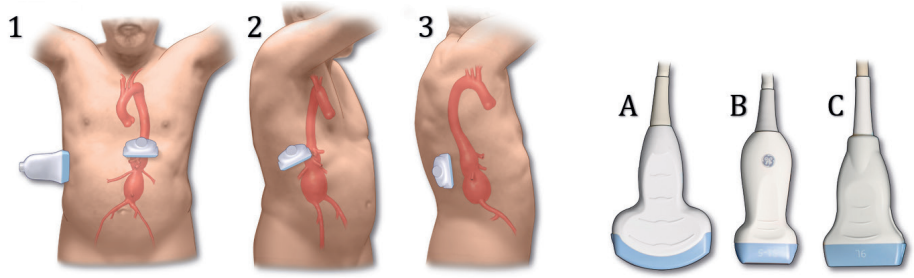

Supplemental Fig 1. Positioning of the patient (left to right). **(1)** Typically, the patient positioning was supinely with transducer in the midline or lateral upper abdomen. **(2)** Oblique, and **(3)** lateral decubitus are used if better visualization is needed. Duplex ultrasound (DUS) transducers. **(A)** C1-5 curved transducer was commonly used. **(B)** S1-5 vector transducer was used in patients with large body habitus. **(C)** 9L transducer was occasionally used for patients with slim body habitus.



Chapter 9

Prospective Assessment of Changes in Target Vessel Peak Systolic Velocity Measurements After Fenestrated-Branched Endovascular Aortic Repair

Titia A.L. Sulzer[1], Thanila A. Macedo[1], Thomas Mesnard[1], Emanuel R. Tenorio[1], Guilherme Baumgardt Barbosa Lima[4], Heather Hatz[2], Gina K. Hesley[2], Alexander Lekah[2], Tiziano Tallarita[3], Ying Huang[1], Bernardo Mendes[4], Gustavo S. Oderich[1]

[1] Department of Cardiothoracic & Vascular Surgery, Advanced Aortic Research Program at the University of Texas Health Science Center at Houston, McGovern Medical School, Houston, TX.
[2] Department of Radiology, Mayo Clinic, Rochester, MN.
[3] Department of Vascular Surgery, Mayo Clinic, Eau Claire, WI.
[4] Department of Vascular and Endovascular Surgery, Mayo Clinic, Rochester, MN.

This study was presented at the Vascular Annual Meeting of the Society for Vascular Surgery (National Harbor, MD, the United States, June 2023); The Dutch Vascular Society Meeting (Noordwijkerhout, the Netherlands, April 2023); The Fast-Track session of the European Society for Vascular Society Annual Meeting (Istanbul, Türkiye, September 2025).

Journal of Endovascular Therapy,
September 2025, pages 1-12
DOI: 10.1177/15266028251368250.

Abstract

Objective: Target vessel stenosis or occlusion is a common indication for secondary intervention after fenestrated-branched endovascular aortic repair (FB-EVAR) requiring long-term imaging surveillance including duplex ultrasound (DUS). This study aimed to describe and compare longitudinal changes in peak systolic velocity (PSV) measurements for renal and mesenteric arteries targeted by directional branches (DBs) or reinforced fenestrations (RFs).

Methods: Patients enrolled in a prospective, non-randomized study (2013-2020) had duplex ultrasound of celiac axis (CA), superior mesenteric artery (SMA) and renal arteries (RAs) obtained pre-operatively, at 6-8 weeks, 6 months, and annually. Vessels with pre-procedural stenosis were excluded. Outcomes were variations in PSV over time for target vessels incorporated by DBs or RFs, differences in balloon-expandable stent-grafts (BESGs) and self-expandable stent-grafts (SESGs), PSV measurements prior to secondary interventions related to vessel stenosis, and a predictive value of PSV for stenosis requiring secondary intervention.

Results: A total of 419 patients (292 male, mean age 74±8 years old) were enrolled, with 1,311 target vessels analyzed preoperatively, including 607 mesenteric and 704 renal arteries. Over a median follow-up of 23 months (interquartile range [IQR], 7-36), PSV measurements decreased in the first 6-8 weeks after DB incorporation, remained stable, followed by a non-significant increase at 5 years. PSV increased in the first 6 months using RFs with post-operative velocities significantly higher ($p<.05$) for RFs compared to DBs. Branched mesenteric vessels stented with BESGs had higher velocities than SESGs ($p<.05$). Of the 23 target vessels treated by secondary intervention for stenosis, 19 (83%) had velocities above the thresholds for native, non-stented vessels. Furthermore, in RAs (n=20) PSV effectively predicted clinically relevant stenosis, AUC was 0.98, with a 231 cm/s threshold offering 84% sensitivity with 100% specificity.

Conclusion: Longitudinal follow-up shows that velocity changes vary depending on the type of incorporation, vessel, and bridging stent. For DBs, PSV decreased initially, stabilized, and showed a non-significant increase at 5 years. In contrast, PSV increased with RFs and remained higher than DBs. Despite these variations, velocities remained below established thresholds for clinically significant stenosis in non-stented vessels. Criteria for in-stent stenosis may differ, and PSV alone should not be the sole indicator for reintervention.

Introduction

Fenestrated and branched endovascular aortic aneurysm repair (FB-EVAR) has expanded the scope and applicability of endovascular techniques in the treatment of complex aortic aneurysms. The technique encompasses variations of stent designs with reinforced fenestrations (RF) or directional branches (DB) to incorporate the renal and mesenteric vessels with the placement of bridging stent-grafts.[1,2] Lifelong surveillance is required, as target vessel complications remain one of the most frequent indications for secondary interventions.[3,4] According to data from the United States Aortic Research Consortium, the rates for target artery occlusion or stenosis are 2% for mesenteric arteries and 8% for renal arteries.[5]

Despite computed tomographic angiography (CTA) serving as the primary method for surveillance after FB-EVAR, duplex ultrasound (DUS) is a valuable complementary non-invasive imaging modality, detecting hemodynamic alterations in stents. This is especially useful in small, stented vessels, where metallic artifact limits accuracy of CTA evaluation.[6,7] The two modalities, CTA and DUS, are often complementary for decision-making into timing and type of secondary intervention if needed.

Ultrasound is a desirable modality because of its favorable cost, wide availability, no need for iodinated contrast, and absence of ionizing radiation.[7] Duplex ultrasound examination after FB-EVAR requires qualified sonographers, preferentially trained in vascular imaging, to maximize success and accuracy of results. Although the ability to detect vessel stenosis or occlusion is a valuable advantage of DUS, morphologic complications such as migration and stent fracture remain a limitation of current ultrasound techniques.[8,9] A prior report by our group confirmed that stenting of non-stenotic renal and mesenteric arteries during FB-EVAR is not associated with increase in target vessel peak systolic velocity (PSV) in the first 6-8 weeks.[10] Nonetheless, there is paucity of evidence concerning the long-term effects of stenting non-stenotic vessels following FB-EVAR, as well as which threshold should be used for reintervention, if any. The aim of the present study was to assess velocity measurements over time after FB-EVAR and describe velocity measurements among patients who underwent secondary interventions for stent stenosis.

Methods

Study design and population

This study involved a cohort of patients enrolled in an ongoing prospective non-randomized physician-sponsored investigational device exemption protocol (Clinical Trial number: NCT02089607) to evaluate FB-EVAR between October 2013 and May 2020. Eligible patients included those undergoing FB-EVAR for complex aortic aneurysms. The study was approved by the Institutional Review Board, and patients provided informed consent. Prospective DUS evaluations of renal-mesenteric vessels were conducted before the procedure, at 6-8 weeks after the procedure, six months, one-year, and yearly thereafter for the first five years. The examinations were all performed in a single ultrasound laboratory with a high volume of vascular ultrasound examinations (over 10,000 studies per year). These were conducted by registered vascular technologist (RVTs), with several years of experience and a substantial vascular exam-case load, all following a standardized protocol. We excluded vessels with significant stenosis defined preoperatively by DUS, according to established criteria of ≥60% stenosis in the renal arteries (RAs) (200 cm/s) and ≥70% stenosis in the celiac axis (CA) and superior mesenteric artery (SMA) (200 and 275 cm/s, respectively), to eliminate potential confounding factors in assessing velocity changes specifically related to stent placement.[11-13] The present study followed the relevant Strengthening the Reporting of Observational Studies in Epidemiology (STROBE) guidelines.[14]

Outcomes

The study's primary outcome was to assess the variations in PSV (cm/s) of the stented mesenteric and renal arteries over a five-year period, stratified by type of incorporation (RFs and DBs). Secondary outcomes included changes in PSV (cm/s) over a five-year period for target vessels incorporated with DBs using either BESGs or SESGs, a description of PSV measurements obtained prior to a secondary intervention related to vessel stenosis, and an exploratory analysis of the predictive value of PSV for stenosis requiring secondary intervention.

Definitions

For the analysis of secondary intervention related to vessel stenosis, we excluded vessels without DUS examination immediately prior to the secondary intervention. The indication for a secondary intervention was individualized and left at the discretion of the primary investigator (G.S.O.). Factors considered in the decision to intervene included perceived severity of stenosis after analysis of PSV and CTA, possible underlying etiology,

progression rate, and other comorbidities (e.g., chronic kidney disease, solitary kidney). This also applied to some asymptomatic patients, in whom high-grade stenosis or high-risk clinical context justified intervention. Furthermore, patient demographics, comorbidities, cardiovascular risk factors, medication status, aortic history, procedural outcomes, anatomic and device characteristics were collected. Definitions were based on the Society for Vascular Surgery (SVS) reporting standards for endovascular repair of aneurysms involving the renal and mesenteric arteries.[15]

Endovascular technique

Patients received either a patient-specific stent graft with any combination of RFs and/or DBs or an off-the-shelf multi-branch stent graft manufactured by Cook Medical (Bloomington, IN, USA). The selection of the stent-graft design was performed at the discretion of the principal investigator, taking into consideration specific anatomical characteristics of the target vessel, e.g. factors such as the extent of the aneurysm, the inner luminal diameter of the aorta, and the orientation of the target vessel. Fenestrations were aligned with BESGs, whereas branches were aligned with either BESGs or SESGs based on anatomical considerations and operator preferences. The procedural techniques have been described previously.[16]

Duplex ultrasound protocol

Duplex ultrasound scans were performed using GE E9 scanners by experienced RVTs. The DUS protocol has been described in detail by our team in a prior study.[10] DUS was performed using pre-defined protocols prospectively and included thorough PSV (cm/s) measurements obtained with <60° angles throughout the visualized vessel.

Statistical analysis

For the demographics, baseline comorbidities, anatomic and device characteristics, we used descriptive statistics (counts and percentages only), without inferential testing. The continuous variable PSV was evaluated for normal distribution using histograms and Q-Q plots and reported as mean and standard deviation. Mesenteric arteries and renal arteries were evaluated independently. We used the maximum of the segments (origin, proximal, and mid) of all target vessels in our longitudinal analysis. For the threshold of PSV at the time of secondary interventions for stenosis, the highest PSV value of the segments of each vessel was used, and the median and IQR were reported. T-tests were used to perform pairwise comparisons of velocities between consecutive time points (baseline to five years) to evaluate differences. To illustrate changes in measured PSVs at different time points within the mesenteric and renal arteries, as well as between

SESGs and BESGs, we used spaghetti plots. These plots were supplemented with locally weighted scatter plot smoothing regression lines (LOESS) and with 95% confidence intervals (95% CI). LOESS is a nonparametric regression method effect that uses locally weighted regression to fit a smooth curve through points in a scatterplot. This method showed the estimated overall variability of the PSVs.[17] Analysis of Variance (ANOVA) was chosen to assess the effects of the independent variables (DBs v RFs and BESGs v SESGs) on the dependent variable (PSV) across multiple time points. To evaluate the predictive value of PSV for stenosis requiring secondary intervention, a 1:1 nearest-neighbor matching of stenotic target vessels with non-stenotic controls was performed, based on vessel type, incorporation, and follow-up duration. Subsequently, a receiver operating characteristic (ROC) analysis was conducted, and the optimal PSV threshold was determined using Youden's index.

A *p*-value of less than .05 was considered statistically significant. The data analysis was performed using R version 4.0.3 (R Foundation for Statistical Computing, Vienna, Austria).

Results

Patient characteristics

There were 419 patients, 292 male and 127 female, with mean age of 74±8 years-old treated by FB-EVAR between October 2013 and May 2020 who were included in the analysis. Aneurysm extent was classified as thoracoabdominal aortic aneurysm (TAAA) in 69% (Crawford extent IV in 31%) or complex abdominal aortic aneurysms in 31%. The mean number of renal-mesenteric vessels targeted per patient was 3.9±0.5. Demographic information, baseline comorbidities, and anatomic details are listed in **Table 1**.

Significant stenosis was identified in 161 targeted vessels preoperatively, and these vessels were subsequently excluded from the study. The remaining 1,411 targeted vessels, including 260 CAs, 409 SMAs, and 742 RAs, had no evidence of preexisting underlying stenosis.

Preoperatively, 100 vessels could not be visualized due to technical limitations (body habitus and overlying bowel gas (CA: N=42; SMA: N=29; RAs: N=29). The study included 1,311 vessels identified by ultrasound preoperatively and followed over a five-year study period, with some patients having missed or incomplete follow-up DUS studies (**Fig 1**).

The overall technique success rate for ultrasound evaluations was 98% with 126/5,229 vessels failed to obtain a measurement due to technique limitations including overlying

bowel gas, body habitus, limited scanning window and uncooperative patient. In 19 vessels, relining with additional covered stents was performed, based on the clinical decision of the primary investigator (G.S.O.). Bare metal stent relining was not performed in our cohort.

Table 1. Demographics and anatomical characteristics of 419 patients treated by FB-EVAR for TAAA or pararenal aortic aneurysms

Demographics	(N=419)
Gender, male	292 (70)
Gender, female	127 (30)
Age, years	74±8.1
BMI	28±5.5
Comorbidities	
Coronary artery disease	207 (49)
CHF	37 (8.8)
Diabetes	57 (14)
Hypertension	371 (86)
Hypercholesterolemia	331 (79)
COPD	127 (30)
Tobacco use	330 (79)
PAD	65 (16)
Stroke/TIA	42 (10)
CKD	195 (47)
Anatomical characteristics	
Maximum aortic aneurysm diameter	65.1±10.9
No. of target vessels per patient	3.89±0.52
Crawford extent	
Extent I	20 (4.8)
Extent II	97 (23)
Extent III	43 (10)
Extent IV	131 (31)
Pararenal	128 (31)
Aneurysm status	
Asymptomatic	411 (98)
Symptomatic non-ruptured	6 (1.4)
Contained rupture	2 (0.5)

Data are presented as N (%) or mean±standard deviation. *BMI*, body mass index; *CHF*, congestive heart failure; *COPD*, chronic obstructive pulmonary disease; *PAD*, peripheral arterial disease; *TIA*, transient ischemic attack; *CKD*, chronic kidney disease.

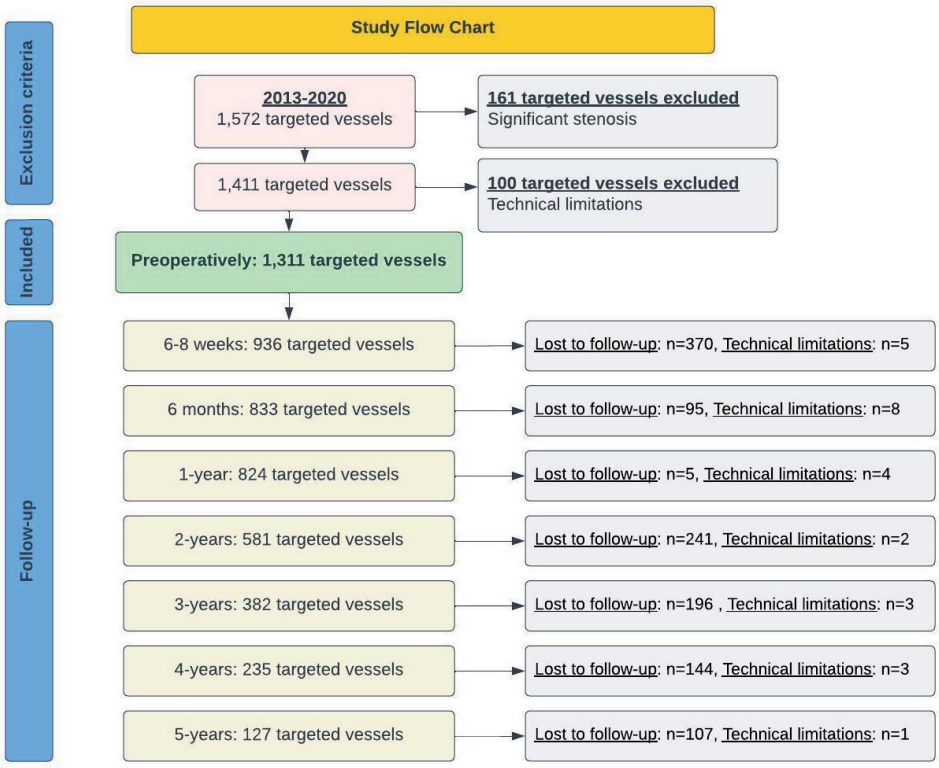

Fig 1. Study flowchart showing the number of target vessels excluded preoperatively, lost to follow-up, or not evaluated due to technical issues.

Changes in PSV over time between RFs and DBs in mesenteric arteries

In mesenteric arteries following FB-EVAR, DBs and RFs had a significant impact on the PSV over a five-year period (ANOVA-test, $p<.001$) (**Fig 2**). Among vessels targeted using RFs, PSV significantly increased during the first 6 months, followed by a continued, non-significant increase in PSVs until year 5 (**Table 2**). The maximum PSV was 148±52 cm/s at baseline, 166±53 cm/s at 6-8 weeks, 187±62 cm/s at 6m, 190±58 cm/s at 1 y, 193±60 cm/s at 2 y, 197±64 cm/s at 3 y, 204±67 cm/s at 4 y and 198±69 cm/s at 5 y. Conversely, vessels targeted by DBs showed a significant decrease in PSV in the first 6-8 weeks, followed by non-significant fluctuations with a gradual increase until year 1, a slight decrease by year 2, and another increase until year 5 (**Table 2**). Maximum PSV was 158±67 cm/s at baseline, 127±43 cm/s at 6-8 weeks, 135±45 cm/s at 6 m, 137±45 cm/s at 1 y, 132±44 cm/s at 2 y, 134±44 cm/s at 3 y, 135±69 cm/s at 4 y and 139±44 cm/s at 5 y. Velocities did not differ significantly between male and females.

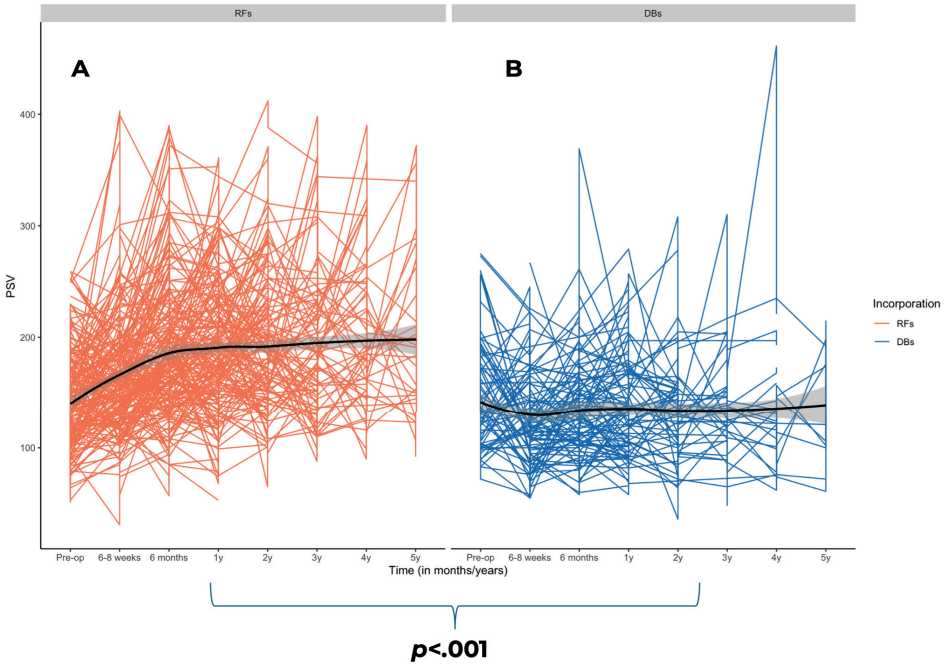

Fig 2. Changes in maximum PSV over time between reinforced fenestrations **(A)** and directional branches **(B)** in mesenteric arteries following fenestrated-branched endovascular aortic repair. *PSV*, peak systolic velocity.

Table 2. Pairwise comparisons of maximum peak systolic velocity in mesenteric arteries after FB-EVAR, including reinforced fenestrations and directional branches, at consecutive time points (baseline to five years)

Mean (SD)	RFs (cm/sec)	*p*-value	DBs (cm/sec)	*p*-value
Baseline	148±52		158±67	
6-8 weeks	166±53	**<.001**	127±43	**<.001**
6 months	187±62	**<.001**	135±45	.12
1 year	190±58	.30	137±45	.96
2 years	193±60	.60	132±44	.09
3 years	197±64	.86	134±44	.18
4 years	204±67	.58	135±69	.71
5 years	198±69	.62	139±44	.11

SD, standard deviation; *RFs*, reinforced fenestrations; *DBs*, directional branches. (*P*-values calculated between time intervals).

Changes in PSV over time between RFs and DBs in renal arteries

For renal arteries, DBs and RFs also significantly affected the PSV over a five-year period (ANOVA-test, $p<.001$) (**Fig 3**). Unlike observations in mesenteric arteries, RFs showed a significant increase in PSV measurements from 6-8 weeks to 6 months, followed

by stabilization with small, non-significant fluctuations until year 4, and a small but significant increase in year 5 (**Table 3**). Maximum PSV was 108±59 cm/s at baseline, 108±43 cm/s at 6-8 weeks, 118±52 cm/s at 6 m, 118±52 cm/s at 1 y, 120±46 cm/s at 2 y, 117±55 cm/s at 3 y, 122±55 cm/s at 4 y and 131±50 cm/s at 5 y. Conversely, DBs showed a significant decrease in PSV measurements in the first 6-8 weeks, followed by non-significant fluctuations, with a slight increase at 6 months to 1 year, a decrease by year 3, and another increase by year 5 (**Table 3**). Maximum PSV was 124±79 cm/s at baseline, 94±44 cm/s at 6-8 weeks, 95±45 cm/s at 6 m, 104±65 cm/s at 1 y, 91±33 cm/s at 2 y, 82±30 cm/s at 3 y, 87±38 cm/s at 4 y and 109±38 cm/s at 5 y. Velocities did not differ significantly between male and females.

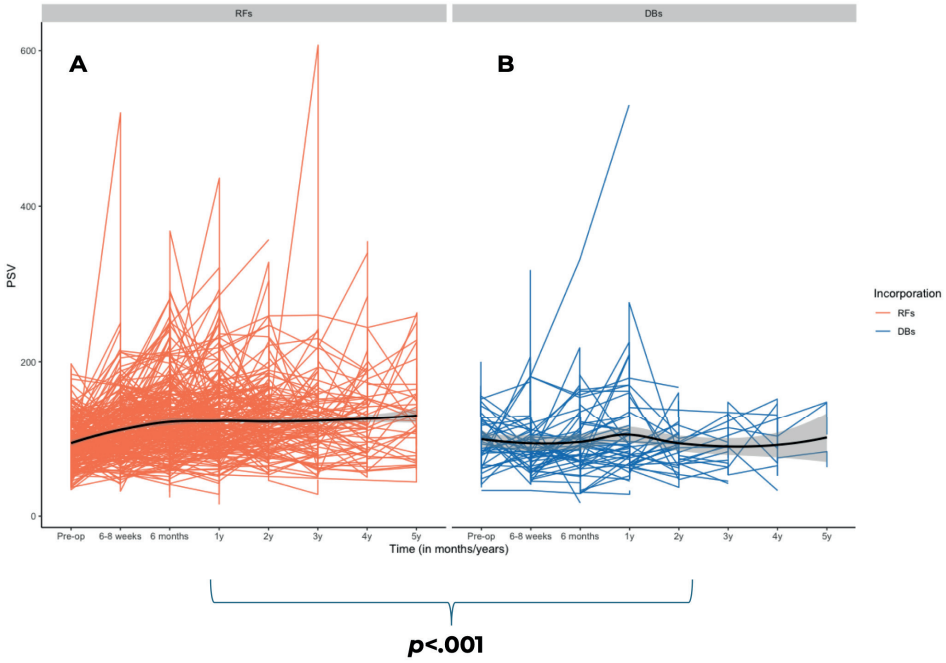

Fig 3. Changes in maximum PSV over time between reinforced fenestrations **(A)** and directional branches **(B)** in renal arteries following fenestrated-branched endovascular aortic repair. *PSV*, peak systolic velocity.

Table 3. Pairwise comparisons of maximum peak systolic velocity in renal arteries after FB-EVAR, including reinforced fenestrations and directional branches, at consecutive time points (baseline to five years

Mean (SD)	RFs (cm/sec)	*p*-value	DBs (cm/sec)	*p*-value
Baseline	108±59		124±79	
6-8 weeks	108±43	.35	94±44	**.019**
6 months	118±52	**<.001**	95±45	.057
1 year	118±52	.26	104±65	.080
2 years	120±46	.20	91±33	.10
3 years	117±55	.43	82±30	.56
4 years	122±55	.83	87±38	.45
5 years	131±50	**.006**	109±38	.43

SD, standard deviation; *DBs*, directional branches; *RFs*, reinforced fenestrations. (*P*-values calculated between time intervals).

Changes in PSV over time between BESGs and SESGs in branched mesenteric arteries

In total, there were 128 branched mesenteric arteries, of which 82 were BESGs and 46 were SESGs. In branched mesenteric arteries, BESGs and SESGs had a significant effect on the PSV (ANOVA-test, p=.011) (**Fig 4**). BESGs exhibited a decrease from baseline to 6-8 weeks, followed by a non-significant increase that remained stable until year 3. Another increase occurred at years 4 and 5, although none of these changes were statistically significant. Maximum PSV for BESG was 157±71 cm/s at baseline, 132±46 cm/s at 6-8 weeks, 143±47 cm/s at 6 m, 144±45 cm/s at 1 y, 141±49 cm/s at 2 y, 141±54 cm/s at 3 y, 185±116 cm/s at 4 y and 198±NA cm/s at 5 y. Conversely, SESGs demonstrated a significant decrease from baseline to 6-8 weeks (p<.001), followed by a non-significant modest increase with velocities remaining below preoperative levels. Maximum PSV was 160±57 cm/s at baseline, 119±38 cm/s at 6-8 weeks, 126±41 cm/s at 6 m, 127±43 cm/s at 1 y, 124±38 cm/s at 2 y, 128±34 cm/s at 3 y, 123±45 cm/s at 4 y and 136±42 cm/s at 5 y.

Fenestrated mesenteric arteries - BESGs Only

All RF target vessels were incorporated by BESGs; detailed PSV trends for these are reported in the section "*Changes in PSV over time between RFs and DBs in mesenteric arteries*". When comparing RFs and DBs incorporated by BESGs, the velocities for the RF group remained higher, confirming that higher velocities in the RF group cannot be justified only by the type of stent used.

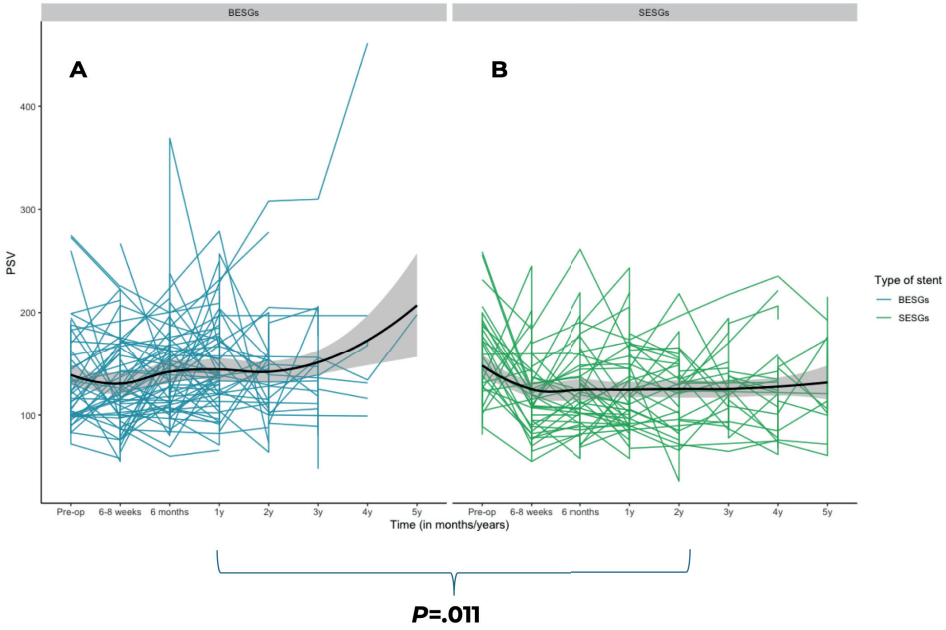

Fig 4. Changes in maximum PSV over time between balloon-expandable stent-grafts **(A)** and self-expandable stent-grafts **(B)** in branched mesenteric arteries following fenestrated-branched endovascular aortic repair. *PSV*, peak systolic velocity.

Changes in PSV over time between BESGs and SESGs in branched renal arteries

In total, there were 72 branched renal arteries, of which 35 were BESGs and 37 were SESGs. In branched renal arteries, BESGs and SESGs did not have a significant effect on PSV (ANOVA-test, p=.78) (**Fig 5**). BESGs showed a non-significant decrease from baseline to 6-8 weeks, followed by non-significant fluctuations, but consistently stayed below baseline values. Maximum PSV was 124±96 cm/s at baseline, 99±41 cm/s at 6-8 weeks, 99±54 cm/s at 6 m, 108±78 cm/s at 1 y, 99±34 cm/s at 2 y, 76±27 cm/s at 3 y, 80±35 cm/s at 4 y. However, SESGs demonstrated a significant decrease from baseline to 6-8 weeks (p<.001) followed by an increase until 6 months (p=.005), followed by another significant decrease from year 1 to year 2 (p=.024), values stayed below baseline. Maximum PSV was 124±61 cm/s at baseline, 88±47 cm/s at 6-8 weeks, 92±37 cm/s at 6 m, 98±48 cm/s at 1 y, 83±30 cm/s at 2 y, 86±31 cm/s at 3 y, 90±41 cm/s at 4 y and 109±38 cm/s at 5 y.

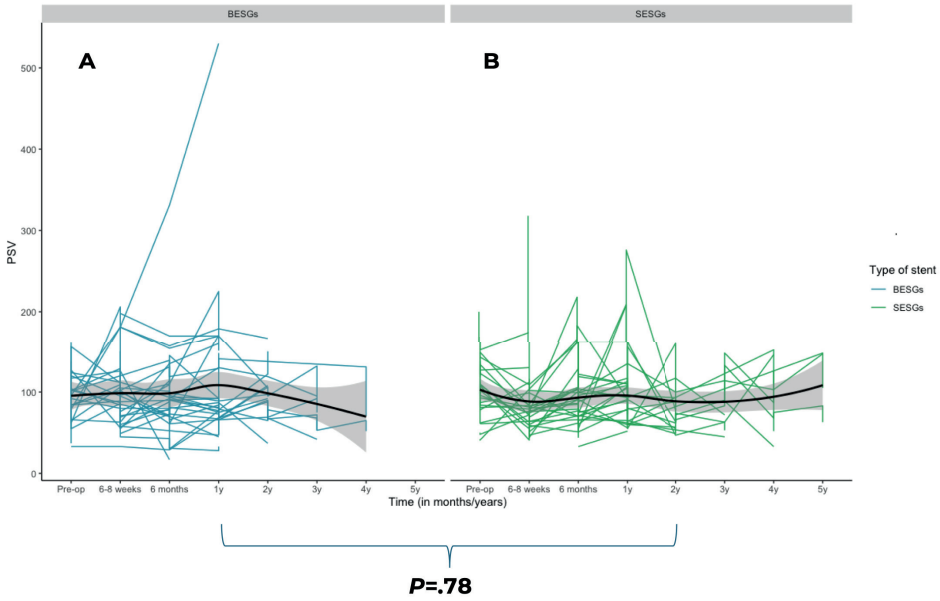

Fig 5. Changes in maximum PSV over time between balloon-expandable stent-grafts **(A)** and self-expandable stent-grafts **(B)** in branched renal arteries following fenestrated-branched endovascular aortic repair. *PSV*, peak systolic velocity.

Threshold of PSV at time of secondary interventions for stenosis

During the study period, 31 of the 1,311 target vessels included in the analysis required a secondary intervention for stenosis (DBs N=10; RFs N=21). Of these 31 vessels, 23 had a DUS examination prior to the intervention. This included 3 SMAs (1 DB, 2 RFs) and 20 RAs (9 DBs, 11 RFs). Notably, 11 underwent intraoperative relining with additional covered stents. The median PSV at time of intervention for superior mesenteric arteries was 350 cm/s ([IQR], 122 to 388 cm/s). For the renal arteries, the median was 308 cm/s ([IQR], 239 to 405 cm/s). Directional branches had lower PSVs for SMA (DBs [N=1], 122 cm/s versus RFs [N=2]; 350 cm/s and 388 cm/s) and a lower median PSV for renal arteries (276 v 318 cm/s) as compared to RFs. Overall, 2 SMAs and 17 RAs had PSVs above the threshold of stenosis for native non-stented vessels (83%, 19/23). After propensity score matching, ROC analysis of 23 stenotic vessels and 23 control vessels was performed. In renal arteries (N=20) PSV effectively predicted clinically relevant stenosis, AUC was 0.98, with a 231 cm/s threshold offering 84% sensitivity with 100% specificity. ROC analysis for mesenteric arteries (N=3) was not feasible due to low numbers.

We also aimed to provide information on the number of vessels and patients that had maximum velocities above the threshold for stenosis, without requiring a secondary

intervention. During the follow-up, 66 CAs, 36 SMAs, and 38 RAs had at some point maximum velocities above 200 and 275 cm/s.

Discussion

This study prospectively evaluated longitudinal changes in DUS measurements after FB-EVAR, including differences in DBs and RFs and type of bridging stents. Over a five-year period, PSV measurements decreased after target vessel incorporation using DBs and increased using RFs with postoperative velocities higher for RFs as compared to DBs. Moreover, the type of stent used for DBs also influenced the PSV over time. PSVs exceeding the recommended threshold for stenosis in native (non-stented) vessels were identified in 83% of target vessels at time of secondary intervention, indicating that this was not the sole criteria used to determine reinterventions for in-stent stenosis. Finally, the ROC analysis performed in renal arteries, gave an AUC of 0.98, indicating PSV effectively predicts clinically relevant stenosis. Thresholds of 231 cm/s gave 84% sensitivity and 100% specificity.

When hypothetically applying this new threshold to our cohort, an additional 16 renal arteries would have had interventions unnecessarily, instead of 38 RAs when using the threshold for native non-stented vessels (>200/s). While this represents an improvement, it would have resulted in 80% increase in the number of secondary interventions compared to what was actually performed (36 instead of 20) obviating the need for refinement and caution using this velocity threshold criteria. However, this analysis does not account for the natural history of vessels with elevated PSVs that did not undergo intervention. Thus, it remains uncertain whether these higher velocities truly represent clinically relevant stenoses that would have progressed or become symptomatic if left untreated. This highlights the need for prospective studies to validate these thresholds. Unfortunately, ROC analysis for mesenteric arteries was not feasible due to low numbers.

We found that incorporation with DBs in renal-mesenteric arteries causes a significant decrease of PSV in the first 6-8 weeks, with small non-significant changes over the 5 years remaining below the baseline velocities (**Table 2**, **Table 3**). This observation may correlate with changes in flow dynamics, which in nearly all cases was antegrade using caudally oriented branches. For RFs, mesenteric arteries have a significant increase in PSV in the first 6 months, which then stabilizes until year 5 (**Table 2**). For RFs in renal arteries, we found a significant increase from 6-8 weeks to 6 months, which remained stable until year 4, followed by a significant increase in year 5 (**Table 3**). Importantly, even though there are slight statistical differences between type of incorporation, these

were not considered clinically relevant with mean PSVs still below the thresholds of clinically significant stenosis when the criteria for native non-stented vessels are used (**Fig 2**, **Fig 3**). These results add to the findings of our prior report which compared preoperative and early postoperative (6-8 weeks) measurements. In that study, DBs had a significant decrease in PSV and RFs showed a significant increase in PSV in most target vessel segments.[10] According to our long-term findings in DBs, the initial decrease stabilizes after 6-8 weeks until year 4, with a small increase in year 5, although not significant. This descriptive trend could serve as a reference during follow-up, where deviations from this baseline pattern may indicate lesions that merit further imaging or reintervention. However, these findings are based on retrospective data and should be validation in larger prospective studies. We have also confirmed the velocity differences between DBs and RFs by comparing fenestrated mesenteric arteries, which are all incorporated by BESGs, and the subset group of DB with BESG, excluding any possible variation related to different stent grafts. In RFs, the PSV values were higher at every time interval compared to DBs incorporated by BESGs. We can conclude that the elevated velocities in RFs are not related only to the stent type, but rather the general anatomical differences between the two types of target artery incorporation is the major factor in velocity differences.

In general, DBs use longer bridging stent grafts sized to the diameter of the vessel (e.g., 6-10 mm). This effectively lengthens the bridging stent; as such, the overall resistance of the vessel itself increases. According to Poiseuille's law, the longer the length of the channel, the greater the resistance, and thus less flow overall, which, all things being equal, would result in reduced velocities.[18] This is especially evident in comparison to fenestrations, where the stent grafts are usually shorter in length. Tran and colleagues conducted a computational fluid analysis study, which revealed an increase in peak aortic pressures after FEVAR, measured at the aortic inlet. They postulate that this alteration is likely a consequence of the considerable reduction in aortic diameter after the endovascular repair, resulting in an overall increase in resistance.[19]

In another study by Tran et al., it was consistently noted that antegrade branches placed into renal arteries with an upward orientation experienced a significant decline in branch perfusion as compared to their preoperative values (estimated peak pressure and flow rate). The researchers suggest that this phenomenon is likely caused by the flow being forced down to travel through an extended stent graft with an upward trajectory, resulting in an overall reduction in flow rate compared to the preoperative measurements.[20] In our study, not only renal but also mesenteric arteries showed a significant decrease in PSV in the first 6-8 weeks.

We performed a subanalysis on differences in BESGs and SESGs since these types of stents are two distinctly different devices that may affect measured velocities. Since all fenestrated target vessels had BESGs, we only included branched target vessels in our analysis. For mesenteric vessels, BESGs and SESGs seemed to have a significant effect on the PSV measurements (p=.011). Although both BESGs and SESGs showed an initial decrease in PSV from baseline to 6–8 weeks, BESGs exhibited a greater increase by 6 months (132±46 to 143±47 cm/s) compared to SESGs (119±38 to 126±41cm/s). Over time, PSV in BESGs continued to increase, reaching 198 cm/s by year 5, whereas SESGs demonstrated only modest fluctuations, remaining consistently lower, with a maximum of 136±42 cm/s at year 5. In the renal arteries, no significant differences were observed between BESGs and SESGs overall (p=.78). However, a notable difference was that SESGs showed a significant decrease in PSV from baseline to 6–8 weeks (124±61 cm/s to 88±47 cm/s, p<.001), whereas the decrease in BESGs over the same period was not significant (124±96 cm/s to 99±41 cm/s, p=.32). This is likely due to the low numbers of branched renal arteries, as most renal arteries were incorporated with RFs (N=72 v N=439). The fact that in mesenteric arteries, the BESGs have higher PSV than SESGs could be attributed to the fact that BESGs have a higher radial force compared to SESGs, which are more flexible.[21]

Finally, we reported PSV measurements at the time of secondary interventions for stenosis in mesenteric (SMAs) and renal arteries. A limitation of this analysis is the small sample. It should be noted that of the 31 vessels requiring a secondary intervention, 11 underwent intraoperative relining with additional covered stents, which may have contributed to an increased risk of restenosis, due to additional stent layers and potential flow disturbance. The median PSV for SMA (N=3) was 350 cm/s ([IQR], 122 to 388 cm/s), exceeding the stenosis threshold for native and non-stented vessels (275 cm/s). One of the patients had a velocity below the threshold (122 cm/s), and intervention was indicated based on CTA findings of thrombus at the distal end of the stent. In retrospective analysis at the point of the thrombus, ultrasound measurements were not obtained, and this was a false negative result. The maximum PSV resulted in this case in an underestimation. The median for the renal arteries was 308 cm/s [IQR, 239 to 405 cm/s]), which is above the threshold of stenosis for native and non-stented vessels (200 cm/s). There were three renal arteries with "normal" velocities (122 cm/s, 181 cm/s and 123 cm/s), however based on CTA findings they all had high-grade stenosis. Due to the very small number of patients with reintervention of the mesenteric arteries, comparison between DBs and RFs is limited. Directional branches had lower median PSV for renal arteries (276 v 318 cm/s) as compared to RFs. The decision for secondary

interventions was based on both DUS and CTA findings. Of the 24 vessels with a secondary intervention analyzed, 20 vessels (83%) had velocities above the threshold of stenosis for native and non-stented vessels (>200/275 cm/s).[11-13] When applying DUS criteria for SMA in chronic mesenteric ischemia (CMI), where the threshold for in-stent restenosis is ≥445 cm/s, none of these 3 SMAs with in-stent stenosis would have met this criterion (with PSVs of 388, 350 and 122 cm/s).[22] This finding highlights the importance of being cautious about extrapolating threshold between patients with atherosclerotic disease and FB-EVAR stenting due to differences in pathophysiology of the underlying abnormality.

The observation that, at some point during follow-up, maximum velocities were above 200 and 275 cm/s in 66 CAs, 36 SMAs, and 38 RAs, without requiring secondary interventions, supports the evidence that only a single PSV threshold based on native vessel criteria should not be the sole reason for secondary intervention. This is further demonstrated by reinterventions in patients with borderline or normal velocity and the wide range of velocities observed in both mesenteric and renal arteries, independent of the method used for incorporation or the type of bridging stent. When in the context of DUS criteria for SMA in CMI, were the threshold for in-stent restenosis is ≥445 cm/s, there would have been no SMAs with velocities above the threshold. And for CAs, where the threshold was ≥289 cm/s, we would have identified 21 CAs.[22] In our experience, the role of ultrasound is to prompt careful evaluation of the CTA to guide decision to intervene keeping in mind that velocities should be considerably high to be the sole reason and normal velocities do not exclude the need for reintervention.

The present study strengths include its prospective design, the relatively large number of patients, and the execution of a standardized protocol by experienced sonographers and dedicated RVTs in a single institution. However, there are several limitations to acknowledge. Firstly, the focus was placed on PSV measurements, reflecting the clinical practice, while other possible relevant parameters like renal to aortic ratios and resistive indices were not collected.[11] Future research should be conducted to investigate these parameters specifically after FB-EVAR. We have chosen to include in the analysis only arterial segments that would be affected by the presence of the newly placed stent, whether directly (origin and proximal) or indirect velocity jet (mid), so we excluded the distal segments of the target vessels in our analysis, as additional factors such as vessel tapering and branching may account for higher velocities and could be a confounding factor. Another limitation worth mentioning is that we did not examine the effect of tortuosity, angulation, vessel diameter, stent size or stent length, despite the potential for these factors to influence the PSV values. Additionally, analysis of patients with

one or multiple stents was not performed due to the small size of the population with multiple stents. Even though we reported a threshold for stenosis requiring reintervention in renal arteries, our cohort consisted of only 20 vessels, limiting the value of this threshold and obviating the need for future studies. The small number of patients who underwent secondary intervention for mesenteric vessels limits the ability to define velocity criteria for reintervention. Our study was not designed to identify velocity criteria for reinterventions. This was a descriptive study that did not consider non-intervention cases. Moreover, the comparison between RFs and DBs may be influenced by differences in aneurysm extent (juxtarenal vs. TAAA), as these typically correspond to graft designs and anatomical configurations. Finally, the study population gradually decreased in size due to patients being lost to follow-up, while others were added to the timeline, but did not complete all the time marks.

Conclusion

This longitudinal study demonstrated distinct hemodynamic behaviors between RFs and DBs in both mesenteric and renal arteries. In mesenteric arteries, RFs showed a significant increase in PSV within the first six months, followed by minor, non-significant variations. DBs demonstrated an early decline in PSV, with subsequent variations remaining below baseline velocities prior to stent placement. Overall, PSV values for RFs were significantly higher than those for DBs.

In renal arteries, RFs showed an initial increase at six months, followed by a plateau and another significant rise at five years. DBs demonstrated an early PSV decline, followed by small non-significant variations, consistently remaining below pre-stent baseline velocities. Similar to mesenteric arteries, RF velocities were higher than DB velocities in renal arteries. Importantly, despite PSV variations over five-year follow-up, velocities remained below established thresholds for significant stenosis in native non-stented vessels.

Additionally, in mesenteric arteries, BESGs had higher PSV values over time than SESGs, whereas in renal arteries, the difference between BESGs and SESGs was not statistically significant. Finally, we have reported PSVs pertaining to stenosis requiring secondary intervention in renal-mesenteric arteries. While the majority of vessels with secondary interventions had velocities above the stenosis threshold, the wide range of velocities observed in both mesenteric and renal arteries, some of which exceeded thresholds without requiring intervention, suggests that a single PSV threshold should not be the sole criterion for reintervention.

These findings suggested that the type of incorporation and stent selection should be considered in postoperative surveillance and intervention decisions. The reported PSV measurements served as a benchmark for DUS surveillance following FB-EVAR.

References

1. Greenberg RK, Haulon S, Lyden SP, Srivastava SD, Turc A, Eagleton MJ, et al. Endovascular management of juxtarenal aneurysms with fenestrated endovascular grafting. J Vasc Surg. 2004;39:279-87.
2. Chuter TA. Branched and fenestrated stent grafts for endovascular repair of thoracic aortic aneurysms. J Vasc Surg. 2006;43 Suppl A:111A-5A.
3. Oderich GS, Ribeiro M, Hofer J, Wigham J, Cha S, Chini J, et al. Prospective, nonrandomized study to evaluate endovascular repair of pararenal and thoracoabdominal aortic aneurysms using fenestrated-branched endografts based on supraceliac sealing zones. J Vasc Surg. 2017;65:1249-59 e10.
4. Dossabhoy SS, Simons JP, Diamond KR, Flahive JM, Aiello FA, Arous EJ, et al. Reinterventions after fenestrated or branched endovascular aortic aneurysm repair. J Vasc Surg. 2018;68:669-81.
5. Tenorio ER, Schanzer A, Timaran CH, Schneider DB, Mendes BC, Eagleton MJ, et al. Effect of bridging stent graft selection for directional branches on target artery outcomes of fenestrated-branched endovascular aortic repair in the United States Aortic Research Consortium. J Vasc Surg. 2023; 78:10-28 e3.
6. Tran K, McFarland G, Sgroi M, Lee JT. Duplex ultrasound surveillance of renal branch grafts after fenestrated endovascular aneurysm repair. J Vasc Surg. 2019;70:1048-55.
7. Zierler RE. Duplex ultrasound follow-up after fenestrated and branched endovascular aneurysm repair (FEVAR and BEVAR). Semin Vasc Surg. 2020;33:60-4.
8. Karthikesalingam A, Al-Jundi W, Jackson D, Boyle JR, Beard JD, Holt PJ, et al. Systematic review and meta-analysis of duplex ultrasonography, contrast-enhanced ultrasonography or computed tomography for surveillance after endovascular aneurysm repair. Br J Surg. 2012;99:1514-23.
9. Wilmink AB, Forshaw M, Quick CR, Hubbard CS, Day NE. Accuracy of serial screening for abdominal aortic aneurysms by ultrasound. J Med Screen. 2002;9:125-7.
10. Sulzer TAL, Macedo TA, Strissel N, Hesley GK, Lekah A, Tallarita T, et al. Changes in Renal-Mesenteric Duplex Ultrasound Velocities after Fenestrated and Branched Endovascular Aortic Aneurysm Repair. J Vasc Surg. 2023;78(5):1162-9 e2.
11. Olin JW, Piedmonte MR, Young JR, DeAnna S, Grubb M, Childs MB. The utility of duplex ultrasound scanning of the renal arteries for diagnosing significant renal artery stenosis. Ann Intern Med. 1995;122:833-8.
12. Hoffmann U, Edwards JM, Carter S, Goldman ML, Harley JD, Zaccardi MJ, et al. Role of duplex scanning for the detection of atherosclerotic renal artery disease. Kidney Int. 1991;39:1232-9.
13. Moneta GL, Yeager RA, Dalman R, Antonovic R, Hall LD, Porter JM. Duplex ultrasound criteria for diagnosis of splanchnic artery stenosis or occlusion. J Vasc Surg. 1991;14:511-8; discussion 8-20.
14. von Elm E, Altman DG, Egger M, Pocock SJ, Gotzsche PC, Vandenbroucke JP, et al. The Strengthening the Reporting of Observational Studies in Epidemiology (STROBE) statement: guidelines for reporting observational studies. J Clin Epidemiol. 2008;61:344-9.
15. Oderich GS, Forbes TL, Chaer R, Davies MG, Lindsay TF, Mastracci T, et al. Reporting standards for endovascular aortic repair of aneurysms involving the renal-mesenteric arteries. J Vasc Surg. 2021; 73:4S-52S.
16. Oderich G. Endovascular Aortic Repair; current Techniques with Fenestrated, Branched and Parallel Stent-Grafts. Cham, Switserland: Springer Nature; 2017. 757 p.
17. Cleveland WS. Robust Locally Weighted Regression and Smoothing Scatterplots. J Am Statistic Assoc., 1979;74(368):829-36.
18. Pfitzner J. Poiseuille and his law. Anaesthesia. 1976;31:273-5.
19. Tran K, Yang W, Marsden A, Lee JT, Stanford C. Patient-specific computational flow modelling for assessing hemodynamic changes following fenestrated endovascular aneurysm repair. JVS Vasc Sci. 2021;2:53-69.
20. Kenneth Tran, Sebastien DeGlise, Celine Deslarzes-Dubuis, Adrien Kaladji, Weiguang Yang, Alison Marsden, et al. Patient-Specific Computational Flow Simulation Reveals Significant Differences in Paravisceral Aortic Hemodynamics Between Fenestrated and Branched Endovascular Aneurysm Repair. JVS Vasc Sci. 2023;5:100183.
21. Tenorio ER, Karkkainen JM, Mendes BC, DeMartino RR, Macedo TA, Diderrich A, et al. Outcomes of directional branches using self-expandable or balloon-expandable stent grafts during endovascular repair of thoracoabdominal aortic aneurysms. J Vasc Surg. 2020;71:1489-502 e6.

22. Soult MC, Wuamett JC, Ahanchi SS, Stout CL, Larion S, Panneton JM. Duplex ultrasound criteria for in-stent restenosis of mesenteric arteries. J Vasc Surg. 2016;64:1366-72.

Part IV

Optimizing Mid-Term Outcomes; The Role of Family History and Proximal Sealing Strategies



Chapter 10

Effect of Family History of Aortic Disease on Outcomes of Fenestrated and Branched Endovascular Aneurysm Repair of Complex Aortic Aneurysms

Titia A.L. Sulzer[1], Thomas Mesnard[1], Andres Schanzer[2], Carlos H. Timaran[3], Darren B. Schneider[4], Mark A. Farber[5], Adam W. Beck[6], Ying Huang[1], Gustavo S. Oderich[1], on behalf of the United States Aortic Research Consortium*

[1] Department of Cardiothoracic & Vascular Surgery, Advanced Aortic Research Program at the University of Texas Health Science Center at Houston, McGovern Medical School, Houston, TX.
[2] Division of Vascular and Endovascular Surgery, University of Massachusetts Medical School, Worcester, MA.
[3] Division of Vascular and Endovascular Surgery, University of Texas Southwestern, Dallas, TX.
[4] Division of Vascular Surgery and Endovascular Therapy, University of Pennsylvania, Philadelphia, PA.
[5] Division of Vascular Surgery, University of North Carolina, Chapel Hill, NC.
[6] Division of Vascular Surgery and Endovascular Therapy, University of Alabama at Birmingham, Birmingham, AL.

Collaborators of the United States Aortic Research Consortium:

Matthew J. Eagleton[7], F Ezequiel Parodi[5], Warren J. Gasper[8], Matthew P. Sweet[9], Sara L. Zettervall[9], W. Anthony Lee[10], Bernardo C. Mendes[11], Hence J.M. Verhagen[12]

[7] Division of Vascular and Endovascular Surgery, Massachusetts General Hospital, Boston, MA.
[8] Division of Vascular and Endovascular Surgery, University of California San Francisco, San Francisco CA.
[9] Division of Vascular Surgery, University of Washington, Seattle, WA.
[10] Division of Vascular Surgery, University of Florida, Boca Raton, FL.
[11] Division of Vascular and Endovascular, Mayo Clinic, Rochester, MN.
[12] Department of Vascular Surgery, Erasmus University Medical Center, Rotterdam, the Netherlands.

This study was presented at the Prize Session of the European Society for Vascular Surgery Annual Meeting (Belfast, Northern Ireland, September 2023).

European Journal of Vascular and Endovascular Surgery, Volume 68, Issue 6, December 2024, pages 712-718
DOI: 10.1016/j.ejvs.2024.05.011

Abstract

Objective: The clinical significance of family history (FH) of aortic disease on the outcomes of fenestrated-branched endovascular aneurysm repair (FB-EVAR) has not been well described. This study aimed to assess how family history of aortic disease affects outcomes following FB-EVAR for CAAs.

Methods: We retrospectively reviewed the clinical data of consecutive patients enrolled in ten ongoing prospective, nonrandomized, physician-sponsored investigational device exemption studies to evaluate FB-EVAR (2005-2022) in the United States Aortic Research Consortium (US-ARC) database. Patients were stratified by presence or absence of FH of any aortic disease in any relative. Patients with confirmed genetically triggered aortic diseases (GTAD) were excluded. Primary outcomes were 30-day major adverse events (MAEs) and late survival. Secondary outcomes included late secondary interventions and aneurysm sac enlargement.

Results: During the study period, 2,901 patients underwent FB-EVAR; 2,355 (81%) patients, 427 (18%) with and 1,928 (82%) without FH of aortic disease, were included in final analysis. Patient demographics, clinical characteristics, and aneurysm extent were similar between groups. Patients with FH of aortic disease more frequently had prior open abdominal aortic repair, but less frequently had prior endovascular aneurysm repair ($p<.05$). There were no significant differences in 30-day mortality (4% vs. 2%, $p=.12$) and MAEs for patients with or without FH of aortic disease (12% vs. 12%, $p=.89$). Three-year survival estimates were 71% (95% confidence interval [CI], 0.67-0.78%) and 71% (95% CI, 0.68-0.74%), respectively ($p=.74$). Freedom from secondary intervention and aneurysm sac enlargement were also not significantly different between groups.

Conclusion: Family history of aortic disease has no impact on 30-day and mid-term outcomes of FB-EVAR of CAAs. In the absence of an identified GTAD, treatment selection for CAAs should be based on clinical risk and patient anatomy, rather than FH of aortic disease.

Introduction

Family history of aortic disease, which is commonly defined as the existence of any first-degree relative with a history of aortic aneurysm or dissection, is recognized as a risk factor for aortic disease and affects up to 25% of patients with abdominal aortic aneurysms (AAAs).[1-5] In the recent guidelines of the American Heart Association, these patients have been classified as non-syndromic heritable aortic disease with no identifiable genetic cause, which is typically inherited as autosomal dominant, with more penetrance and earlier age in men than women.[6] Previous studies have demonstrated that patients with FH or aortic disease have worse 30-day and mid-term outcomes after standard endovascular aneurysm repair (EVAR) as compared to those without FH of aortic disease.[2, 7, 8] The underlying mechanisms involved in the increased adverse events are not fully understood, but it has been speculated that these are affected by adverse anatomy or risk of disease progression. It is possible that that patients with positive FH may have unknown, inherited connective tissue disorders.[2] This controversial assumption would imply major clinical implications as genetically triggered aortic aneurysms are known to be associated with increased risk of having secondary interventions after endovascular aortic repair.[9, 10] In contrast, the Vascular Quality Initiative (VQI) data did not reveal significant differences in 30-day mortality and complications after EVAR in patients with and without FH of aortic disease.[11]

While outcomes after EVAR in patients with or without FH of aortic disease are conflicting in the literature, there is paucity of data on its effect on outcomes after fenestrated and branched endovascular aneurysm repair (FB-EVAR) for treatment of complex aortic aneurysms (CAA).[6, 12] The United States Aortic Research Consortium (US-ARC) is a multicenter research collaboration resulting in the most extensive database containing FB-EVAR patients collected to date. All patients are treated in the context of ongoing prospective, nonrandomized, physician-sponsored investigational device exemption (PS-IDE) studies in the United States. Prior studies from the US-ARC have demonstrated the safety and effectiveness of FB-EVAR in octogenarians and female patients, yet the impact of FH of aortic disease has not been previously explored.[13, 14] The aim of this study was to evaluate the clinical impact of FH of aortic disease on 30-day and mid-term outcomes after FB-EVAR for the treatment of CAAs.

Methods

Study population

Consecutive patients enrolled in ten ongoing prospective, nonrandomized PS-IDE studies between July 1, 2005 and December 31, 2022 to evaluate FB-EVAR, were retrospectively reviewed in the US-ARC database. The study was approved by the Institutional Review Boards of each participating institution with a data-sharing agreement (IRB number: HSC-MS-21-0143). Follow-up ended in January 2023. All patients consented to the use of data upon initial inclusion in the research study. Moreover, the present study followed the relevant STROBE guidelines (Strengthening the Reporting of Observational Studies in Epidemiology).[15] We excluded patients with confirmed genetically triggered aortic diseases, which have been classified in the AHA guidelines as syndromic heritable aortic diseases with identifiable genetic causes (e.g. Marfans, Loeys-Dietz or other syndromes).[6] Patients were classified as those with or without FH of aortic disease, defined by the presence of aortic disease in any relative. This was based on a preoperative medical interview with the question: 'Any familial history of aortic disease?' With response options: 'No', 'Yes' or 'Unknown'. We excluded patients with missing or unknown FH of aortic disease.

Demographics, clinical, and anatomical information were prospectively collected in case report forms at each site and entered into a shared electronic data system. Aneurysm extent was determined based on the location of abnormal aortic segments as observed on preprocedural computed tomography angiography (CTA). Follow-up protocols were consistent across all PS-IDE sites and involved clinical examination, laboratory tests, and imaging studies at 1, 6, and 12 months, and annually thereafter. Imaging assessments included CTA or computed tomography without contrast and duplex ultrasound of the renal-mesenteric arteries. Cause of death was determined by review of death certificates or autopsy reports or adjudicated by the site principal investigator (PI). Adverse events were reviewed and evaluated independently at each institution. Finally, the follow-up index (FUI) was calculated for each patient as follow-up completeness at the study end date as the ratio between the actual and potential follow-up period.[16]

Device design and procedural details

The decision on specific device used was made based on aneurysm extent, vessel angulation, and inner aortic diameter at the origin of each target renal-mesenteric artery on preprocedural CTA, at the discretion of the site PI. Device design options were similar in all ten PS-IDE studies and included devices with nitinol-reinforced fenestrations

and/or directional branches manufactured by Cook Medical Inc. (Brisbane, Australia). Procedural steps of FB-EVAR have been described in detail previously.[17]

Study outcomes

The Society for Vascular Surgery reporting standards for endovascular aortic repair involving the renal and mesenteric vessels were used to define outcomes of interest.[18] Data was analyzed in patients with or without FH of aortic disease. Primary outcomes were 30-day major adverse events (MAE) and late patient survival. Secondary outcomes included late secondary interventions, and aneurysm sac enlargement which was defined as sac diameter increases of >5 mm on follow-up imaging study as compared to the baseline size. A subanalysis stratifying patients with a positive FH by those with or without prior thoracic endo-vascular aneurysm repair (TEVAR) was also performed.

Statistical analysis

The expression of normally distributed variables was in terms of mean ± standard deviation (SD), while non-normally distributed variables were presented as median (interquartile range [IQR]). Categorical variables were reported as number (percentage). For differences in 30-day outcomes between the groups, categorical variables were evaluated using the Pearson chi-square test or Fisher exact test, while continuous variables were analyzed using the Student's t-test or Mann-Whitney U test. Logistic regression analysis was performed to calculate the odds ratios (ORs) and corresponding 95% confidence intervals (CI). Time-dependent outcomes were analyzed using the Kaplan-Meier method and compared using univariable cox-regression analysis. Hazard ratio (HR) and 95% CIs were used to report the results. A *p*-value of less than .05 was considered statistically significant. All the analyses were performed using R version 4.0.3 (R Foundation for Statistical Computing, Vienna, Austria).

Results

Patients

There were 2,901 patients treated by FB-EVAR for CAAs during the study period. A total of 546 patients were excluded from the analysis; N=27 due to genetically triggered aortic disease, N=395 due to unknown status of FH of aortic disease, and N=124 due to missing essential data for analysis. A total of 2,355 (80%) patients were included in the final analysis; 1,641 patients (70%) were men and 714 (30%) were women. The mean age was 74±7.9 years-old. There were 788 (34%) complex abdominal aortic aneurysms (CAAAs) and 1,567 (66%) thoracoabdominal aortic aneurysms (TAAAs). The mean

maximum aortic diameter was 65±22 mm. Family history of aortic disease was present in 427 patients (18%) and absent in 1,928 patients (82%). Patients with FH of aortic disease were more likely to be females (34% vs. 29%, *p*=.025) and were younger (73±8 vs. 74±8, *p*=.039); these patients more often had prior open AAA repair (17% vs. 10%, *p*<.001), but less frequently had prior EVAR (14% vs. 20%, *p*=.025) compared to those without FH of aortic disease (**Table 1**). However, comparing the number of previous AAA repairs (EVAR and open repair) for patients with and without family history, there was no statistical difference.

Table 1. Demographics, clinical and anatomical characteristics of 2,355 patients treated by fenestrated and branched endovascular aneurysm repair (FB-EVAR) stratified by family history (FH) of aortic disease

	Overall N=2,355	No FH N=1,928	FH N=427	*p*-value
Age at procedure, years	73.7±7.9	73.8±7.9	72.9±7.9	**.039**
Male sex	1,641 (70)	1,361 (71)	280 (66)	**.025**
BMI, kg/cm^2	27.6±5.5	27.5±5.5	27.8±5.7	.39
Coronary artery disease	1,082 (47)	890 (47)	192 (45)	.53
Congestive heart failure	273 (13)	227 (12)	46 (11)	.56
Hypertension	2,127 (91)	1,743 (92)	384 (90)	.30
Hyperlipidemia	1,627 (79)	1,343 (79)	284 (81)	.49
Chronic pulmonary disease	833 (36)	683 (36)	150 (35)	.81
Diabetes mellitus	353 (16)	297 (16)	56 (13)	.21
Peripheral artery disease	433 (19)	355 (19)	78 (18)	.89
Dialysis	35 (1.5)	32 (1.7)	3 (0.7)	.20
Active cancer	75 (3.2)	64 (3.3)	11 (2.6)	.56
Current smoker	616 (27)	517 (27)	99 (23)	.16
Aneurysm extent				
CAAA	788 (34)	653 (34)	135 (32)	.40
Extent I-III TAAA	965 (41)	782 (41)	183 (43)	.41
Extent IV TAAA	602 (26)	493 (26)	109 (26)	1
History of aortic dissection	232 (10)	186 (9.8)	46 (11)	.59
Maximum aortic diameter, mm	65±22	65±24	64±10	.16
Presentation				.19
Asymptomatic	1,950 (95)	1,618 (95)	332 (94)	
Symptomatic	108 (5)	89 (4.3)	19 (0.9)	
Prior TEVAR	348 (21)	288 (21)	60 (20)	.78
Prior EVAR	314 (19)	272 (20)	42 (14)	**.025**
Prior open AAA repair	268 (11)	194 (10)	74 (17)	**<.001**

Data are presented as N (%) or mean±standard deviation, or median (interquartile range). *BMI*, body mass index; *CAAA*, complex abdominal aortic aneurysm; *TAAA*, thoracoabdominal aortic aneurysm; *TEVAR*, thoracic endovascular aneurysm repair; *EVAR*, endovascular aneurysm repair; *AAA*, abdominal aortic aneurysm.

Procedural data

Patient-specific devices were used in 1,977 (85%) patients, with no significant difference between groups. Patients with FH of aortic disease more frequently required open surgical conduits for the access (5% vs. 3%, *p*=.029). The use of directional branches was more frequent in patients with FH of aortic disease (41% vs. 35%, *p*=.007), whereas fenestrations were more often selected among patients without FH of aortic disease (62% vs. 56%, *p*=.001; **Table 2**).

Table 2. Stent graft design and procedural details for fenestrated and branched endovascular aneurysm repair (FB-EVAR) stratified by family history (FH) of aortic disease

	Overall N=2,355	No FH N=1,928	FH N=427	*p*-value
ASA classification ≥3	1,674 (88)	1,410 (88)	264 (90)	.086
Device design				.32
Custom-made device	1,977 (85)	1,627 (85)	350 (83)	
T-Branch	322 (14)	258 (14)	64 (15)	
P-Branch	35 (1.5)	26 (1.4)	9 (2.1)	
Staged TEVAR	387 (16)	316 (16)	71 (17)	.96
Spinal drain	664 (28)	515 (27)	149 (35)	**.001**
Access conduit				**.029**
Open conduit	57 (3.1)	40 (2.6)	17 (5.4)	
Endovascular conduit	26 (1.4)	21 (1.4)	5 (1.6)	
Neuromonitoring	1,090 (47)	903 (48)	187 (44)	.21
Number of target arteries incorporated per patient	3.7±0.8	3.7±0.8	3.7±0.7	.16
Number of target arteries incorporated	8,760	7,184	1,576	
Fenestration	5,340 (61)	4,455 (62)	885 (56)	**.007**
Directional branch	3,194 (36)	2,544 (35)	650 (41)	**.001**
Scallop	226 (2.6)	185 (2.6)	41 (2.6)	.98
Procedural time, min	249±114	247±111	257±125	.12
Technical success	2,231 (97)	1,823 (97)	408 (97)	1

Data are presented as N (%) or mean±standard deviation, or median (interquartile range). *ASA*, American society of anesthesiologists; *TEVAR*, thoracic endovascular aneurysm repair. Due to rounding, numbers may not add up.

30-day outcomes

A total of 274 patients (12%) had at least one MAE within 30-days of FB-EVAR, including 51 patients (12%) with and 223 patients (12%) without FH of aortic disease (OR: 1.03; 95% CI, 0.81-1.28; *p*=.89). The 30-day mortality rate was 4% (N=16) and 2% (N=44) in both groups, respectively, but the difference was not statistically significant (OR: 1.44; 95% CI, 0.93-2.13, *p*=.12; **Table 3**). Causes of deaths are specified in **Supplemental Table 1**. There was no significant difference in patients who died of aortic rupture or dissection after repair between groups (*p*<.05).

Table 3. Thirty-day outcomes following fenestrated and branched endovascular aneurysm repair (FB-EVAR) stratified by family history (FH) of aortic disease

	Overall N=2,355	No FH N=1,928	FH N=427	*p*-value
Major adverse events	274 (12)	223 (12)	51 (12)	.89
Mortality	60 (2.5)	44 (2.3)	16 (3.7)	.12
Acute kidney injury	114 (4.8)	91 (4.7)	23 (5.4)	.65
Respiratory failure	59 (2.5)	48 (2.5)	11 (2.6)	1
Paraplegia	58 (2.5)	44 (2.3)	14 (3.3)	.30
Myocardial infarction	42 (1.8)	33 (1.7)	9 (2.1)	.72
Stroke	34 (1.4)	28 (1.5)	6 (1.4)	1
Bowel ischemia	25 (1.1)	23 (1.2)	2 (0.5)	.29

Data are presented as N (%).

Mid-term outcomes

Median follow-up was 17 months (IQR, 5-41). The follow-up index (FUI) was 0.54±0.71. Of all 2,355 patients, 639 (27%) had ≥ three-years of follow-up, and 187 (8.1%) had ≥ five-years of follow-up. Furthermore, of 2,355 patients included, 2,291 patients had a clinical follow-up, and 2,272 had at least one follow-up with CTA or ultrasound. The overall patient survival estimate was 71% (95% CI, 69-74%) at 3-years and was comparable between patients with and without FH of aortic disease (HR, 0.98; 95% CI, 0.85-1.12; *p*=.74; **Fig 1A**). The overall freedom from secondary interventions at 3-years was 64% (95% CI, 62-67%) and was also similar between groups (HR, 0.94; 95% CI, 0.81-1.08; *p*=.38; **Fig 1B**). The overall freedom from aneurysm sac enlargement at 3 years was 77% (95% CI, 75-79%), and was slightly higher among patients with FH as compared to those without FH of aortic disease, but the difference was not statistically significant (HR, 0.85; 95% CI, 0.71-1.02; *p*=.089; **Fig 1C**).

Sub-analysis: positive family history and prior TEVAR

Of the 427 patients with FH of aortic disease, 14% (60/427) had a prior TEVAR. The risk of mortality was significantly lower for patients with prior TEVAR compared to those without (HR, 0.48; 95% CI, 0.25-0.96; *p*=.04). There was no significant difference in the risk of secondary interventions between patients with and without a prior TEVAR (HR, 0.92; 95% CI, 0.54-1.57; *p*=.76). Additionally, the risk of sac enlargement did not differ significantly between patients with and without a prior TEVAR (HR, 1.56; 95% CI, 0.86-2.82; *p*=.15).

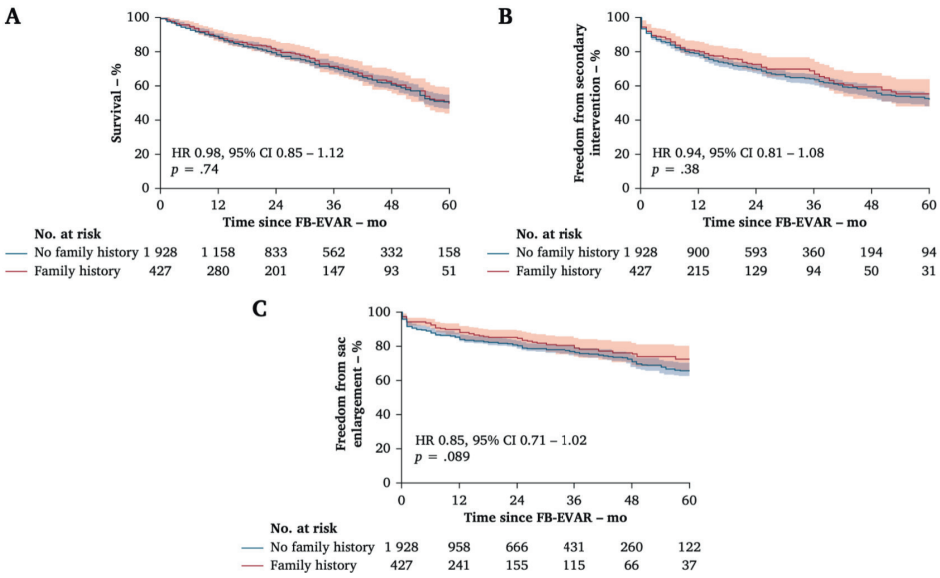

Fig 1. Kaplan-Meier curves for outcomes following fenestrated and branched endovascular aneurysm repair (FB-EVAR) stratified by family history (FH) of aortic disease demonstrating **(A)** Survival. **(B)** Freedom from secondary interventions. **(C)** Freedom from aneurysm sac enlargement.

Discussion

The present multicenter study of prospectively collected and adjudicated data using the US-ARC database focused on patients with or without FH of aortic disease who underwent FB-EVAR for treatment of CAAs. In this cohort the incidence of positive FH of aortic disease was 18%, which is nearly identical to prior reports.[6] We found that patients with FH of aortic disease were younger, more likely to be females, and more often had prior open AAA repairs compared to those without FH. This study found no difference in 30-day and mid-term outcomes with respect to MAEs, all-cause mortality, secondary interventions, and aneurysm sac enlargement between patients with FH of aortic disease and sporadic aneurysms.

The main controversy regarding FH of aortic disease is its potentially detrimental impact on outcomes of endovascular repair, which is supported by three previous reports dealing with EVAR.[2, 7, 8] All of these studies assumed that the underlying existence of inherited connective tissue disorder in FH patients would confer a constitutional aortic wall weakness leading to the aneurysmal dilation of the aorta at a younger age with more extensive disease or more predisposition to disease progression, conferring a higher risk of secondary interventions over time. Nevertheless, the VQI data challenged this theory by the observation that patients with FH of aortic disease did not have

higher incidence of reintervention after EVAR compared to those without. Currently, there are at least 11 genes with confirmed risk of aortic dissection or aneurysms. Recommendations of the recent AHA guidelines have been revised to include genetic testing in all patients with syndromic features, age of presentation <60 years-old, FH of aortic aneurysms or dissections, intra-cranial or peripheral aneurysms in first degree relatives, or history of sudden death at young age in first or second-degree relatives.[6] A criticism to these studies, including ours, is that these recommendations are not always followed and most of the patients (with or without FH of aortic disease) have not been routinely tested for genetic mutations.

The present study outlined an incidence of positive FH of 18% among 2,355 patients who underwent FB-EVAR of CAAs. This finding is similar to the proportion of 20-25% and 22% previously reported among patients with AAAs and thoracic aortic aneurysms (TAA) using standardized questionnaires.[2, 4, 7] While these studies defined FH of aortic disease in terms of first-degree relatives, we used a broader definition based on the occurrence of any relative with aortic disease. We excluded patients with connective tissue disorders because these patients represent a minority with unique identified genetic mutations that have been shown to portend higher risk of complications and secondary interventions with any endovascular repair.[19] Therefore, we aimed to create a more homogeneous study cohort by excluding this higher risk category focusing only on the non-syndromic heritable aortic diseases without identifiable genetic causes.

It is known that patients with FH of aortic disease require aortic repair at a younger age as compared to patients without FH.[3, 11, 20, 21] Our results align with these observations, and the age difference can be explained by the fact that individuals with FH of aortic disease have increased awareness and may be screened or seek medical attention sooner than those without FH. In line with previous reports, we found a higher proportion of females in patients with FH of aortic disease than those without (34% vs. 29%, p=.025).[1, 11, 20] It could be assumed that inherited risk may play a more prominent role in the development of aneurysmal disease in female patients, due to their low likelihood of presenting cardiovascular risk factors.[22] However, this result is not in line with the AHA guidelines, reporting that penetrance is higher in men than woman.[6] Regarding anatomical features, Brown and colleagues reported a greater incidence of chronic aortic dissection and more extensive aneurysms among patients with positive FH.[3, 6] In contradiction, we observed comparable rates of chronic dissections and there was no significant difference in aneurysm extent in both groups, which suggests that FH may not affect the disease presentation. Additionally, there was no difference in previous AAA repair between patients with and without FH (31% vs. 30%). However, FH patients

more often had prior open AAA repair (17% vs. 10%, $p<.001$) and less frequently had prior EVAR (14% vs. 20%, $p=.025$). This indicates a preference for open AAA repair among patients with a family history.

In the present study, FH of aortic disease had no effect on 30-day mortality compared to sporadic CAA patients. This contrasts to the findings of the Rotterdam Group, which identified increased 30-day mortality (adjusted HR 5.7) among patients with FH of aortic disease in a cohort of 1,262 EVAR patients enrolled in an industry sponsored registry.[8] In that study, among four early deaths in patients with FH of aortic disease, one was attributed to potential constitutional aortic wall weakness in a patient who died of ruptured thoracic aortic aneurysm.[8] In the present study, perioperative aortic aneurysm rupture or retrograde dissection leading to death were uncommon, and they might not have been influenced by a FH of aortic disease. Additionally, we did not observe discernible differences in early MAEs between two groups, although it has been reported that patients with FH have more MAEs after EVAR, despite the lack of substantial evidence supporting a direct relationship with FH.[8, 11]

In addition to comparable risk of early mortality and morbidity, our results also demonstrated that there was no difference in mid-term outcomes regarding all-cause mortality, secondary intervention, and aneurysm sac enlargement. The study of van de Luijtgaarden and associates reported a two-fold increased risk of having composite secondary intervention, aneurysm growth, non-type II endoleak, limb thrombosis and aneurysm rupture after EVAR among 51 FH patients compared to 204 patients without FH.[2] Additionally, a group from the United States analyzed 392 patients who underwent EVAR and pointed out that FH patients were more likely to require a secondary intervention.[7] Length of follow-up was superior in both studies (40 and 54 months, respectively). Our findings are different from those reports, which is very likely due to the limited follow-up (17 months), the fact that our inclusion for FH was wider and perhaps the hereditary component thus weaker, and finally the circumstance wherein our study cohort consists of FB-EVAR patients. Beyond these disparities, the Rotterdam group hypothesized that patients with positive family history of aortic disease may have an underlying inherited aortic wall weakness, leading to more sac growth and a higher need for secondary intervention. If such intrinsic aortic wall defect is present in patients with family history, we would anticipate observing similar trends in our results.

Nevertheless, we observed a trend of increased aneurysm sac growth in patients with no FH of aortic disease (23% vs. 21% at 3 years, $p=.089$). This association has been confirmed in previous reports in the settings of standard EVAR.[2, 4, 21]

In a subanalysis conducted in patients having a positive FH with and without prior TEVAR, we found a reduced risk of mortality in patients with previous TEVAR (HR, 0.48; 95% CI, 0.25-0.96; *p*=.04). One hypothesis could be that the increased coverage of the aorta during FB-EVAR contributes to greater durability. However, we do not see the same trend in the secondary interventions. Future research should explore this topic further.

In the present study, 30-day and mid-term outcomes after FB-EVAR were satisfactory for patients with FH of aortic disease. It can be argued that the increased experience with FB-EVAR had led to an augmented learning curve, resulting in favorable outcomes.[23] Furthermore, in the context of the findings, the participating centers in the US-ARC are all tertiary referring centers with high-volume and highly experienced operators and teams in planning and management.

The present study has a number of limitations. First, FH of aortic disease was recorded based on preoperative medical interview, this subgroup of patients may be underreported due to the absence of structured questionnaires. Because genetic testing was not routinely performed it is possible that some patients carried genetic mutations known to be associated with risk of aortic related events. Secondly, additional features of disease extent, such as aneurysm configuration, mural thrombus, arterial calcifications, aorto-iliac tortuosity, and other site aneurysms were not captured as part of the prospective database and could be different between groups. Lastly, although we used prospectively collected data, follow-up information might be incomplete due to a significant number of patients being lost to follow-up, thereby increasing the likelihood of type II errors.

Conclusion

Family history of aneurysm in the absence of a known genetically triggered aortic disease affected 18% of patients who underwent FB-EVAR of CAAs. Although the presence of FH of aortic disease is a risk factor associated with increased incidence of aortic aneurysms, it had no impact on 30-day and mid-term outcomes with respect to MAEs, survival, secondary intervention, and aneurysm sac enlargement following FB-EVAR. These findings support the notion that in the absence of a genetically triggered aortic disease, treatment selection for CAAs (e.g. open surgical repair versus FB-EVAR) should be based on other factors such as clinical risk and anatomical suitability. Despite these findings, longer follow-up is certainly warranted to assess the durability of FB-EVAR in patients with FH of aortic disease.

References

1. Darling RC, 3rd, Brewster DC, Darling RC, LaMuraglia GM, Moncure AC, Cambria RP, et al. Are familial abdominal aortic aneurysms different? J Vasc Surg. 1989;10:39-43.
2. van de Luijtgaarden KM, Bastos Goncalves F, Hoeks SE, Majoor-Krakauer D, Rouwet EV, Stolker RJ, et al. Familial abdominal aortic aneurysm is associated with more complications after endovascular aneurysm repair. J Vasc Surg. 2014;59:275-82.
3. Brown CR, Greenberg RK, Wong S, Eagleton M, Mastracci T, Hernandez AV, et al. Family history of aortic disease predicts disease patterns and progression and is a significant influence on management strategies for patients and their relatives. J Vasc Surg. 2013;58:573-81.
4. Albornoz G, Coady MA, Roberts M, Davies RR, Tranquilli M, Rizzo JA, et al. Familial thoracic aortic aneurysms and dissections--incidence, modes of inheritance, and phenotypic patterns. Ann Thorac Surg. 2006;82:1400-5.
5. Larsson E, Granath F, Swedenborg J, Hultgren R. A population-based case-control study of the familial risk of abdominal aortic aneurysm. J Vasc Surg. 2009;49:47-50; discussion 1.
6. Isselbacher EM, Preventza O, Hamilton Black J, 3rd, Augoustides JG, Beck AW, Bolen MA, et al. 2022 ACC/AHA Guideline for the Diagnosis and Management of Aortic Disease: A Report of the American Heart Association/American College of Cardiology Joint Committee on Clinical Practice Guidelines. Circulation. 2022;146:e334-e482.
7. Ryer EJ, Garvin RP, Thomas B, Kuivaniemi H, Franklin DP, Elmore JR. Patients with familial abdominal aortic aneurysms are at increased risk for endoleak and secondary intervention following elective endovascular aneurysm repair. J Vasc Surg. 2015;62:1119-24 e9.
8. van de Luijtgaarden KM, Bastos Goncalves F, Hoeks SE, Blankensteijn JD, Bockler D, Stolker RJ, et al. Higher 30 Day Mortality in Patients with Familial Abdominal Aortic Aneurysm after EVAR. Eur J Vasc Endovasc Surg. 2017;54:142-9.
9. Waterman AL, Feezor RJ, Lee WA, Hess PJ, Beaver TM, Martin TD, et al. Endovascular treatment of acute and chronic aortic pathology in patients with Marfan syndrome. J Vasc Surg. 2012;55:1234-40; discussion 40-1.
10. Svensson LG, Kouchoukos NT, Miller DC, Bavaria JE, Coselli JS, Curi MA, et al. Expert consensus document on the treatment of descending thoracic aortic disease using endovascular stent-grafts. Ann Thorac Surg. 2008;85:S1-41.
11. Ryer EJ, Garvin RP, Zhou Y, Sun H, Pham A, Orlova K, et al. Outcomes of familial abdominal aortic aneurysm repair in the Vascular Quality Initiative. J Vasc Surg. 2019;69:717-27 e1.
12. Oderich GS, Farber MA, Schneider D, Makaroun M, Sanchez LA, Schanzer A, et al. Final 5-year results of the United States Zenith Fenestrated prospective multicenter study for juxtarenal abdominal aortic aneurysms. J Vasc Surg. 2021;73:1128-38 e2.
13. Motta F, Oderich GS, Tenorio ER, Schanzer A, Timaran CH, Schneider D, et al. Fenestrated-branched endovascular aortic repair is a safe and effective option for octogenarians in treating complex aortic aneurysm compared with nonoctogenarians. J Vasc Surg. 2021;74:353-62 e1.
14. Edman NI, Schanzer A, Crawford A, Oderich GS, Farber MA, Schneider DB, et al. Sex-related outcomes after fenestrated-branched endovascular aneurysm repair for thoracoabdominal aortic aneurysms in the U.S. Fenestrated and Branched Aortic Research Consortium. J Vasc Surg. 2021;74:861-70.
15. von Elm E, Altman DG, Egger M, Pocock SJ, Gotzsche PC, Vandenbroucke JP, et al. The Strengthening the Reporting of Observational Studies in Epidemiology (STROBE) statement: guidelines for reporting observational studies. J Clin Epidemiol. 2008;61:344-9.
16. von Allmen RS, Weiss S, Tevaearai HT, Kuemmerli C, Tinner C, Carrel TP, et al. Completeness of Follow-Up Determines Validity of Study Findings: Results of a Prospective Repeated Measures Cohort Study. PLoS One. 2015;10:e0140817.
17. Oderich G. Endovascular Aortic Repair; current Techniques with Fenestrated, Branched and Parallel Stent-Grafts. Cham, Switserland: Springer Nature; 2017. 757 p.
18. Oderich GS, Forbes TL, Chaer R, Davies MG, Lindsay TF, Mastracci T, et al. Reporting standards for endovascular aortic repair of aneurysms involving the renal-mesenteric arteries. J Vasc Surg. 2021; 73:4S-52S.
19. Olsson KW, Mani K, Burdess A, Patterson S, Scali ST, Kolbel T, et al. Outcomes After Endovascular Aortic Intervention in Patients With Connective Tissue Disease. JAMA Surg. 2023;158:832-9.

20. Powell JT, Greenhalgh RM. Multifactorial inheritance of abdominal aortic aneurysm. Eur J Vasc Surg. 1987;1:29-31.
21. Coady MA, Davies RR, Roberts M, Goldstein LJ, Rogalski MJ, Rizzo JA, et al. Familial patterns of thoracic aortic aneurysms. Arch Surg. 1999;134:361-7.
22. Walli-Attaei M, Joseph P, Rosengren A, Chow CK, Rangarajan S, Lear SA, et al. Variations between women and men in risk factors, treatments, cardiovascular disease incidence, and death in 27 high-income, middle-income, and low-income countries (PURE): a prospective cohort study. Lancet. 2020;396:97-109.
23. Mirza AK, Tenorio ER, Karkkainen JM, Hofer J, Macedo T, Cha S, et al. Learning curve of fenestrated and branched endovascular aortic repair for pararenal and thoracoabdominal aneurysms. J Vasc Surg. 2020;72:423-34 e1.

Supplemental Material

Supplementary Table 1. Causes of 30-day mortality in patients with and without a family history (FH) of aortic disease

	Overall N=2,355	No FH N=1,928	FH N=427	*p*-value
Overall	60 (2.5)	44 (2.3)	16 (3.7)	.12
Aortic rupture	3 (0.1)	2 (0.1)	1 (0.2)	
Retrograde dissection	7 (0.3)	5 (0.3)	2 (0.5)	
Cardiac related	11 (0.5)	11 (0.6)	0 (0)	
Bowel ischemia	7 (0.3)	5 (0.3)	2 (0.5)	
Respiratory	3 (0.1)	2 (0.1)	1 (0.2)	
Spinal cord ischemia	3 (0.1)	3 (0.2)	0 (0)	
Sepsis	2 (0.1)	1 (0.1)	1 (0.2)	
Stroke	2 (0.1)	2 (0.1)	0 (0)	
Intra-abdominal hemorrhage	2 (0.1)	2 (0.1)	0 (0)	
Complication of implantation procedure	5 (0.2)	2 (0.1)	3 (0.7)	
Multi organ failure	8 (0.3)	5 (0.3)	3 (0.7)	
Other	7 (0.3)	4 (0.2)	3 (0.7)	

Data are presented as N (%).



Chapter 11

Perioperative and Mid-Term Results of Supraceliac Versus Infraceliac Sealing for Fenestrated Endovascular Aortic Repair of Juxtarenal Aortic Aneurysms

Titia A.L. Sulzer[1], Jorg L. de Bruin[1], Vinamr Rastogi[1], Gert Jan Boer[2], Klaas H.J. Ultee[1,2], Bram Fioole[2], Gustavo S. Oderich[3], Marc L. Schermerhorn[4], Hence J.M. Verhagen[1]

[1] Department of Vascular Surgery, Erasmus University Medical Center, Rotterdam, the Netherlands.
[2] Department of Vascular Surgery, Maasstad Hospital Rotterdam, the Netherlands. Division of Vascular and Endovascular Surgery, Mayo Clinic, Rochester, MN.
[3] Department of Cardiothoracic & Vascular Surgery, Advanced Aortic Research Program at the University of Texas Health Science Center at Houston, McGovern Medical School, Houston, TX.
[4] Beth Israel Deaconess Medical Center, Harvard Medical School, Boston, MA.

This study was presented at the Dutch Vascular Society Meeting (NVvV, najaarsvergadering, Ermelo, November 2024).

European Journal of Vascular and Endovascular Surgery, Volume 69, Issue 4, April 2025, pages 619-627
DOI: 10.1016/j.ejvs.2024.11.019

Abstract

Objective: Our aim was to investigate perioperative and mid-term outcomes, including sac dynamics, of fenestrated endovascular aneurysm repair (FEVAR) for juxtarenal abdominal aortic aneurysms (J-AAAs), comparing supraceliac sealing with infraceliac sealing. Supraceliac sealing may offer an advantage due to a longer proximal sealing zone, but it is associated with a more complex procedure and increased risk of complications. Furthermore, it is unknown whether supraceliac sealing actually leads to increased durability.

Methods: Patients undergoing elective FEVAR for J-AAAs from 2008-2021 at two hospitals in the Netherlands were included. The definition of supraceliac sealing was sealing in zone 5 or 6, with incorporation of the celiac axis. Infraceliac sealing was defined below zone 6. The primary endpoints included perioperative outcomes. Secondary endpoints included one-year aneurysm-sac dynamics, freedom from secondary intervention, five-year mortality, and sac dynamics over time.

Results: Among 167 patients, 78 (47%) had a proximal sealing at an infraceliac level, and 89 (53%) at a supraceliac level. Median proximal sealing length was 37 mm [interquartile range (IQR), 28-52] for the supraceliac group, and 26 mm [(IQR) 19-34] for the infraceliac group. Patients with supraceliac sealing more often had prior EVAR (31% vs.12%, p=.004). Type 3c endoleaks only occurred in patients with supraceliac sealing (6.7% vs. 0.0%, p=.03). Other perioperative complications and mortality were similar between the groups. Furthermore, no differences were found in one-year aneurysm-sac dynamics, freedom from secondary interventions, mortality at five-year, and sac-dynamics over time.

Conclusion: Proximal supraceliac and infraceliac sealing showed similar mid-term outcomes, including sac dynamics, despite supraceliac sealing's higher procedural complexity. Supraceliac sealing had a higher rate of 30-day type 3c endoleaks, but no differences in the five-year secondary intervention rate. Theoretically, supraceliac sealing may be advantageous as sealing zones dilate over time, though future studies with over five-year follow-up are needed to determine its impact on long-term aneurysm-sac exclusion.

Introduction

Endovascular aortic aneurysm repair (EVAR) has become the prevailing approach for the treatment of abdominal aortic aneurysms worldwide.[1,2] The introduction of fenestrated endovascular aortic repair (FEVAR) has expanded the range of endovascular procedures, allowing for effective treatment in patients with complex abdominal aortic aneurysms (C-AAAs), with durable outcomes.[3-6]

Early experiences with FEVAR involved the incorporation of one or two renal fenestrations and a scallop for the superior mesenteric artery (SMA) in patients with juxtarenal abdominal aortic aneurysms (J-AAAs).[5,7] Now, centers are opting to stent in a healthier and more proximal segment of the aorta. The strategy of sealing above the SMA and celiac axis (CA) would potentially reduce the risk of disease progression and moreover expand the durability of the repair.[8,9]

In addition, it has been demonstrated that proximal seal dilatation occurs not only after EVAR, but also after FEVAR, presumably more resistant to dilatation.[10,11] Although not much is known about long-term consequences of this seal dilatation in FEVAR, it might lead to clinical implications. If so, a longer sealing length could prove beneficial over time.

According to recent studies, supraceliac sealing in patients with J-AAAs, is associated with a lower risk of type 1a endoleaks and similar three-year mortality compared with sealing at an infraceliac level.[12] However, supraceliac sealing might also be associated with more perioperative complications such as spinal cord ischemia (SCI), acute limb ischemia, bowel ischemia, myocardial infarction, acute kidney injury (AKI), and 30-day mortality.[12-16] Given the limited available data on the influence of sealing zone on outcomes, the aim of our study was to evaluate perioperative and mid-term outcomes, including sac dynamics, comparing a supraceliac versus an infraceliac sealing zone in the treatment of J-AAAs.

Methods

Design and population

All consecutive patients undergoing FEVAR for J-AAAs between 2008 and 2021 at two large hospitals in the Netherlands (Erasmus University Medical Center, Rotterdam, and Maasstad Hospital, Rotterdam) were included in this retrospective cohort study. Clinical follow-up and imaging were captured until October 2023. This study complies with the Declaration of Helsinki in research ethics and was approved by the institutional and ethical review board of both hospitals (MEC-2022-0591 and L2018103).[17] Moreover, the present study followed the relevant STROBE guidelines (Strengthening the Reporting of Observational Studies in Epidemiology).[18] A part of this patient cohort has been previously described.[19, 20]

Data collection and definitions

Patients were stratified by their proximal landing zone: either at the supraceliac or infraceliac level. According to the reporting standards, supraceliac sealing was defined as proximal sealing in aortic zones 5 or zone 6 with incorporation of the celiac axis with a scallop, fenestration, or occlusion. Whereas infraceliac sealing was defined as sealing below zone 6 (**Fig 1**).[21] FEVAR has been used for complex abdominal aortic aneurysms where regular EVAR was not sufficient due to short-neck juxtarenal or pararenal abdominal aortic aneurysms. Anatomically, the patients in this study were candidates for both treatment options. The decision for either supraceliac or infraceliac sealing was at the discretion of the treating vascular surgeon. Patient demographics, comorbidities, and medication were assessed for both groups, following the reporting standards outlined by the Society for Vascular Surgery for complex abdominal aortic aneurysm repair.[22] Patients' demographics were retrospectively collected from the medical records. The American Society of Anesthesiologist (ASA) score was used to determine the overall health of the patients. To measure the proximal sealing length and distance from endograft to uppermost renal artery, all imaging was reviewed (by TALS and VR). For the purpose of this study, the outcome "freedom from secondary intervention" included the use of proximal cuff, limb extension, iliac percutaneous transluminal angioplasty (PTA), conversion to aorto-uni-iliac configuration (AUI), coiling, gluing, embolization, open or laparoscopic ligation of collateral, or other surgical intervention. "Mortality" was defined as all-cause mortality and was meticulously collected from regularly updated medical records. Perioperative mortality referred to death occurring within 30 days after index procedure. Major adverse events were defined based on the reporting standards.[22] The maximum perioperative aneurysm

diameter was measured in the axial view of the computed tomography angiography (CTA) at the location of maximum diameter of the aneurysm, within 30 days of the surgery. SCI was categorized based on the grading system of the reporting standards, including Grade 0 (No neurologic deficit); Grade 1 (Minimal sensory deficit); Grade 2 (Paraparesis); Grade 3 (Paraplegia).[22] When SCI was suspected, independent neurologists graded the severity. AKI was classified using the Kidney Guidelines Improving Global Outcomes (KDIGO) criteria and categorized into three grades: Grade 1 (Serum creatinine 1.5-1.9 times baseline or ≥0.3 mg/dl (≥26.5 μmol/l) increase; Grade 2 (Serum creatinine 2.0-2.9 times baseline); and Grade 3 (Serum creatinine 3 times baseline or ≥4.0 mg/dl (≥353.6 μmol/l).[23] To be included for the one-year aneurysm-sac dynamics, patients were required to have both 30-day CTA and one-year CTA. One-year CTAs were compared with 30-day CTAs for one-year aneurysm-sac dynamics, defined following: sac regression >5% volume decrease; stable sac <5% volume change; sac expansion >5% volume increase. For the aneurysm sac dynamics over time, all available follow-up CTA of the patients were used. All aneurysm sac measurements were obtained using image processing software (3 mensio Medical Imaging, Bilthoven, the Netherlands). Our group previously validated the measure methods of aneurysm volumes for both intra-and interobserver variability in infrarenal AAA.[24]

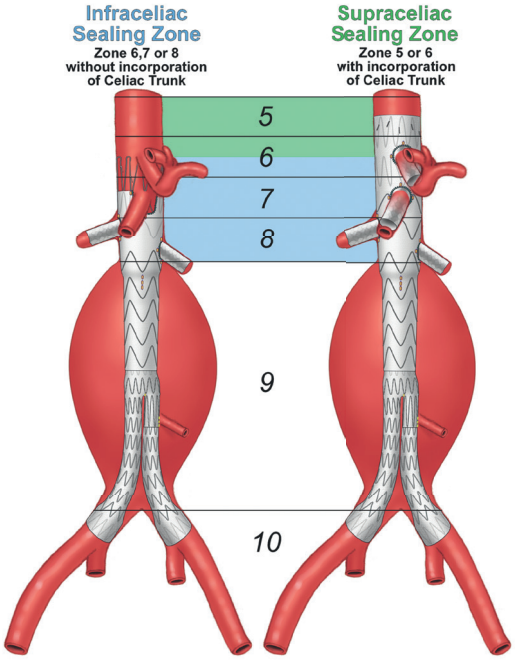

Fig 1. Definition of infraceliac and supraceliac proximal sealing zone based on the Society for Vascular Surgery (SVS) guidelines.

Endpoints

The primary endpoints were perioperative outcomes, including mortality, SCI, AKI, and endoleaks. Secondary endpoints included one-year aneurysm-sac dynamics, five-year freedom from secondary interventions, five-year freedom from mortality, and five-year sac dynamics over time.

Statistical analysis

Categorical variables were expressed as numbers (%) and compared using either Pearson's χ^2-test or Fisher's exact tests. Continuous variables were assessed for normal distribution using Q-Q plots, histograms, and the Shapiro-Wilk test. Normally distributed continuous variables were presented as mean ± standard deviation (SD), while non-normally distributed variables were presented as median with interquartile range (IQR). Parametric or non-parametric tests such as t-tests or Mann-Whitney U tests were used to analyze continuous variables accordingly. For the analysis of five-year freedom from secondary intervention and mortality, time-dependent Kaplan-Meier analysis and multivariable Cox-regression analyses were used. Kaplan-Meier estimates were presented as percentage (%) and standard error (SE). To investigate the aneurysm-sac volume over time, two longitudinal mixed effects model were made stratified on proximal sealing zone (infraceliac/supraceliac). In these models, time was entered as the independent variable and aneurysm volume as the dependent variable, assuming random intercepts and slopes to allow individual variation per patient (fixed: time + [time2]; random: ~time). To compare the time-sensitivity of the models, the models were run with and without different polynomial terms for time, and the difference in likelihood ratios was calculated. A 95% confidence interval (CI) was utilized, and statistical significance was defined as $p<.05$. All statistical analyses were conducted using RStudio (version 4.2.2, Foundation for Statistical Computing, Institute for Statistics and Mathematics, Vienna, Austria).

Results

Patient characteristics

Among 167 patients identified, 78 (47%) had a proximal sealing at an infraceliac level, and 89 (53%) had a sealing at a supraceliac level. In the supraceliac sealing group, 56 patients had four-vessel fenestrations, 31 patients had three-vessel fenestrations and a scallop, and two patients had three-vessel fenestrations due to an occluded visceral vessel. Regarding demographical characteristics, the proportion of current smokers was lower in the supraceliac group compared with the infraceliac sealing group (21% vs. 38%;

p=.024). Patients with supraceliac sealing had more often an ASA score of 3 or 4 compared to patients with an infraceliac sealing zone (74% vs. 51%, *p*=.004). Furthermore, patients with a supraceliac seal were more likely to have a prior EVAR in their medical history (31% vs. 12%, *p*=.004). The median proximal sealing length was 37mm [IQR, 28-52] for the

Table 1. Demographics and clinical characteristics of patients (N=167) treated by fenestrated endovascular aneurysm repair (FEVAR) stratified by proximal sealing zone

	Total (N=167)	Infraceliac sealing (N=78)	Supraceliac sealing (N=89)	
		N (percent) or mean±SD or median (IQR)		*p*-value
Age (at surgery), years	74± 6.8	75±6.9	74± 6.6	.34
Gender, female	26 (16)	12 (15)	14 (16)	1
Cardiovascular risk factors				
Hypertension	133 (80)	62 (79)	71 (80)	1
DM	26 (16)	9 (12)	17 (19)	.26
Current smoking	49 (29)	30 (38)	19 (21)	**.024**
PAOD	65 (39)	33 (42)	32 (36)	.50
Myocardial infarct	55 (33)	24 (31)	31 (35)	.83
COPD	54 (32)	24 (31)	30 (34)	.81
Preoperative eGFR				.66
eGFR >60 mL/min/1.73 m^2	105 (63)	48 (62)	57 (64)	
eGFR 30-60 mL/min/1.73 m^2	53 (32)	22 (28)	31 (35)	
eGFR <30 mL/min/1.73 m^2	3 (1.8)	2 (2.6)	1 (1.1)	
ASA III or IV	106 (63)	40 (51)	66 (74)	**.004**
Cancer	27 (16)	10 (13)	17 (19)	.44
Medication				
Beta blockers	139 (83)	64 (82)	75 (84)	1
Statins	116 (69)	53 (68)	63 (71)	1
Antiplatelets	37 (22)	15 (19)	22 (25)	.53
Anticoagulants	124 (74)	55 (71)	69 (78)	.47
Antihypertensives	88 (53)	40 (51)	48 (54)	.86
Prior surgery				
EVAR	37 (22)	9 (12)	28 (31)	**.004**
TEVAR	1 (0.6)	0 (0)	1 (1.1)	1
Open repair	3 (1.8)	1 (1.3)	2 (2.2)	1
Proximal seal diameter, mm	27±2.8	26±2.8	27±2.7	**.04**
Proximal seal length, mm	32 [23-44]	26 [19-34]	37 [28-52]	**<.001**
Distance endograft to upper renal, mm	29 [15-38]	19 [13-25]	47 [30-60]	**<.001**
Maximum perioperative aneurysm diameter, mm	61 [57-66]	59 [57-64]	62 [59-69]	.069

SD, standard deviation; *IQR*, interquartile range; *DM*, Diabetes Mellitus; *PAOD*, peripheral arterial occlusive disease; *COPD*, chronic obstructive pulmonary disease; *eGFR*, estimated glomerular filtration rate; *ASA*, American Society of Anesthesiologists; *EVAR*, endovascular aortic repair; *TEVAR*, thoracic endovascular aortic aneurysm; Boldface entries indicate statistical significance.

supraceliac group, and 26 mm [IQR, 19-34] for the infraceliac group, $p<.001$. The distance from endograft to uppermost renal was 47 mm [30-60] in the supraceliac group, and 19 mm [13-25] in the infraceliac group, $p<.001$ (**Table 1**). In our study, the procedures were significant longer for supraceliac sealing (240 min [IQR, 199-300] vs. 195 min [IQR, 168-242]; $p<.001$), and the fluoroscopy time, was significantly longer in the supraceliac group (77 min [IQR, 55-100] min vs. 56 [IQR, 45-67] min $p=.003$). No differences were found in Cumulative Air Kerma (CAK), use of contrast and blood loss (**Table 2**).

Table 2. Procedural details for fenestrated endovascular aortic repair (FEVAR) (N=167 patients) stratified by proximal sealing zone

	Total (N=167)	Infraceliac sealing (N=78)	Supraceliac sealing (N=89)	
		N (percent) or mean±SD or median (IQR)		*p*-value
Operative time, min	211 [180-280]	195 [168-242]	240 [199-300]	**<.001**
Fluoroscopy time, min	70 [53-92]	56 [45-67]	77 [55-100]	**.003**
CAK, mGy	1,221 [790-1,843]	1,067 [601-1,424]	1,294 [888-2,053]	.07
Contrast use, mL	132±51	134±56	130±46	.59
Blood loss, mL	300 [200-500]	300 [150-488]	300 [225-500]	.64
No. of target vessels	3.1±0.7	2.6±0.5	3.6±0.6	**<.001**
Celiac trunk	57 (34)	0 (0)	57 (64)	NA
Superior mesenteric artery	143 (86)	54 (69)	89 (100)	**<.001**
Right renal artery	159 (95)	71 (91)	88 (99)	**.045**
Left renal artery	161 (96)	74 (95)	87 (98)	.56

CAK, cumulative air kerma; *SD*, standard deviation; *IQR*, interquartile range; Boldface entries indicate statistical significance.

Perioperative outcomes

Both infraceliac and supraceliac sealing zones demonstrated satisfactory perioperative outcomes. Only one patient, with infraceliac sealing, experienced 30-day mortality, due to intraoperative complications. No patient died in-hospital after repair, beyond 30 days. The total occurrence of SCI and acute limb ischemia was low (SCI; 1 event in each group (1.2%, $p=.37$), acute limb ischemia; 1 event in supraceliac group, and 2 events in the infraceliac group (1.8%, $p=.93$)) and did not significantly differ between the groups. In total, 25 patients (15%) had acute kidney injury (AKI) after surgery, but there were no significant differences observed between the two groups. Notably, type 3c endoleaks only occurred in patients with supraceliac sealing (6.7% vs. 0.0%, $p=.03$) (**Table 3**). All these endoleaks originated from the renal arteries.

One-year aneurysm-sac dynamics

Imaging data from 137 patients (82%; 137/167) were obtained to analyze the one-year aneurysm-sac volume dynamics. No significant differences in one-year sac dynamics were observed between patients with supraceliac or infraceliac sealing zone: sac regression (63% vs. 69%), stable sac (16% vs. 20%), and sac expansion (21% vs. 11%) (*p*=.32) (**Table 3**).

Table 3. Early outcomes following fenestrated endovascular aortic repair (FEVAR) (N=167) stratified by proximal sealing zone

	Total (N=167)	Infraceliac sealing (N=78)	Supraceliac sealing (N=89)	
		N (percent) or mean±SD or median (IQR)		*p*-value
30-day mortality	1 (0.6)	1 (1.3)	0 (0)	1
Admission time, days	3 [3-5]	3[2-5]	4 [3-5]	.60
Spinal Cord Ischemia				.37
Grade 1	1 (0.6)	0 (0)	1 (1.1)	
Grade 2	1 (0.6)	1 (1.3)	0 (0.0)	
Grade 3	0	0	0	
AKI by KDIGO criteria				.62
Stage 1	21 (13)	11 (14)	10 (11)	
Stage 2	4 (2.4)	0 (0)	4 (4.5)	
Stage 3	0 (0)	0 (0)	(0)	
Buttocks claudication	3 (1.8)	1 (1.3)	2 (2.2)	1
30-day CTA endoleaks				
Type 1A	1 (0.6)	0 (0)	1 (1.1)	1
Type 2	7 (4.2)	1 (1.3)	6 (6.7)	.10
Type 3A	3 (1.8)	0 (0)	3 (3.4)	.25
Type 3C	6 (3.6)	0 (0)	6 (6.7)	**.03**
Undefined	4 (2.4)	0 (0)	4 (4.5)	.17
Access site hematoma	12 (7.1)	3 (3.8)	9 (10)	.19
Acute limb ischemia	3 (1.8)	2 (2.6)	1 (1.1)	.93
One-year aneurysm sac-dynamics	(N=137)	(N=61)	(N=76)	.32
Regression	90 (66)	42 (69)	48 (63)	
Stable	24 (17)	12 (20)	12 (16)	
Expansion	23 (17)	7 (11)	16 (21)	

AKI, acute kidney injury; *KDIGO*, Kidney Guidelines Improving Global Outcomes *CTA*, computed tomography angiography; *SD*, standard deviation; *IQR*, interquartile range; Boldface entries indicate statistical significance.

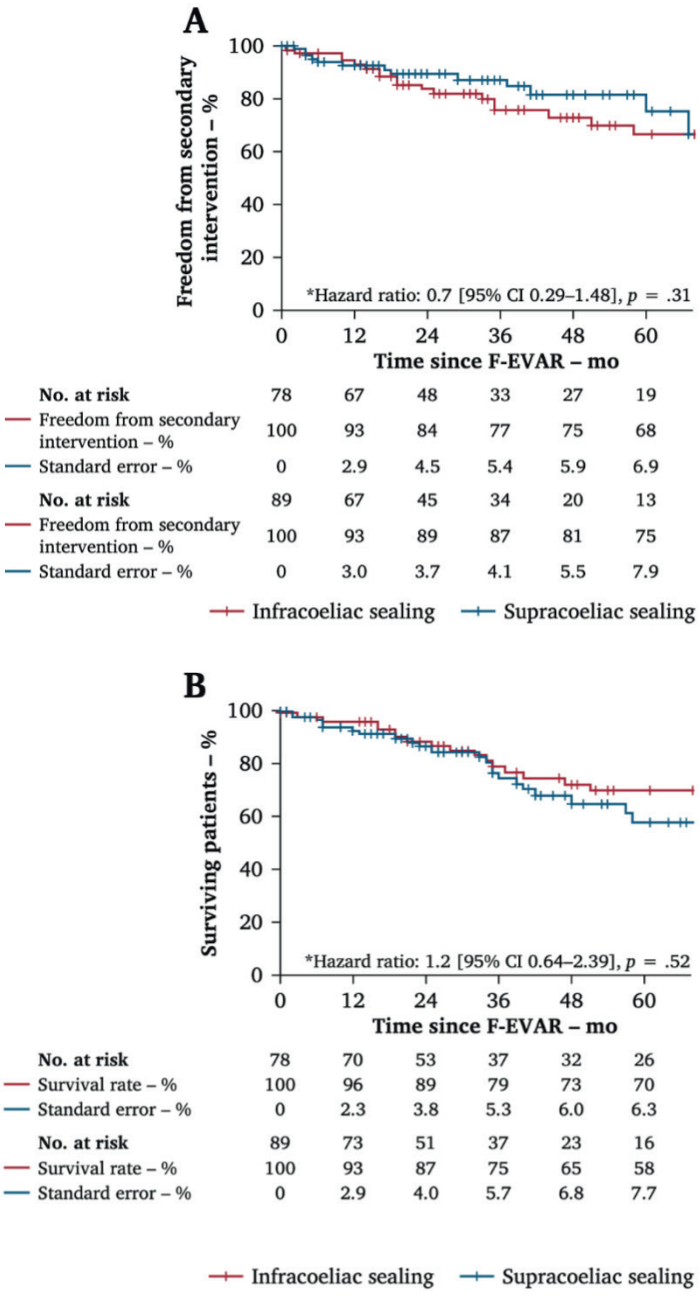

Fig 2. Cumulative Kaplan-Meier estimates of outcomes following fenestrated endovascular aortic repair (FEVAR) for juxtarenal abdominal aortic aneurysms stratified by proximal sealing zone: **(A)** freedom from secondary intervention; and **(B)** five-year mortality.

Mid-term outcomes

The median follow-up time was 33 months [IQR, 16-60]. Specifically, the median follow-up was 35 months (IQR, 20-68) for the infraceliac sealing group and 30 months (IQR, 15-48) for the supraceliac sealing group. There was no significant disparity observed in the three-year and five-year freedom for secondary intervention between supraceliac sealing and infraceliac sealing (three-year: 87±4.1% vs. 77±5.4%; five-year 75±7.9% vs. 68±6.9%, Log-Rank = .40/Hazard Ratio [HR]: 0.7 [95% CI: 0.29-1.48], *p*=.31) (**Fig 2A**). Within the group with supraceliac sealing, there was variation in the types of secondary interventions, while the group with infraceliac sealing predominantly underwent renal PTA, conversion to AUI, and limb extension procedures. Further details regarding the secondary interventions are available in **Supplemental Table 1**.

The three-year, and five-year freedom from mortality did also not differ significantly for patients with supraceliac sealing and infraceliac sealing (three-year: 75±5.7% vs. 79±5.3%; five-year: 58±7.7% vs. 70±6.3%, Log-Rank = .39/[HR]: 1.2 [95% CI: 0.64-2.39], *p*=.52) (**Fig 2B**).

Sac dynamics over time

The sac dynamics have been followed over a five-year period. The median radiological follow-up for the patients included in the sac dynamics analyses was 28 months (IQR, 16-46). For the infraceliac group, it was 29 months (IQR, 15-53), and for the supraceliac group, 27 months (IQR, 18-42). The longitudinal mixed effect models demonstrate aneurysm-sac volumes since the moment of FEVAR as function of time (in months), for both the infraceliac and supraceliac sealing zone. Our model shows no significant variations in sac volumes over time for both groups (**Fig 3**).

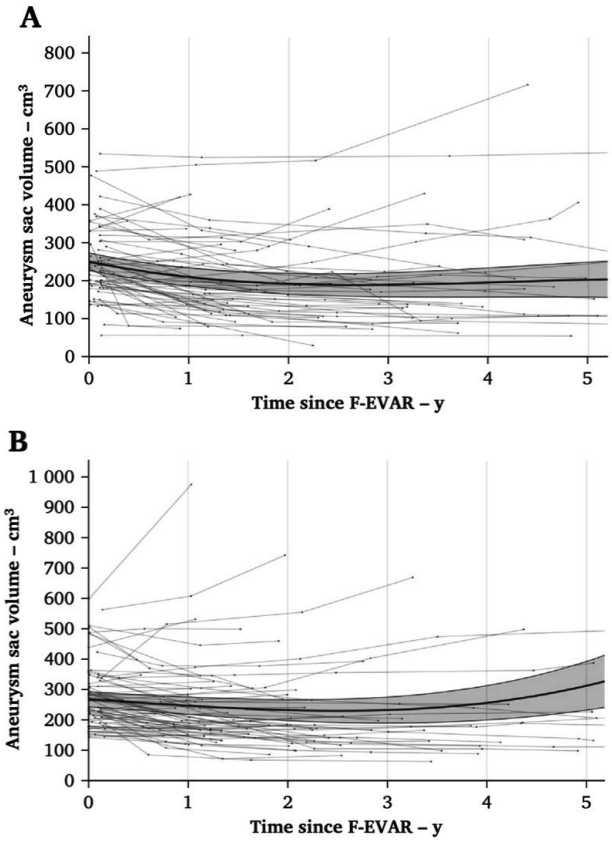

Fig 3. Linear mixed effects models for five-year aneurysm sac dynamics of patients treated by fenestrated endovascular aortic repair (FEVAR) for juxtarenal abdominal aortic aneurysms with **(A)** infraceliac and **(B)** supraceliac proximal sealing zone.

Discussion

Supraceliac sealing in FEVAR has been acknowledged for its potential advantages, attributed to a longer and improved proximal sealing zone, and to avoid technical challenges encountered in secondary interventions following FEVARs with infraceliac sealing. This study demonstrates that the use of supraceliac sealing in J-AAAs was associated with similar, low rates, of perioperative complications compared with infraceliac sealing. The only notable difference was found in perioperative endoleaks, with patients in the supraceliac sealing group experiencing a higher incidence of type 3c endoleaks (6.7% vs. 0.0%, p=.03), however with similar reintervention rates. Both groups showed comparable rates of one-year sac dynamics, freedom from secondary intervention, five-year mortality, and sac-dynamics over time.

Although the procedures were longer and more complex following FEVAR with sealing at a supraceliac level, this did not affect the 30-day outcomes. This contrasts with recent studies on AKI, where longer procedures and, in some cases, more contrast were found to be related with higher risk of AKI in complex endovascular aneurysm repair.[25-27] Out of all patients in the present study, 25 patients (15%) experienced AKI, 11 (15%) in the infraceliac group and 14 (15%) in the supraceliac group (p=.62). Conversely, Sailer et al. and Cucuruz et al. reported overall AKI rates of 28% and 36%, following complex endovascular aortic aneurysm repair.[26,27] Notably, regarding the sealing zones, Rastogi et al. found that AKI occurred in 16% of patients with supraceliac sealing and 11% in patients with infraceliac sealing (p=.024).[12] But important to emphasize is that the definition of AKI varied among these studies, with some using the KDIGO, others the Acute Kidney Injury Network criteria, and the RIFLE criteria.[23, 28, 29] Furthermore, another potential cause for the low incidence of AKI within our study cohort may be attributed to the restrictive inclusion of FEVAR patients. Existing literature on AKI after complex endovascular aortic aneurysm repair remains heterogeneous, whereas it has been established that BEVAR patients are more predisposed to experience AKI.[25, 27, 30] Finally, another factor contributing may be the reduced use of contrast over time in patients treated with both supraceliac and infraceliac sealing. Previous studies have established a correlation between higher contrast volumes and an increased risk of AKI.[26, 27] Sveinsson et al. conducted a study comparing early and late experiences with FEVAR, revealing a gradual reduce of contrast over time.[7] This decrease can be attributed to the pre-catheterizing of target vessels to aid in device positioning, diminishing the need for repeated contrast runs during deployment. The use of fusion techniques further reduces intraoperative contrast.[7,31] Besides, a significant difference in procedure duration was found between the supraceliac and infraceliac sealing group in the present study (240 min [IQR, 199-300] vs. 195 min [IQR, 168-242]; p<.001). This can be due to the higher prevalence of prior EVAR procedures among patients with supraceliac sealing (31% vs. 12%, p=.004), as technical challenges can be encountered when accessing target vessels in the presence of a previously implanted graft, which could result in increased difficulty and prolonged procedure times compared to standard four-vessel FEVAR.

Lastly, the occurrence of SCI, particularly paraplegia, remains the most concerning complication after FEVAR. It is known that the incidence of SCI is rare after endovascular repair of pararenal and juxtarenal aortic aneurysms.[32] Moreover, a previous study suggests that a higher sealing zone, is not associated with an increased risk of SCI.[12] Our study shows a SCI incidence of approximately 1% in both groups, and no cases of

paraplegia. Preventive methods for SCI have advanced significantly, including the use of permissive hypertension, neuromonitoring, cerebrospinal fluid drainage (CSFD) in four-vessel FEVARs, and the early restoration of limb blood flow. These advancements in techniques and performance over time may have also influenced the results.[33]

Exclusively patients with supraceliac sealing had perioperative type 3c endoleaks (6.7% vs. 0.0%; *p*=.03). All these endoleaks originated from the renal arteries. Two of the six type endoleaks were patients with prior EVAR. The technical challenges associated with accessing target vessels in the presence of a previously implanted graft could potentially explain this relationship, especially in cases of suprarenal fixation where cannulation must traverse the suprarenal stent. A clear explanation has not yet been found for the other endoleaks. Our hypothesis is that in supraceliac sealing, the anatomy is sometimes less ideal, which can lead to small, potentially invisible gaps between the FEVAR and the target vessel. Alternatively, manipulation during the procedure could cause the renal stent to compress, misalign, or subtly migrate. There were no significant changes in the use of bridging stents during our study period.

The findings from our study suggest that FEVAR with supraceliac and infraceliac sealing may be effective in achieving sac regression at one-year, as a majority of patients demonstrated aneurysm-sac regression (63% with supraceliac sealing, 69% with infraceliac sealing). In terms of one-year sac expansion, a total 23 patients showed sac growth after one-year (21% supraceliac (16/23), 11% infraceliac (7/23)). To provide a nuanced perspective, among patients with sac expansion, 65% (15/23) had a FEVAR after previous EVAR. Recent evidence suggests an association with significant sac growth in patients undergoing FEVAR after EVAR, compared to patients with a primary FEVAR.[34] In an additional analysis excluding patients after prior EVAR, there was no effect regarding 30-day outcomes, sac-dynamics, five-year mortality and secondary interventions comparing the supraceliac versus infraceliac sealing.

Despite the greater complexity and incorporation of more target vessels in supraceliac sealing, no significant differences were observed in terms of freedom from secondary intervention, even after risk-adjusted analysis for smoking, ASA 3 or 4, and prior EVAR. This aligns with the findings of Simons et al. who found no significant differences in reinterventions for supraceliac and infraceliac proximal sealing zone (<4 vessel repair 89% vs. 4-vessel repair 83%; *p*=.29).[35] In the present study, the type of secondary interventions for supraceliac sealing varied, with no observed trend. However, frequent secondary interventions after infraceliac sealing were limb extension, conversion to AUI, and renal PTA. Furthermore, after risk-adjusted analysis, the five-year mortality was

also similar for supraceliac and infraceliac sealing levels. These results are in contrast with prior studies, which found significant higher mortality rates for patients treated with supraceliac sealing zones.[5, 14-16, 36] It can be argued that the increased adoption of supraceliac sealing in recent years has led to an augmented learning curve, resulting in favorable outcomes. This is supported by the study of Mirza et al. and Sveinsson et al., indicating improved outcomes over time, despite increased complexity of aneurysm pathology.[7, 37] Additionally, it is worth noting that the centers participating in our study are tertiary referral centers with a high-volume. Alberga et al. demonstrated that high-volume is a predictor of favorable and improved outcomes in these centers.[38]

The sac dynamics over time showed no significant differences between the two groups. Although no differences were found, it is theoretical expected that over time supraceliac sealing should be better due to their "longer" sealing, considering the tendency of proximal sealing to dilate over time in.[9-11] According to the study of Rastogi et al., proximal seal dilatation occurs after FEVAR, accelerating in the first year and decelerating over time, a pattern similar to the neck dilatation observed in infrarenal EVAR.[10] Despite limited knowledge about the long-term consequences of this seal dilatation in FEVAR, it will most likely lead to clinical implications. If so, longer sealing lengths might be beneficial in avoiding endoleak development, endograft migration and proximal-seal related interventions. This should be confirmed by long-term studies.

The determination of the optimal seal zone and seal length for FEVAR remains uncertain. The reporting standards recommend sealing in "healthy aortic segments," which can be located either more proximal or distal to the extent of the aneurysm.[22] However, visually identifying these healthy aortic segments can be challenging, even with advanced imaging technologies. When there is evidence of proximal aortic pathology that might later require a TEVAR, supraceliac sealing should be favored, as infraceliac repair could complicate subsequent proximal aortic interventions. Imaging of the entire aorta before choosing the level of seal is therefore advisable. Over time we have been more aggressive towards a more proximal sealing zone to ensure durability. However, during the period of this study, endografts with inner branches to treat juxta-and pararenal aneurysms were not used in our centers. Future studies with long-term follow-up are necessary to assess the durability of higher sealing and provide more conclusive evidence. It is important to optimize the selection of the proximal sealing zone, and our findings contribute to better understanding regarding the safety of supraceliac sealing for J-AAAs.

Our study should be interpreted within its retrospective design. Despite all patients having a juxtarenal aortic aneurysm, the decision regarding whether to use supraceliac or infraceliac sealing levels was at the discretion of the treating vascular surgeon. This choice was likely influenced by both anatomical factors and surgeon preference. But recently, at our centers, the decision has also been guided by the desire to achieve a higher and more durable seal, which is advantageous in case a patient may require a TEVAR in the future. A significant trend towards supraceliac sealing was observed over the years (p=.032) (**Supplemental Table 2**). From 2008 to 2014, hospital one had 8 cases of infraceliac sealing and 13 cases of supraceliac sealing, while hospital two had 15 cases of infraceliac sealing and 1 case of supraceliac sealing. From 2015 to 2021, hospital one had 14 cases of infraceliac sealing and 60 cases of supraceliac sealing, whereas hospital two had 41 cases of infraceliac sealing and 15 cases of supraceliac sealing. In a subanalysis, no significant differences in perioperative and mid-term outcomes were found between the two centers. While it is crucial to acknowledge the potential impact of time bias in our study due to the growing adoption of supraceliac sealing over time, the fact that the results remain favorable is promising. Furthermore, key parameters related to durability, such as sealing zone effacement, neck dilatation, proximal endoleaks, and target vessel instability during follow-up, were not assessed. These factors have been shown to play an important role in mid-term outcomes after FEVAR and should be investigated in future research.[10, 39] Finally, the fact that only patients with one-year CTA were included for one-year aneurysm-sac dynamics may have caused selection bias, as patients who experienced early mortality were not captured in this analysis.

Conclusion

Both supraceliac and infraceliac sealings techniques showed similar mid-term outcomes, including sac dynamics, despite the greater complexity of the supraceliac procedure. Supraceliac sealing was associated with a higher rate of 30-day type 3c endoleaks, however, there were no differences in the secondary intervention rate at five years. The advantages of supraceliac sealing are posited, considering the tendency for sealing zones to dilate over time. Future studies should elucidate the long-term outcomes to assess the durability of sealing in a more proximal part of the aorta.

Fig 1 in this chapter was drawn by Mr. David Factor. Used with permission.

References

1. Chaikof EL, Dalman RL, Eskandari MK, Jackson BM, Lee WA, Mansour MA, et al. The Society for Vascular Surgery practice guidelines on the care of patients with an abdominal aortic aneurysm. J Vasc Surg. 2018;67:2-77 e2.
2. De Bruin JL, Baas AF, Buth J, Prinssen M, Verhoeven EL, Cuypers PW, et al. Long-term outcome of open or endovascular repair of abdominal aortic aneurysm. N Engl J Med. 2010;362:1881-9.
3. Greenberg RK, Haulon S, Lyden SP, Srivastava SD, Turc A, Eagleton MJ, et al. Endovascular management of juxtarenal aneurysms with fenestrated endovascular grafting. J Vasc Surg. 2004;39:279-87.
4. Schanzer A, Oderich GS. Management of Abdominal Aortic Aneurysms. N Engl J Med. 2021;385: 1690-8.
5. Mastracci TM, Eagleton MJ, Kuramochi Y, Bathurst S, Wolski K. Twelve-year results of fenestrated endografts for juxtarenal and group IV thoracoabdominal aneurysms. J Vasc Surg. 2015;61:355-64.
6. Oderich GS, Greenberg RK, Farber M, Lyden S, Sanchez L, Fairman R, et al. Results of the United States multicenter prospective study evaluating the Zenith fenestrated endovascular graft for treatment of juxtarenal abdominal aortic aneurysms. J Vasc Surg. 2014;60:1420-8 e1-5.
7. Sveinsson M, Sobocinski J, Resch T, Sonesson B, Dias N, Haulon S, et al. Early versus late experience in fenestrated endovascular repair for abdominal aortic aneurysm. J Vasc Surg. 2015;61:895-901.
8. Katsargyris A, Oikonomou K, Kouvelos G, Mufty H, Ritter W, Verhoeven ELG. Comparison of outcomes for double fenestrated endovascular aneurysm repair versus triple or quadruple fenestrated endovascular aneurysm repair in the treatment of complex abdominal aortic aneurysms. J Vasc Surg. 2017;66:29-36.
9. Zettervall SL, Dansey K, Kline B, Singh N, Starnes BW. Significant aortic neck dilation occurs after repair of juxtarenal aneurysms with fenestrated endovascular aneurysm repair. J Vasc Surg. 2021; 74:1090-7 e2.
10. Rastogi V, de Bruin JL, Varkevisser RRB, Oliveira NFG, Bouwens E, Hoeks SE, et al. Proximal seal dilatation following fenestrated endovascular repair for complex abdominal aortic aneurysms. J Vasc Surg. 2022;75:1521-9 e1.
11. Tran K, Deslarzes-Dubuis C, Lee JT. Quantification of suprarenal aortic neck dilation after fenestrated endovascular aneurysm repair. J Vasc Surg. 2021;73:31-8.
12. Rastogi V, Marcaccio CL, Kim NH, Patel PB, Anjorin AC, Zettervall SL, et al. The effect of supraceliac versus infraceliac landing zone on outcomes following fenestrated endovascular repair of juxta-/ pararenal aortic aneurysms. J Vasc Surg. 2023;77:9-19 e2.
13. Kitpanit N, Ellozy SH, Connolly PH, Agrusa CJ, Lichtman AD, Schneider DB. Risk factors for spinal cord injury and complications of cerebrospinal fluid drainage in patients undergoing fenestrated and branched endovascular aneurysm repair. J Vasc Surg. 2021;73:399-409 e1.
14. Patel SD, Constantinou J, Simring D, Ramirez M, Agu O, Hamilton H, et al. Results of complex aortic stent grafting of abdominal aortic aneurysms stratified according to the proximal landing zone using the Society for Vascular Surgery classification. J Vasc Surg. 2015;62:319-25 e2.
15. Roy IN, Millen AM, Jones SM, Vallabhaneni SR, Scurr JRH, McWilliams RG, et al. Long-term follow-up of fenestrated endovascular repair for juxtarenal aortic aneurysm. Br J Surg. 2017;104:1020-7.
16. British Society for Endovascular T, the Global Collaborators on Advanced Stent-Graft Techniques for Aneurysm Repair R. Early results of fenestrated endovascular repair of juxtarenal aortic aneurysms in the United Kingdom. Circulation. 2012;125:2707-15.
17. World Medical A. World Medical Association Declaration of Helsinki: ethical principles for medical research involving human subjects. JAMA. 2013;310:2191-4.
18. von Elm E, Altman DG, Egger M, Pocock SJ, Gotzsche PC, Vandenbroucke JP, et al. The Strengthening the Reporting of Observational Studies in Epidemiology (STROBE) statement: guidelines for reporting observational studies. J Clin Epidemiol. 2008;61:344-9.
19. Rastogi V, Sulzer TL, de Bruin JL, Oliveira-Pinto J, Alberga AJ, Hoeks SE, et al. Aneurysm Sac Dynamics and its Prognostic Significance Following Fenestrated and Branched Endovascular Aortic Aneurysm Repair. Eur J Vasc Endovasc Surg. 2024;67(5):728-36.
20. Sulzer TAL, de Bruin JL, Rastogi V, Boer GJ, Mesnard T, Fioole B, et al. Mid-Term Outcomes and Aneurysm Sac Dynamics Following Fenestrated Endovascular Aneurysm Repair after Previous Endovascular Aneurysm Repair. Eur J Vasc Endovasc Surg. 2024;67(6):886-93.

21. Fillinger MF, Greenberg RK, McKinsey JF, Chaikof EL, Society for Vascular Surgery Ad Hoc Committee on TRS. Reporting standards for thoracic endovascular aortic repair (TEVAR). J Vasc Surg. 2010;52: 1022-33, 33 e15.
22. Oderich GS, Forbes TL, Chaer R, Davies MG, Lindsay TF, Mastracci T, et al. Reporting standards for endovascular aortic repair of aneurysms involving the renal-mesenteric arteries. J Vasc Surg. 2021; 73:4S-52S.
23. Khwaja A. KDIGO clinical practice guidelines for acute kidney injury. Nephron Clin Pract. 2012;120: c179-84.
24. Bastos Goncalves F, van de Luijtgaarden KM, Hoeks SE, Hendriks JM, ten Raa S, Rouwet EV, et al. Adequate seal and no endoleak on the first postoperative computed tomography angiography as criteria for no additional imaging up to 5 years after endovascular aneurysm repair. J Vasc Surg. 2013;57:1503-11.
25. Rastogi V, de Bruin JL, Bouwens E, Hoeks SE, Ten Raa S, van Rijn MJ, et al. Incidence, Prognostic Significance, and Risk Factors of Acute Kidney Injury Following Elective Infrarenal and Complex Endovascular Aneurysm Repair. Eur J Vasc Endovasc Surg. 2022;64:621-9.
26. Sailer AM, Nelemans PJ, van Berlo C, Yazar O, de Haan MW, Fleischmann D, et al. Endovascular treatment of complex aortic aneurysms: prevalence of acute kidney injury and effect on long-term renal function. Eur Radiol. 2016;26:1613-9.
27. Cucuruz B, Kasprzak PM, Gallis K, Schierling W, Pfister K, Kopp R. Midterm outcome of renal function after branched thoracoabdominal aortic aneurysm repair. J Vasc Surg. 2020;71:1119-27.
28. Mehta RL, Kellum JA, Shah SV, Molitoris BA, Ronco C, Warnock DG, et al. Acute Kidney Injury Network: report of an initiative to improve outcomes in acute kidney injury. Crit Care. 2007;11:R31.
29. Bellomo R, Kellum JA, Ronco C. Defining and classifying acute renal failure: from advocacy to consensus and validation of the RIFLE criteria. Intensive Care Med. 2007;33:409-13.
30. Martin-Gonzalez T, Pincon C, Maurel B, Hertault A, Sobocinski J, Spear R, et al. Renal Outcomes Following Fenestrated and Branched Endografting. Eur J Vasc Endovasc Surg. 2015;50:420-30.
31. Maurel B, Hertault A, Sobocinski J, Le Roux M, Gonzalez TM, Azzaoui R, et al. Techniques to reduce radiation and contrast volume during EVAR. J Cardiovasc Surg (Torino). 2014;55:123-31.
32. Rinaldi E, Melloni A, Gallitto E, Fargion A, Isernia G, Kahlberg A, et al. Spinal Cord Ischemia After Thoracoabdominal Aortic Aneurysms Endovascular Repair: From the Italian Multicenter Fenestrated/ Branched Endovascular Aneurysm Repair Registry. J Endovasc Ther. 2023;30:281-8.
33. Sulzer TAL, Vacirca A, Mesnard T, Baghbani-Oskouei A, Savadi S, Kanamori LR, et al. How We Would Treat Our Own Thoracoabdominal Aortic Aneurysm. J Cardiothorac Vasc Anesth. 2024;38:379-87.
34. Sanders AP, Swerdlow NJ, Yadavalli SD, Marcaccio CL, Stangenberg L, Schermerhorn ML. Reinterventions and sac dynamics after fenestrated endovascular aortic repair with physician-modified endografts for index aneurysm repair and following proximal failure of prior endovascular aortic repair. J Vasc Surg. 2024;79(6):1287-94 e1.
35. Simons JP, Podder S, Dossabhoy SS, Wyman AS, Arous EJ, Judelson DR, et al. Fenestrated/Branched Endovascular Aortic Aneurysm Repair Using a Supraceliac Aortic Proximal Seal Zone Versus an Infraceliac Aortic Proximal Seal Zone. Ann Vasc Surg. 2020;62:213-22.
36. O'Callaghan A, Greenberg RK, Eagleton MJ, Bena J, Mastracci TM. Type Ia endoleaks after fenestrated and branched endografts may lead to component instability and increased aortic mortality. J Vasc Surg. 2015;61:908-14.
37. Mirza AK, Tenorio ER, Karkkainen JM, Hofer J, Macedo T, Cha S, et al. Learning curve of fenestrated and branched endovascular aortic repair for pararenal and thoracoabdominal aneurysms. J Vasc Surg. 2020;72:423-34 e1.
38. Alberga AJ, von Meijenfeldt GCI, Rastogi V, de Bruin JL, Wever JJ, van Herwaarden JA, et al. Association of Hospital Volume with Perioperative Mortality of Endovascular Repair of Complex Aortic Aneurysms: A Nationwide Cohort Study. Ann Surg. 2021.
39. Becker D, Sikman L, Ali A, Mosbahi S, C FP, Stana J, et al. Analysis of Target Vessel Instability in Fenestrated Endovascular Repair (f-EVAR) in Thoraco-Abdominal Aortic Pathologies. J Clin Med. 2024;13.

Supplemental Material

Supplemental Table 1. Details of secondary interventions following a supraceliac or infraceliac proximal sealing zone in fenestrated endovascular aneurysm repair (FEVAR)

	Supraceliac (n=13)	Infraceliac (n=19)
Proximal cuff	1	
Limb extension	3	4
Iliac PTA		1
Conversion AUI	1	4
Coil/glue/embolization	1	3
Open conversion	1	
Renal stenting	1	1
Renal PTA	2	5
TEVAR	1	
BEVAR in FEVAR	1	
Fem-fem crossover bypass	1	
Endovascular bridging tube		1

PTA, percutaneous transluminal angioplasty; *AUI*, aorto-uni-iliac stent; *TEVAR*, thoracic endovascular aneurysm repair; *BEVAR*, branched endovascular aneurysm repair; *FEVAR*, fenestrated endovascular aneurysm repair.

Supplemental Table 2. Trend of supraceliac and infraceliac sealing in fenestrated endovascular aneurysm repair (FEVAR) at the two study centers over time

Time	Supraceliac sealing (n=78)	Infraceliac sealing (n=89)	*p*-value
2008-2014	23	14	
2015-2021	55	75	
			.032

FEVAR, fenestrated endovascular aneurysm repair.



Chapter 12

General discussion

PART I: PERIOPERATIVE AND TECHNICAL ASPECTS OF COMPLEX AORTIC ANEURYSMS

The introduction of endovascular stent grafts has significantly improved the treatment of abdominal and thoracic aortic aneurysms. During the last decades, the development of endovascular techniques for complex aneurysms involving visceral arteries has similarly transformed the management of complex aortic disease including the use of fenestrated and branched endografts. While these devices are predominantly technically successful, they can still lead to complications if not deployed correctly. **Part I** provides a comprehensive and insightful overview of the field of endovascular surgery, highlighting the increasing adoption of endovascular aortic repair (EVAR) and fenestrated-branched EVAR (FB-EVAR) as preferred treatments for aortic aneurysms, including thoracoabdominal aortic aneurysms (TAAAs). This shift is driven by reported favorable outcomes, including lower morbidity and mortality rates, faster recovery, and the ability to treat older, frail, and higher-risk patients who might not be suitable for open surgical repair.[1-4] However, the increasing complexity of these procedures, especially when treating challenging anatomy, means that intraoperative difficulties and potential complications remain significant concerns, even in highly standardized settings and high-volume centers with state of the art imaging and surgical techniques.

Chapter 2 investigates the pathophysiology, epidemiology, diagnosis, and the intricate perioperative, intraoperative, and postoperative management strategies. A central and critical focus is the prevention and management of spinal cord ischemia (SCI), a severe complication associated with TAAA repair, regardless of the method.

Chapter 3 meticulously describes the types of intraoperative adverse events (IAEs) that can occur during EVAR and FB-EVAR. These technical problems directly influence the severe postoperative complications highlighted in **Chapter 2**, such as SCI. For example, accidental disruption of iliac arteries during access carries the risk of severe hypotension, which, can significantly increase the risk of SCI by compromising spinal cord perfusion. Similarly, failure to cannulate target arteries can lead to kidney failure and mesenteric ischemia, contributing to the "major adverse events". **Chapter 4** further illustrates how technical challenges during graft deployment in an angulated neck during EVAR, can lead to issues like Type Ia endoleaks, which might necessitate secondary interventions, aligning with the concerns about graft-related IAEs.

All three chapters acknowledge the advancements in graft designs and intraoperative imaging (e.g., onlay fusion, cone-beam computed tomography (CBCT)). These technologies improve precision and allow for early identification of technical issues.

However, they might not be the holy grail. Despite the improved grafts and techniques, patients with more complex anatomy and substantial comorbidities are now increasingly being treated, which continues to make these procedures challenging and complications unavoidable. In **Chapter 4**, we highlight that even with a "conformable" device designed for challenging anatomies, manual adjustments and deviations from standard Instructions for Use are necessary to achieve optimal results in a highly angulated neck. This emphasizes that stent graft technology is important, however not the complete solution; the expertise of the operating team remains crucial in diminishing the risk on adverse perioperative events. This is why **Chapter 2** emphasizes the need for a multidisciplinary team approach. In **Chapter 3** and **Chapter 4** this approach resonates, quantifying the impact of learning curve and experience in high-volume centers. The importance of centralizing complex EVAR and FB-EVAR in high-volume centers cannot be overstated. Multiple studies suggest that center and operator experience significantly reduce the incidence of IAEs and improve outcomes, particularly in anatomically challenging cases.[5, 6]

As with any surgical procedure, there is a learning curve associated with mastering complex EVAR techniques. Nowadays, every vascular surgeon is trained in guidewire and catheter techniques, however, achieving consistently favorable outcomes depends heavily on repetition and cumulative experience. Lobato et al. wrote in 2002 that performing at least 55 EVAR cases in total and maintaining a frequency of at least one case every 10 days, appears necessary to obtain optimal operative results.[7] In most centers, EVAR-related mortality is now <1%. Learning these techniques of complex aortic procedures requires extensive endovascular experience including, renal and mesenteric stenting, and knowledge of complication management, as discussed in **Chapter 3**. Studies comparing early and later experiences with FB-EVAR consistently show that outcomes improve as the team's and individual surgeon's experience increases.[8, 9] With this in mind, it is important that young surgeons gain early exposure to these complex cases. Countries with a dedicated vascular residency program are in a strong position to integrate this early exposure. Above all, training should continue to emphasize bail-out strategies and maintaining the skills required to convert to open repair when necessary.

Finally, a patient-specific approach and treatment planning is required for these complex cases as mentioned in **Chapter 2**. Some patients are suitable for off-the-shelf devices, but not all of them. In Europe the customized stent-graft with a combination of fenestrations and/or branches are approved and made by commercial businesses based on the patient's computed tomography angiography (CTA). In the United States these devices

are still under investigation in a hand full of centers. The principal investigators, make hand-drawn sketches of the custom-made stent grafts, calculating clock positions, diameters and angulation. Then they send their plan to the medical device company, who makes the graft accordingly. In both situations, the patient's its characteristics as well as unique aorta anatomy should be meticulously checked.

In conclusion, this part underscores that endovascular TAAA treatment requires an expert-driven, multidisciplinary, and individualized approach, with adaptation of techniques when standard approaches prove insufficient. Future directions include advances in imaging and device technology, artificial intelligent (AI)-assisted planning, and patient-specific strategies. Structured training and centralization in high-volume centers may shorten learning curves and improve management of intraoperative adverse events. Novel strategies to prevent major adverse events, like spinal cord ischemia, also warrant investigation. All aiming to further improve outcomes in complex EVAR and FB-EVAR.

PART II: SAC DYNAMICS AS A PROGNOSTIC MARKER FOR CLINICAL SUCCESS

Traditionally, success after aneurysm repair was primarily focused on preventing rupture. However, as evidence accumulates, surrogate markers for long-term outcomes, particularly aneurysm sac behavior is pivotal and associated with survival, graft-related complications, and durability. This has been extensively investigated after infrarenal EVAR, however only a few publications have shown this after complex endovascular aneurysm repair.[10-14] Currently, sac dynamics, and particularly sac regression, may serve as a prognostic marker beyond aortic-related events, a hypothesis that is reinforced throughout **Part II**.

Chapter 5 demonstrates that aneurysm sac shrinkage at one year occurred in 58% of FB-EVAR patients and was associated with improved patient survival at five years (69% versus 46%). After adjusting for relevant comorbidities and aneurysm extent, the hazard of late mortality was 1.7 times higher in patients whose aneurysm sac failed to regress. This survival benefit was seen in extent I–III TAAA patients, but not in those with complex AAAs or extent IV TAAAs. Importantly, aortic-related mortality and rupture were rare in both groups, suggesting that sac non-regression may be a marker for overall patient risk and non-aortic causes of death. No significant difference in aortic-related secondary interventions or endoleak-related secondary interventions was found between the sac regression and non-regression groups.

These findings were confirmed in **Chapter 6** using a separate dataset across two high-volume centers. In this cohort of FB-EVAR patients, volume-based measurements showed that non-regression at one-year (volume decrease <5%) was associated with a 2.6 times increased risk of five-year mortality and 2.4 times higher risk of graft-related events, even after risk adjustment. Interestingly, sac behavior differed by repair type. After FEVAR, aneurysm sacs generally displayed regression (66% at one-year), with volumes decreasing significantly up to two years and remaining stable thereafter. Following branched-EVAR (BEVAR), aneurysm sac volume overall remained stable over five years, but a concerning proportion (28%) showed sac expansion at one-year. This might be associated with a difference of aneurysm sac behavior in abdominal aneurysm compared to thoraco-abdominal aneurysms. Factors associated with non-regression were previous aortic repair and larger baseline aneurysm diameter.

Chapter 5 and **Chapter 6** emphasize the need for a personalized surveillance strategy. Patients with non-regression, prior aortic repair, or large aneurysm diameters may benefit from intensified imaging follow-up. This aligns with previous studies in infrarenal aneurysm management for patient-specific post-EVAR protocols, which are increasingly incorporating early aneurysm sac changes.[13, 15, 16] Personalized medicine has the potential to minimize radiation exposure and nephrotoxic contrast effects in low-risk patients, while also reducing the burden and costs associated with frequent imaging. However, in contrast to standard EVAR, there is currently limited evidence to support personalized surveillance after FB-EVAR.[17] Future studies should explore whether sac behavior after FB-EVAR can guide the intensity and frequency of surveillance, similar to how this is evolving for infrarenal EVAR. In **Chapter 8** and **Chapter 9** novel data is presented on "normal" duplex ultrasound (DUS) velocities after FB-EVAR and highlight how these differ from native, unstented vessels. A start for introducing routine surveillance with DUS following FB-EVAR, which could prove particularly valuable in the future for low-risk patients who may benefit from a less intensive follow-up strategy.

A major difference between **Chapter 5** and **Chapter 6** is the method of measuring sac dynamics: diameter versus volume. Volume measurements are more sensitive, particularly in patients with irregular or complex aneurysm morphology, and can detect changes beyond the standard orthogonal planes. However, they are also time-consuming and require highly trained staff. This challenge opens the door to automated or AI-solutions. To date, most AI-segmentation tools have been developed and validated for infrarenal EVAR, with limited applicability to FB-EVAR. The limitation is that most models are not trained on postoperative imaging with metallic stent artifacts, which can interfere with accurate segmentation in FB-EVAR. But recent advances are promising. For

example, fully automated machine learning segmentation software has demonstrated high accuracy in measuring AAA sac volume evolution.[18] Since the evolution in AI is going so rapid, it is expected that these models will soon be applicable for fenestrated and branched repairs as well. Robbi et al. introduced Blood Vessels Recognition and Aneurysms Visualization Enhancement (BRAVE), offering exhaustive segmentation, identifying both the primary abdominal aorta and secondary vessels.[19] Although this method is primarily used for EVAR planning, their 3D-models could potentially be leveraged for sac dynamic simulation, computational fluid analysis, and personalized risk stratification.

In **Chapter 7** we shift focus to comparing FEVAR after EVAR with primary FEVAR. These are the first results, noting higher rates of sac expansion (48% at one-year) and aortic-related procedures for FEVAR after previous EVAR, while showing no significant difference in five-year mortality. This raises questions about the long-term durability of FEVAR after EVAR. And what are the causes for non-regression in the cases with perfect alignment and absence of visible endoleaks? This may point to underlying biological processes such as persistent inflammation, genetic predispositions, occult endoleak or microleakage through graft fabric. Prior biomarker studies have shown that certain circulating proteins, including LDLR, TFPI, TIMP4, and IGFBP-2, are independently associated with sac volume after EVAR, suggesting ongoing biological activity in the aneurysm sac even after technically successful repair.[20] Possible contributing factors include genetic predisposition for connective tissue disorder, higher inflammatory activity or impaired aortic wall remodeling. Based on this, one might expect that patients with a family history of aortic aneurysms have worse outcomes or less sac regression. In **Chapter 10** a detailed analysis on family history for complex aortic aneurysms is presented. Interestingly, a non-significant trend toward increased sac growth was observed in patients without a positive family history (23% versus 21% at three years). These findings contrast with other studies reporting more sac growth in patients with a positive family history after EVAR. Recent European Society of Cardiology (ESC) and American Heart Association (AHA) guidelines highlight the importance of genetic testing in patients with suspected hereditary aortic conditions, especially in the presence of syndromic features, a family history of aortic or intracranial aneurysms, early disease onset (<60 years), or sudden death among first- or second-degree relatives.[21, 22] To improve outcomes and risk stratification, routine implementation of these guidelines is essential, and greater integration into daily practice in both Europe and the United States is warranted. This chapter highlights the need for future research into biomarkers or pharmacologic interventions (e.g., anti-inflammatory drugs) that might promote

sac regression. As genetic testing becomes more widely adopted, our understanding of hereditary contributions to aneurysm behavior is expected to grow significantly.

Sac dynamics have emerged as a potential marker for clinical success, with early regression linked to improved outcomes. However, the exact mechanisms behind non-regression remain poorly understood. Whether active sac-management will improve the outcomes after endovascular treatment is subject of future studies.

PART III: DUPLEX ULTRASOUND SURVEILLANCE AFTER COMPLEX AORTIC ANEURYSM REPAIR

After complex aortic repair, lifelong imaging surveillance is essential to detect target vessel complications and guide timely secondary interventions. Although CTA remains the gold standard, it has limitations, including radiation exposure, nephrotoxic contrast, and reduced accuracy in small, stented vessels due to metallic artifact. Duplex ultrasound has therefore emerged as a valuable complementary tool: it is widely available, free of radiation and contrast, and can detect hemodynamic changes suggestive of stenosis or occlusion. However, its use depends on operator expertise, and standardized velocity criteria for stented vessels are still lacking. This part examines the role of DUS after FB-EVAR, highlighting its current value as a complement to CTA and its potential future role in replacing some CTA examinations during long-term follow-up of stable FB-EVAR.

Chapter 8 shows that velocity criteria derived from native vessels cannot be directly applied to stented arteries. By comparing preoperative values with those at 6-8 weeks after FB-EVAR, only minor changes in peak systolic velocities (PSV) were observed: no significant rise at the vessel origin or proximal segment, and a modest increase in the mid-segment. All PSVs remained well below the thresholds used for native vessels. Balloon-expandable stents showed slightly higher velocities than self-expanding stents. In sub analyses, a significant difference was observed between fenestrated and branched target vessels, with PSVs increasing in fenestrated vessels and decreasing in branched vessels after 6-8 weeks.

Chapter 9 extends these findings by analyzing PSV changes over a median follow-up of 23 months in 1,311 target vessels after FB-EVAR. For directional branches (DBs), PSV decreased in the first 6-8 weeks, remained stable thereafter, and showed only a non-significant increase at five years. In contrast, reinforced fenestrations (RFs) were associated with an early rise in PSV that remained higher than in DBs throughout

follow-up. Branched mesenteric vessels with balloon-expandable stents had higher velocities than those with self-expanding stents. Among 23 target vessels undergoing secondary intervention for stenosis, 83% had velocities above the thresholds used for native vessels. In renal arteries, a PSV cut-off of 231 cm/s predicted clinically relevant stenosis with an area under the curve of 0.98. Overall, these results confirm that velocity patterns depend on incorporation technique and stent type, but PSV values typically remain below native-vessel thresholds, highlighting that PSV alone should not guide secondary intervention decisions.

Duplex ultrasound suffers from operator dependency and its limited ability to detect morphological complications such as stent fracture or migration. Nevertheless, it is valuable for the early detection of branch occlusion, stenosis, and endoleaks, all of which may adversely affect outcomes. **Chapter 9** focused primarily on descriptive PSV trends and on the diagnostic accuracy of DUS in identifying stenosis. However, the number of events was low, which limits the strength of these conclusions.

Current guidelines recommend CTA-based surveillance at one month and 12 months after EVAR, followed by annual imaging. In stable patients undergoing standard EVAR, CTA can be replaced by DUS for long-term follow-up.[23, 24] For FB-EVAR, however, no standardized protocol exists. Expert consensus emphasizes the need for close surveillance to ensure durable results. According to the 2024 European Society for Vascular Surgery (ESVS) guidelines, surveillance after FB-EVAR should include assessment of aneurysm sac size, detection of endoleaks, and evaluation of target vessel patency and integrity. CTA remains the primary imaging modality, with at least a 30-day and a one-year postoperative CTA recommended, followed by individualized imaging thereafter. In selected stable patients, DUS may replace CTA during later follow-up. Duplex ultrasound protocols can be adapted from those used after standard EVAR, but must also include assessment of fenestrations, branches, and patency of the renal and mesenteric arteries.[24]

However, the guideline provides no evidence-based instructions on how to apply DUS in this setting, and do not define "normal" PSV values for stented target vessels. As a result, the practical use of DUS to detect stenosis in fenestrated or branched vessels remains unclear. The criteria proposed in **Chapter 9**, derived from only 23 renal arteries with stenosis after FB-EVAR, suggest that a PSV of 231 cm/s can predict clinically relevant stenosis with an AUC of 0.98. These findings require validation in large, prospective multicenter studies, given the variability in operator experience and patient populations, to achieve standardized surveillance criteria and ensure reliable clinical implementation.

After that, DUS can hopefully be reliably used for surveillance, including restenosis, occlusion and endoleaks. Further research into the role of DUS and contrast-enhanced ultrasound (CEUS) would be valuable. For example, a combined surveillance protocol in which patients undergo both CTA and ultrasound, with outcomes compared head-to-head, would help to define their respective roles. In the future, models that integrate patient anatomy, imaging data (e.g. sac dynamics), age, renal function, and other clinical parameters could be used to personalized surveillance, reducing radiation exposure, contrast use, and costs while focusing resources on those at highest risk.

The guidelines also note that CEUS can serve as alternatives to CTA for FB-EVAR follow-up. This is supported by single-center retrospective studies by Gargiulo et al. and Perini et al., which found CEUS to be comparable to CTA for detecting changes in sac size, endoleaks, and target vessel patency.[25, 26] Although their findings are promising, these studies were small and clearly underpowered to change clinical practice.

One limitation already mentioned is the operator dependency of DUS. To facilitate widespread implementation of DUS surveillance, a standardized protocol for imaging the aorta and target vessels is essential. The protocol we used in our single-center study (*presented on the next page*) is highly detailed and structured. Although our study benefited from the presence of dedicated vascular sonographers, we acknowledge this may not be feasible in every setting. Training programs and close collaboration between vascular sonographers, radiologists, and vascular surgeons will be an important step forward.

Future technological advancements such as automated ultrasounds studies and other AI-assisted image interpretation could also help towards a more efficient integration. Recent work in the carotid artery field illustrates this potential. A prospective single-center study by Kordzadeh et al. demonstrated in 156 images, an AI-driven program applied to greyscale DUS images could accurately distinguish normal from stenotic carotid arteries, achieving sensitivities and specificities of around 90%.[27] This approach reduces operator dependency by shifting from a qualitative to a data-driven, quantitative interpretation. This illustrates how AI-tools could eventually be embedded into DUS for aortic surveillance as well.

Example of integrated duplex ultrasound protocol

DUPLEX IMAGING_____

Patient Initials			Date of Evaluation			-				-				
				D	D		M	M	M		Y	Y	Y	Y

Exam Period:	☐ Pre-procedure	☐ 6 month	☐ 24 Month	☐ 4 Year	☐ Other
	☐ 6-8 weeks	☐ 12 Month	☐ 3 Year	☐ 5 Year	
Technically adequate exam:	☐ Yes	→ If No, state reason:			
	☐ No				

AORTA

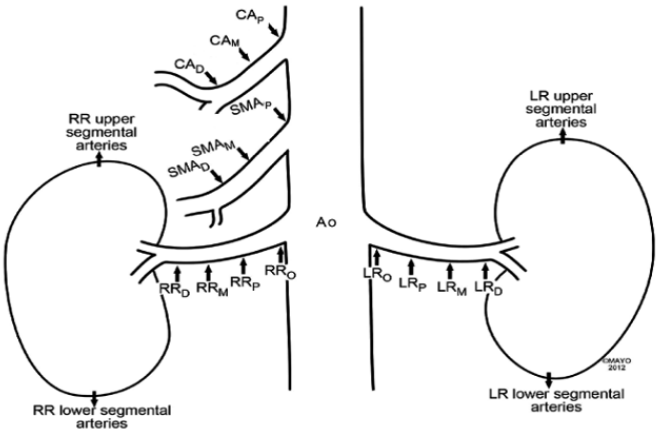

AORTA							
Measurement at the level of Renals (Ao):	PSV:	cm/sec	No data ☐	EDV:	cm/sec	No data ☐	

CELIAC ARTERY	**NOT APPLICABLE** ☐		**Stent present in artery (Post-op only):**		**YES** ☐	**NO** ☐
Celiac Artery Origin (CAO):	PSV:	cm/sec	No data ☐	EDV:	cm/sec	No data ☐
Celiac Artery Proximal (CAP):	PSV:	cm/sec	No data ☐	EDV:	cm/sec	No data ☐
Celiac Artery Middle (CAM):	PSV:	cm/sec	No data ☐	EDV:	cm/sec	No data ☐
Celiac Artery Distal (CAD):	PSV:	cm/sec	No data ☐	EDV:	cm/sec	No data ☐

SMA	**NOT APPLICABLE** ☐		**Stent present in artery (Post-op only):**		**YES** ☐	**NO** ☐
SMA Origin l (SAO):	PSV:	cm/sec	No data ☐	EDV:	cm/sec	No data ☐
SMA Proximal (SMAP):	PSV:	cm/sec	No data ☐	EDV:	cm/sec	No data ☐
SMA Middle (SMAM):	PSV:	cm/sec	No data ☐	EDV:	cm/sec	No data ☐
SMA Distal (SMAD):	PSV:	cm/sec	No data ☐	EDV:	cm/sec	No data ☐

SPLENIC	**NOT APPLICABLE** ☐		**Stent present in artery (Post-op only):**		**YES** ☐	**NO** ☐
Spl Origin l (SplAO):	PSV:	cm/sec	No data ☐	EDV:	cm/sec	No data ☐
Spl Proximal (SplP):	PSV:	cm/sec	No data ☐	EDV:	cm/sec	No data ☐
Spl Middle (SplM):	PSV:	cm/sec	No data ☐	EDV:	cm/sec	No data ☐
Spl Distal (SplD):	PSV:	cm/sec	No data ☐	EDV:	cm/sec	No data ☐

DUPLEX IMAGING_____

HEPATIC	**NOT APPLICABLE** ☐			**Stent present in artery (Post-op only):**	**YES** ☐	**NO** ☐
Hepatic Origin (HepAO):	PSV:	cm/sec	No data ☐	EDV:	cm/sec	No data ☐
Hepatic Proximal (HepCAP):	PSV:	cm/sec	No data ☐	EDV:	cm/sec	No data ☐
Hepatic Middle (HepM):	PSV:	cm/sec	No data ☐	EDV:	cm/sec	No data ☐
Hepatic Distal (HepD):	PSV:	cm/sec	No data ☐	EDV:	cm/sec	No data ☐

RIGHT KIDNEY	**Kidney absent** ☐	**NOT APPLICABLE** ☐		**Stent present in artery (Post-op only):**	**YES** ☐	**NO** ☐
Right Renal Artery Measurements in Anatomy:						
Origin (RRO):	PSV:	cm/sec	No data ☐	EDV:	cm/sec	No data ☐
Proximal (RRP):	PSV:	cm/sec	No data ☐	EDV:	cm/sec	No data ☐
Middle (RRM):	PSV:	cm/sec	No data ☐	EDV:	cm/sec	No data ☐
Distal (RRD):	PSV:	cm/sec	No data ☐	EDV:	cm/sec	No data ☐
Right Renal to Aortic Ratio (RAR):			No data ☐			
Right Renal Parenchyma Upper Pole Measurements:	PSV:	cm/sec	No data ☐	EDV:	cm/sec	No data ☐
Resistive Index:			No data ☐			
Right Renal Parenchyma Lower Pole Measurements:	PSV:	cm/sec	No data ☐	EDV:	cm/sec	No data ☐
Resistive Index:			No data ☐			
Right Kidney Pole-to-Pole Length Measurement:					cm	No data ☐

ACCESSORY RIGHT RENAL ARTERY	**NOT APPLICABLE** ☐			**Stent present in artery (Post-op only):**	**YES** ☐	**NO** ☐
Origin	PSV:	cm/sec	No data ☐	EDV:	cm/sec	No data ☐
Proximal	PSV:	cm/sec	No data ☐	EDV:	cm/sec	No data ☐
Middle	PSV:	cm/sec	No data ☐	EDV:	cm/sec	No data ☐
Distal	PSV:	cm/sec	No data ☐	EDV:	cm/sec	No data ☐

LEFT KIDNEY	**Kidney absent** ☐	**NOT APPLICABLE** ☐		**Stent present in artery (Post-op only):**	**YES** ☐	**NO** ☐
Left Renal Artery Measurements in Anatomy:						
Origin (RRO):	PSV:	cm/sec	No data ☐	EDV:	cm/sec	No data ☐
Proximal (RRP):	PSV:	cm/sec	No data ☐	EDV:	cm/sec	No data ☐
Middle (RRM):	PSV:	cm/sec	No data ☐	EDV:	cm/sec	No data ☐
Distal (RRD):	PSV:	cm/sec	No data ☐	EDV:	cm/sec	No data ☐
Left Renal to Aortic Ratio (RAR):			No data ☐			
Left Renal Parenchyma Upper Pole Measurements:	PSV:	cm/sec	No data ☐	EDV:	cm/sec	No data ☐
Resistive Index:			No data ☐			
Left Renal Parenchyma Lower Pole Measurements:	PSV:	cm/sec	No data ☐	EDV:	cm/sec	No data ☐
Resistive Index:			No data ☐			
Left Kidney Pole-to-Pole Length Measurement:					cm	No data ☐

ACCESSORY LEFT RENAL ARTERY	**NOT APPLICABLE** ☐			**Stent present in artery (Post-op only):**	**YES** ☐	**NO** ☐
Origin	PSV:	cm/sec	No data ☐	EDV:	cm/sec	No data ☐
Proximal	PSV:	cm/sec	No data ☐	EDV:	cm/sec	No data ☐
Middle	PSV:	cm/sec	No data ☐	EDV:	cm/sec	No data ☐
Distal	PSV:	cm/sec	No data ☐	EDV:	cm/sec	No data ☐

PART IV: OPTIMIZING MID-TERM OUTCOMES; THE ROLE OF FAMILY HISTORY AND PROXIMAL SEALING STRATEGIES

This final part provides insights into how both patient characteristics and technical decisions may affect the durability and success of complex endovascular aortic repair.

In **Chapter 10**, the impact of a positive family history of aortic disease on outcomes after FB-EVAR was assessed. In this multicenter cohort study, 18% of patients (excluding those with connective tissue disorders) reported a positive family history. Patients with a family history underwent surgery at a significantly younger age, which may reflect both earlier disease progression and a greater likelihood of seeking medical attention at an earlier stage. In our study, as in most EVAR reports, a positive family history was more frequently reported among women than men, likely influenced by reporting bias, as women may be more aware of and attentive to family medical histories, a phenomenon well described in cancer research.[28, 29] In our cohort, a positive family history was not associated with greater aneurysm extent, 30-day mortality, or mid-term outcomes, including survival, secondary interventions, and sac enlargement. These findings contrast with some studies of standard EVAR that reported worse outcomes in this group.[30-33] However, results across studies are inconsistent, with different studies linking family history to disease extent, perioperative outcomes, or survival, highlighting the heterogeneity in this field. This points out how little is still understood about the influence of family history and genetic factors on the outcomes of endovascular aneurysm repair. Although it requires additional time and resources, systematic genetic evaluation should be implemented in patients with syndromic features, age of presentation <60 years, a family history of aortic aneurysm or dissection, intracranial or peripheral aneurysms in first-degree relatives, or a history of sudden death at a young age in first- or second-degree relatives.[22] Such an approach would help uncover novel genes and mechanisms underlying aortic disease and enable earlier identification and counseling of high-risk family members. As our understanding grows, this knowledge could be translated into personalized risk profiles and follow-up strategies, facilitating prevention and timely treatment. Especially when combined with other prognostic factors such as sac dynamics and imaging findings.

In **Chapter 11**, supraceliac and infraceliac sealing for FEVAR in juxtarenal and pararenal aneurysms were compared. Interestingly, despite supraceliac sealing being a more complex and technically demanding procedure, no difference in perioperative and five-year mortality was observed between the two groups. Both approaches achieved comparable outcomes overall, which contrasts with several previous studies that

reported higher mortality rates after supraceliac sealing.[34-36] Rates of acute kidney injury, spinal cord ischemia, secondary interventions, and five-year mortality were similar between groups, and sac regression occurred in the majority of patients. These findings suggest that both strategies are safe, although long-term follow-up will be crucial to determine whether a more proximal seal improves durability by reducing late migration and endoleak as the aorta remodels. We hypothesize that in the long-term, sac dynamics with supraceliac sealing will not just be similar to, but more favorable than infraceliac sealing

Looking ahead, if long-term outcomes prove to be as favorable as the mid-term results, supraceliac sealing could become a standard option for many patients. In line with personalized medicine, sealing strategies can then be adapted to each patient by considering prior aortic repairs, anatomy, risk factors, and genetic background, and by deciding together on the most durable approach.

References

1. Prinssen M, Verhoeven EL, Buth J, Cuypers PW, van Sambeek MR, Balm R, et al. A randomized trial comparing conventional and endovascular repair of abdominal aortic aneurysms. N Engl J Med. 2004;351(16):1607-18.
2. De Bruin JL, Baas AF, Buth J, Prinssen M, Verhoeven EL, Cuypers PW, et al. Long-term outcome of open or endovascular repair of abdominal aortic aneurysm. N Engl J Med. 2010;362(20):1881-9.
3. Motta F, Oderich GS, Tenorio ER, Schanzer A, Timaran CH, Schneider D, et al. Fenestrated-branched endovascular aortic repair is a safe and effective option for octogenarians in treating complex aortic aneurysm compared with nonoctogenarians. J Vasc Surg. 2021;74(2):353-62 e1.
4. Greenberg RK, Haulon S, Lyden SP, Srivastava SD, Turc A, Eagleton MJ, et al. Endovascular management of juxtarenal aneurysms with fenestrated endovascular grafting. J Vasc Surg. 2004;39(2):279-87.
5. Alberga AJ, von Meijenfeldt GCI, Rastogi V, de Bruin JL, Wever JJ, van Herwaarden JA, et al. Association of Hospital Volume with Perioperative Mortality of Endovascular Repair of Complex Aortic Aneurysms: A Nationwide Cohort Study. Ann Surg. 2021.
6. Zettervall SL, Dun C, Columbo JA, Mendes BC, Goodney PP, Schanzer A, et al. Fenestrated and Branched Endovascular Aortic Repair and Mortality at Hospitals Without Investigational Device Trials. JAMA Surg. 2025;160(2):153-61.
7. Lobato AC, Rodriguez-Lopez J, Diethrich EB. Learning curve for endovascular abdominal aortic aneurysm repair: evaluation of a 277-patient single-center experience. J Endovasc Ther. 2002;9(3):262-8.
8. Sveinsson M, Sobocinski J, Resch T, Sonesson B, Dias N, Haulon S, et al. Early versus late experience in fenestrated endovascular repair for abdominal aortic aneurysm. J Vasc Surg. 2015;61(4):895-901.
9. Mirza AK, Tenorio ER, Karkkainen JM, Hofer J, Macedo T, Cha S, et al. Learning curve of fenestrated and branched endovascular aortic repair for pararenal and thoracoabdominal aneurysms. J Vasc Surg. 2020;72(2):423-34 e1.
10. Soler RJ, Bartoli MA, Mancini J, Lerussi G, Thevenin B, Sarlon-Bartoli G, et al. Aneurysm sac shrinkage after endovascular repair: predictive factors and long-term follow-up. Ann Vasc Surg. 2015;29(4):770-9.
11. Deery SE, Ergul EA, Schermerhorn ML, Siracuse JJ, Schanzer A, Goodney PP, et al. Aneurysm sac expansion is independently associated with late mortality in patients treated with endovascular aneurysm repair. J Vasc Surg. 2018;67(1):157-64.
12. Bastos Goncalves F, Baderkhan H, Verhagen HJ, Wanhainen A, Bjorck M, Stolker RJ, et al. Early sac shrinkage predicts a low risk of late complications after endovascular aortic aneurysm repair. Br J Surg. 2014;101(7):802-10.
13. Rastogi V, O'Donnell TFX, Marcaccio CL, Patel PB, Varkevisser RRB, Yadavalli SD, et al. One-year aneurysm-sac dynamics are associated with reinterventions and rupture following infrarenal endovascular aneurysm repair. J Vasc Surg. 2024;79(2):269-79.
14. O'Donnell TFX, Deery SE, Boitano LT, Siracuse JJ, Schermerhorn ML, Scali ST, et al. Aneurysm sac failure to regress after endovascular aneurysm repair is associated with lower long-term survival. J Vasc Surg. 2019;69(2):414-22.
15. Wanhainen A, Verzini F, Van Herzeele I, Allaire E, Bown M, Cohnert T, et al. Editor's Choice - European Society for Vascular Surgery (ESVS) 2019 Clinical Practice Guidelines on the Management of Abdominal Aorto-iliac Artery Aneurysms. Eur J Vasc Endovasc Surg. 2019;57(1):8-93.
16. Andraska EA, Phillips AR, Reitz KM, Asaadi S, Dai Y, Tzeng E, et al. Longer follow-up intervals following endovascular aortic aneurysm repair are safe and appropriate after marked aneurysm sac regression. J Vasc Surg. 2022;76(2):454-60.
17. Oderich GS, Forbes TL, Chaer R, Davies MG, Lindsay TF, Mastracci T, et al. Reporting standards for endovascular aortic repair of aneurysms involving the renal-mesenteric arteries. J Vasc Surg. 2021;73(1S):4S-52S.
18. van Tongeren O, Vanmaele A, Rastogi V, Hoeks SE, Verhagen HJM, de Bruin JL. Volume Measurements for Surveillance after Endovascular Aneurysm Repair using Artificial Intelligence. Eur J Vasc Endovasc Surg. 2025;69(1):61-70.
19. Robbi E, Ravanelli D, Allievi S, Raunig I, Bonvini S, Passerini A, et al. Automatic CTA analysis for blood vessels and aneurysm features extraction in EVAR planning. Sci Rep. 2025;15(1):16431.

20. Bouwens E, Vanmaele A, Hoeks SE, Verhagen HJ, Fioole B, Moelker A, et al. Circulating biomarkers of cardiovascular disease are related to aneurysm volume in abdominal aortic aneurysm. Vasc Med. 2023;28(5):433-42.
21. Mazzolai L, Teixido-Tura G, Lanzi S, Boc V, Bossone E, Brodmann M, et al. 2024 ESC Guidelines for the management of peripheral arterial and aortic diseases. Eur Heart J. 2024;45(36):3538-700.
22. Isselbacher EM, Preventza O, Hamilton Black J, 3rd, Augoustides JG, Beck AW, Bolen MA, et al. 2022 ACC/AHA Guideline for the Diagnosis and Management of Aortic Disease: A Report of the American Heart Association/American College of Cardiology Joint Committee on Clinical Practice Guidelines. Circulation. 2022;146(24):e334-e482.
23. Chaikof EL, Dalman RL, Eskandari MK, Jackson BM, Lee WA, Mansour MA, et al. The Society for Vascular Surgery practice guidelines on the care of patients with an abdominal aortic aneurysm. J Vasc Surg. 2018;67(1):2-77 e2.
24. Wanhainen A VHI, Bastos-Goncalves F, Bellmunt-Montoya S, Berard X, Boyle JR, et al. Editor's Choice: European Society for Vascular Surgery (ESVS) 2024 clinical practice guidelines on the management of abdominal aorto-iliac artery aneurysms. Eur J Vasc Endovasc Surg. 2024;67(2):192-331.
25. Gargiulo M, Gallitto E, Serra C, Freyrie A, Mascoli C, Bianchini Massoni C, et al. Could four-dimensional contrast-enhanced ultrasound replace computed tomography angiography during follow up of fenestrated endografts? Results of a preliminary experience. Eur J Vasc Endovasc Surg. 2014; 48(5):536-42.
26. Perini P, Sediri I, Midulla M, Delsart P, Gautier C, Haulon S. Contrast-enhanced ultrasound vs. CT angiography in fenestrated EVAR surveillance: a single-center comparison. J Endovasc Ther. 2012; 19(5):648-55.
27. Kordzadeh A, Askari A, Abbassi OA, Sanoudos N, Mohaghegh V, Shirvani H. Artificial intelligence and duplex ultrasound for detection of carotid artery disease. Vascular. 2023;31(6):1187-93.
28. Ozanne EM, O'Connell A, Bouzan C, Bosinoff P, Rourke T, Dowd D, et al. Bias in the reporting of family history: implications for clinical care. J Genet Couns. 2012;21(4):547-56.
29. Sieverding M, Arbogast AL, Zintel S, von Wagner C. Gender differences in self-reported family history of cancer: A review and secondary data analysis. Cancer Med. 2020;9(20):7772-80.
30. van de Luijtgaarden KM, Bastos Goncalves F, Hoeks SE, Majoor-Krakauer D, Rouwet EV, Stolker RJ, et al. Familial abdominal aortic aneurysm is associated with more complications after endovascular aneurysm repair. J Vasc Surg. 2014;59(2):275-82.
31. Ryer EJ, Garvin RP, Thomas B, Kuivaniemi H, Franklin DP, Elmore JR. Patients with familial abdominal aortic aneurysms are at increased risk for endoleak and secondary intervention following elective endovascular aneurysm repair. J Vasc Surg. 2015;62(5):1119-24 e9.
32. Brown CR, Greenberg RK, Wong S, Eagleton M, Mastracci T, Hernandez AV, et al. Family history of aortic disease predicts disease patterns and progression and is a significant influence on management strategies for patients and their relatives. J Vasc Surg. 2013;58(3):573-81.
33. van de Luijtgaarden KM, Bastos Goncalves F, Hoeks SE, Blankensteijn JD, Bockler D, Stolker RJ, et al. Higher 30 Day Mortality in Patients with Familial Abdominal Aortic Aneurysm after EVAR. Eur J Vasc Endovasc Surg. 2017;54(2):142-9.
34. Mastracci TM, Eagleton MJ, Kuramochi Y, Bathurst S, Wolski K. Twelve-year results of fenestrated endografts for juxtarenal and group IV thoracoabdominal aneurysms. J Vasc Surg. 2015;61(2):355-64.
35. Patel SD, Constantinou J, Simring D, Ramirez M, Agu O, Hamilton H, et al. Results of complex aortic stent grafting of abdominal aortic aneurysms stratified according to the proximal landing zone using the Society for Vascular Surgery classification. J Vasc Surg. 2015;62(2):319-25 e2.
36. British Society for Endovascular T, the Global Collaborators on Advanced Stent-Graft Techniques for Aneurysm Repair R. Early results of fenestrated endovascular repair of juxtarenal aortic aneurysms in the United Kingdom. Circulation. 2012;125(22):2707-15.



Appendices

Nederlandse samenvatting
List of publications
PhD portfolio
Dankwoord
Curriculum vitae

Nederlandse samenvatting

De opbouw van dit proefschrift en de achtergrond van het onderzoek worden beschreven in **hoofdstuk 1.** De aorta is de grootste slagader van het lichaam en bestaat uit vijf segmenten: de aortawortel, de aorta ascendens, de aortaboog, aorta descendens en de abdominale aorta. Een aorta-aneurysma is een verwijding van minimaal 1,5 keer de normale diameter. Het abdominale aorta-aneurysma (AAA) komt veel voor, met een wereldwijde prevalentie van ongeveer 4,8%. De meeste AAA's geven geen klachten, wanneer dat wel het geval is, gaat het vaak om rugklachten of buikpijn, of in het ergste geval een ruptuur.

Sinds de introductie van endovasculaire aneurysma-reparatie (EVAR) in 1991 is deze minimaal invasieve techniek de standaardbehandeling geworden voor AAA's met een geschikte anatomie. Voor complexere aneurysma's, waarbij de nier- en viscerale arteriën bij de behandeling betrokken zijn, zijn gefenestreerde en branched endovasculaire technieken (FB-EVAR) ontwikkeld. Dit proefschrift onderzoekt de uitkomsten van complexe aorta-aneurysma's behandeld met FB-EVAR, in een tijd waarin dit vakgebied zich snel ontwikkelt.

Deel 1 beschrijft de klinische en technische achtergrond van complexe endovasculaire aortareparatie. **Hoofdstuk 2** geeft een uitgebreid overzicht van de endovasculaire behandeling van thoraco-abdominale aorta-aneurysmata (TAAA's), inclusief de pathofysiologie, epidemiologie en het peri-, intra- en postoperatieve management, met bijzondere aandacht voor het voorkomen van myelumischemie, een van de meest gevreesde complicaties van TAAA-behandeling.

Hoofdstuk 3 biedt een overzicht van de meest voorkomende technische, intraoperatieve complicaties tijdens standaard EVAR en FB-EVAR. Complicaties werden onderverdeeld in problemen met de vaattoegang, de zijtakken (*target vessels*), en graftgerelateerde problemen. Hoewel deze ingrepen steeds verder zijn gestandaardiseerd, blijven technische problemen voorkomen, zeker bij complexere anatomie. Vroege herkenning en direct handelen tijdens de procedure bleken essentieel om de impact van deze complicaties te beperken.

Hoofdstuk 4 beschrijft de technische uitdagingen en voorgestelde aanpassingen aan de *"Instructions for Use"* bij het gebruik van de Gore Excluder Conformable-stentgraft bij een sterk geanguleerde proximale hals (75°). Bij dergelijke anatomie biedt de standaard voorgeschreven techniek onvoldoende steun, met risico op onnauwkeurige plaatsing. Voorgestelde aanpassingen waren onder andere pre-catheterisatie van de

laagste nierarterie, het hoger houden van de sheath ter ondersteuning (in plaats van deze volledig terug te trekken), gebruik van een stugge voerdraad om distale migratie te voorkomen, en het ballonneren van de proximale hals vóór het terugtrekken van het *deliverysysteem*. Deze stappen worden niet aanbevolen voor elke procedure, maar bieden potentieel voordeel bij patiënten met een korte en sterk geanguleerde hals, al blijft zorgvuldige patiëntselectie essentieel en is langere follow-up nodig.

Deel II richt zich op de ontwikkeling van het aneurysma na behandeling met FB-EVAR. Hierbij worden zowel veranderingen in de aneurysmadiameter als in het aneurysmavolume onderzocht. Succesvolle behandeling wordt gekenmerkt door volledige exclusie van het aneurysma, wat doorgaans resulteert in een regressie of stabilisatie van het aneurysma. Een stabiel of krimpend aneurysma wordt na EVAR gezien als belangrijke voorspeller voor betere uitkomsten, waaronder overleving en minder re-interventies.

Hoofdstuk 5 onderzocht de invloed van veranderingen in de aneurysmadiameter na één jaar op de overleving van 463 patiënten na FB-EVAR. Bij 58% van de patiënten trad binnen een jaar krimp van het aneurysma op: deze groep had een significant betere vijfjaarsoverleving (69%) dan patiënten zonder krimp van het aneurysma (46%). Opvallend was dat het aantal aorta-gerelateerde sterfgevallen en rupturen in beide groepen laag en vergelijkbaar was. Dit suggereert dat het uitblijven van krimp van het aneurysma een signaal is voor niet-aorta-gerelateerde sterfte (bijvoorbeeld door verminderde algehele conditie (*frailty)* of comorbiditeit dan voor een verhoogd ruptuurrisico zelf.

Hoofdstuk 6 onderzocht bij 165 patiënten de prognostische betekenis van veranderingen in het aneurysmavolume na FB-EVAR en vergeleek de uitkomsten na FEVAR (122 patiënten) en BEVAR (43 patiënten). Het uitblijven van krimp van het aneurysma na één jaar ging gepaard met een hoger risico op vijfjaars *all-cause* mortaliteit en graft-gerelateerde complicaties. Een eerdere aortareparatie en een grotere preoperatieve aneurysmadiameter waren geassocieerd met het uitblijven van regressie, terwijl een geschiedenis van roken juist geassocieerd was met krimp van het aneurysma. Na FEVAR liet 66% van de patiënten krimp zien van het aneurysma na een jaar, terwijl na BEVAR 28% juist aneurysma groei toonde. Dit kan wijzen op een behoefte aan intensievere surveillance na BEVAR.

Hoofdstuk 7 onderzocht de duurzaamheid van FEVAR als behandeling voor een eerdere (gefaalde) EVAR, bij 196 patiënten waarvan 53 een eerdere EVAR hadden ondergaan. Patiënten met een eerdere EVAR waren ouder en hadden een hoger risico op aorta-gerelateerde re-interventies binnen vijf jaar, zonder dat dit de vijfjaarsoverleving beïnvloedde. Wel lieten zij vaker aneurysma groei zien (48% versus 8% bij primaire

FEVAR) en minder vaak regressie (23% versus 77%). Dit patroon hield aan over de tijd, het aneurysma bleef groeien bij patiënten die eerder een EVAR hadden ondergaan, terwijl deze juist afnam bij patiënten die primair met FEVAR waren behandeld.

Levenslange surveillance aan de hand van beeldvorming is noodzakelijk na FB-EVAR om complicaties tijdig te detecteren. Hoewel computertomografie-angiografie (CTA) de hoeksteen blijft van deze follow-up, kan duplex-echografie (DUS) als niet-invasieve, aanvullende methode worden gebruikt. **Deel III** gaat over DUS surveillance na complexe aorta-aneurysma reparatie. DUS kan hemodynamische veranderingen binnen de stents detecteren, met name waardevol bij kleine vaten, waar metaalartefacten een CTA-beoordeling beperken. Voor natieve vaten bestaan al criteria om stenose vast te stellen, maar voor gestente vaten ontbreekt deze nog.

Hoofdstuk 8 beschreef de (vroeg) postoperatieve veranderingen in PSV bij 419 patiënten met 1.411 gestente nier- en viscerale vaten, gemeten preoperatief en 6-8 weken na FB-EVAR. Hoewel PSV in het midden-segment licht toenam, bleven alle waarden ruim onder de drempelwaarde voor klinisch relevante stenose. Opvallender was de subanalyse: vaten behandeld met fenestraties lieten een significante toename in PSV zien, terwijl vaten behandeld met branches een significante afname toonden, een verschil dat vermoedelijk samenhangt met de stentlengte en stroomrichting, maar ook bij deze groepen klinisch niet significant was. De bevindingen leveren referentiewaarden op voor de verwachte PSV na het stenten van nier- en viscerale vaten tijdens FB-EVAR.

Hoofdstuk 9 volgde dezelfde patiënten longitudinaal tot vijf jaar en vergeleek het verloop van PSV tussen branches en fenestraties in de nier- en viscerale arteriën. Bij branches daalde de PSV initieel, stabiliseerde zich, en steeg licht maar niet-significant na vijf jaar. Bij fenestraties steeg de PSV binnen de eerste zes maanden en bleef structureel hoger dan bij branches, consistent met de bevindingen uit **hoofdstuk 8**. In viscerale vaten hadden *balloon-expandable stentgrafts* (BESGs) hogere PSV-waarden dan *self-expandable stentgrafts* (SESGs), mogelijk door de hogere radiaalkracht van BESGs. Alle waarden bleven onder de drempelwaarde voor significante stenose in natieve vaten. Van de 31 vaten die een re-interventie ondergingen wegens stenose had 83% een PSV boven de drempelwaarde voor natieve vaten. Echter, ook tientallen vaten zonder re-interventie overschreden deze drempel op enig moment, wat bevestigt dat PSV alleen niet leidend mag zijn bij de beslissing tot re-interventie. Voor gestente nierarteriën bleek PSV een sterke voorspeller van klinisch relevante stenose (AUC 0,98), met een drempelwaarde van 231 cm/s (sensitiviteit 84%, specificiteit 100%),

hoger dan de gangbare 200 cm/s voor natieve vaten. Echter, is validatie in prospectief onderzoek nodig.

In **deel IV** worden twee specifieke factoren onderzocht die mogelijk de uitkomsten na FB-EVAR beïnvloeden. Enerzijds de rol van een familiaire belasting voor aorta-aandoeningen, een bekende risicofactor voor het ontstaan van aneurysma's, maar met onduidelijke invloed op de uitkomsten. Anderzijds de keuze van het proximale sealingniveau tijdens FEVAR, waarbij centra steeds vaker kiezen voor een hogere, supracoeliacale sealing om de duurzaamheid van de reparatie te vergroten.

Hoofdstuk 10 onderzocht de invloed van een familiaire belasting voor aorta-aandoeningen op de uitkomsten na FB-EVAR, in de multicenter database van het *United States Aortic Research Consortium* (2.355 patiënten, waarvan 427 met een positieve familieanamnese). Patiënten met een positieve familieanamnese waren jonger, vaker vrouw, en hadden vaker een eerdere open AAA-behandeling ondergaan dan patiënten zonder familiaire belasting. Er werd echter geen significant verschil gevonden in 30-dagen mortaliteit (4% versus 2%) of *major adverse events* (12% versus 12%) tussen beide groepen. Ook op de langere termijn waren de driejaarsoverleving (71% in beide groepen), re-interventies en aneurysmazak groei vergelijkbaar tussen de groepen. Deze bevindingen suggereren dat, in afwezigheid van een aangetoonde genetische aandoening, de behandelkeuze voor complexe aorta-aneurysma's gebaseerd moet worden op klinisch risico en anatomische geschiktheid, en niet op de aanwezigheid van een familiaire belasting.

Hoofdstuk 11 vergeleek bij 167 patiënten met juxtarenale AAA's de uitkomsten van supracoeliacale (89 patiënten) versus infracoeliacale sealing (78 patiënten) tijdens FEVAR. Supracoeliacale sealing werd vaker toegepast bij patiënten met een eerdere EVAR. De procedures met supracoeliacale sealing duurden langer en waren technisch complexer, maar dit leidde niet tot meer perioperatieve complicaties zoals myelumischemie, acute nierinsufficiëntie of mortaliteit. Wel ontstonden type 3c endoleaks uitsluitend bij patiënten met supracoeliacale sealing (6,7% versus 0,0%), afkomstig van de nierarteriën. Dit is mogelijk te verklaren door de technische uitdagingen bij het cannuleren van zijtakken (*target vessels)*, met name in aanwezigheid van een eerder geplaatste graft (zoals een eerdere EVAR). Op de middellange termijn waren de uitkomsten vergelijkbaar: er werd geen significant verschil gevonden in aneurysmazak dynamiek na één jaar, vijf jaar re-interventie, vijfjaarsoverleving, of het groeien of krimpen van het aneurysma over tijd. Zelfs na correctie voor rookgedrag, ASA-klasse en eerdere EVAR bleven deze bevindingen hetzelfde. Theoretisch zou een hogere,

proximalere sealing op de langere termijn voordeel kunnen bieden, omdat sealingzones na verloop van tijd dilateren. Dit potentiële voordeel kon in deze studie nog niet worden aangetoond en zal moeten worden bevestigd in studies met een langere follow-up dan vijf jaar.

List of publications

Figueroa, A. V., Tanenbaum, M. T., Costa Filho, J. E., Coronel, N. I., Gonzalez, M. S., Kanamori, L. R., **Sulzer, T.**, Mesnard, T., Huang, Y., Gonzalez-Guardiola, G., Baig, M. S., Oderich, G., & Timaran, C. H. (2025). Landing zones optimization using transcatheter electrosurgical septotomy for endovascular repair of post-dissection aortic aneurysms. *Journal of vascular surgery*, S0741-5214(25)01571-X. Advance online publication. https://doi.org/10.1016/j.jvs.2025.07.055

Sulzer, T. A. L., de Bruin, J. L., Rastogi, V., Boer, G. J., Ultee, K. H. J., Fioole, B., Oderich, G. S., Schermerhorn, M. L., & Verhagen, H. J. M. (2024). Peri-operative and Midterm Results of Supracoeliac vs. Infracoeliac Sealing for Fenestrated Endovascular Aortic Repair of Juxtarenal Aortic Aneurysms. *European journal of vascular and endovascular surgery*, S1078-5884(24)00975-4. https://doi.org/10.1016/j.ejvs.2024.11.019

Vacirca, A., Mesnard, T., Huang, Y., Mendes, B. C., Jakimowicz, T., Schneider, D. B., Haulon, S., Sobocinski, J., Beck, A. W., Schanzer, A., Farber, M. A., Timaran, C., Kahlberg, A., Kölbel, T., Gasper, W. J., Mees, B. M. E., Gargiulo, M., Dias, N. V., Woongchae, A. L., Sweet, M. P., … International Multicenter Aortic Research Group (2025). Predictors of failure to rescue after fenestrated-branched endovascular aortic repair of thoracoabdominal aortic aneurysms. *Journal of vascular surgery*, S0741-5214(25)00358-1. Advance online publication. https://doi.org/10.1016/j.jvs.2025.02.032

Baghbani, A., Savadi, S., Sulzer, **T. A. L.**, Tenorio, E. R., Mesnard, T., Vacirca, A., Mendes, B. C., Saqib, N. U., Maximus, S., Huang, Y., & Oderich, G. S. (2026). Familial History of Aortic Disease Does Not Affect Outcomes of Fenestrated-Branched Endovascular Aortic Repair in Patients With Complex Aortic Aneurysms. *Journal of endovascular therapy*, 15266028261417156. Advance online publication. https://doi.org/10.1177/15266028261417156

Wong, J., Mesnard, T., Vacirca, A., George, M., Goel, V., Sulzer, **T. A. L.**, Huang, Y., Tenorio, E. R., Skibber, M., Maximus, S., & Oderich, G. S. (2024). Intraoperative Position System guided with Augmented Reality Improves the Learning Curve of Endovascular Navigation in Endovascular Naïve Operators. *Journal of vascular surgery*, S0741-5214(24)02031-7. https://doi.org/10.1016/j.jvs.2024.10.074

Jobim, F., Ruiter Kanamori, L., Cambiaghi, M., Mesnard, T., **Sulzer, T. A.**, Savadi, S., Babocs, D., Pagnin Schmid, B., Maximus, S., Huang, Y., Verzini, F., & Oderich, G. S. (2024). Tabular review of contemporary fenestrated-branched endovascular aortic repair experiences

for treatment of thoracoabdominal aortic aneurysms. *The Journal of cardiovascular surgery*, 10.23736/S0021-9509.24.13168-0. Advance online publication. https://doi.org/10.23736/S0021-9509.24.13168-0

Cambiaghi, M., Ruiter Kanamori, L., Jobim, F., Mesnard, T., **Sulzer, T. A.**, Babocs, D., Maximus, S., Huang, Y., Verzini, F., & Oderich, G. S. (2024). Tabular review of contemporary open surgical repair experiences for treatment of thoracoabdominal aortic aneurysms. *The Journal of cardiovascular surgery*, 10.23736/S0021-9509.24.13167-9. Advance online publication. https://doi.org/10.23736/S0021-9509.24.13167-9

Mesnard, T., **Sulzer, T. A. L.**, Kanamori, L. R., Babocs, D., Vacirca, A., Baghbani-Oskouei, A., Savadi, S., Tenorio, E. R., Mirza, A., Saqib, N., Mendes, B., Macedo, T., Verhagen, H. J. M., Huang, Y., & Oderich, G. S. (2024). Aneurysm sac shrinkage at 1 year after fenestrated-branched endovascular aortic repair of complex aortic aneurysms offers mid-term survival advantage. *Journal of vascular surgery*, S0741-5214(24)01233-3. Advance online publication. https://doi.org/10.1016/j.jvs.2024.05.054

Tanenbaum, M. T., Figueroa, A. V., Kanamori, L. R., Costa Filho, J. E., Soto Gonzalez, M., **Sulzer, T.**, Mesnard, T., Huang, Y., Baig, M. S., Oderich, G. S., & Timaran, C. H. (2024). Early experience with patient-specific unibody bifurcated fenestrated-branched devices for complex endovascular aortic aneurysm repair. *Journal of vascular surgery*, S0741-5214(24)01337-5. Advance online publication. https://doi.org/10.1016/j.jvs.2024.06.020.

Sulzer, T. A. L., Mesnard, T., Schanzer, A., Timaran, C. H., Schneider, D. B., Farber, M. A., Beck, A. W., Huang, Y., Oderich, G. S., & United States Aortic Research Consortium (2024). Effect of Family History of Aortic Disease on Outcomes of Fenestrated/Branched Endovascular Aneurysm Repair of Complex Aortic Aneurysms. *European journal of vascular and endovascular surgery*, S1078-5884(24)00389-7. Advance online publication. https://doi.org/10.1016/j.ejvs.2024.05.011

Baghbani-Oskouei, A., Savadi, S., Mesnard, T., **Sulzer, T.**, Mirza, A. K., Baig, S., Timaran, C. H., & Oderich, G. S. (2023). Transcatheter electrosurgical septotomy technique for chronic postdissection aortic aneurysms. *Journal of vascular surgery cases and innovative techniques*, 10(2), 101402. https://doi.org/10.1016/j.jvscit.2023.101402

Mesnard, T., Vacirca, A., Baghbani-Oskouei, A., Sulzer, **T. A. L.**, Savadi, S., Kanamori, L. R., Tenorio, E. R., Mirza, A., Saqib, N., Mendes, B. C., Huang, Y., & Oderich, G. S. (2024). Prospective evaluation of upper extremity access and total transfemoral approach during fenestrated and branched endovascular repair. *Journal of vascular surgery*, 79(5), 1013-1023.e3. https://doi.org/10.1016/j.jvs.2023.1

Sulzer, T. A. L., de Bruin, J. L., Rastogi, V., Boer, G. J., Mesnard, T., Fioole, B., Rijn, M. J. V., Schermerhorn, M. L., Oderich, G. S., & Verhagen, H. J. M. (2024). Midterm Outcomes and Aneurysm Sac Dynamics Following Fenestrated Endovascular Aneurysm Repair after Previous Endovascular Aneurysm Repair. *European journal of vascular and endovascular surgery*, S1078-5884(24)00097-2. Advance online publication. https://doi.org/10.1016/j.ejvs.2024.01.070

Rastogi, V., Sulzer, **T. A. L.**, de Bruin, J. L., Oliveira-Pinto, J., Alberga, A. J., Hoeks, S. E., Bastos Goncalves, F., Ten Raa, S., Josee van Rijn, M., Akkersdijk, G. P., Fioole, B., & Verhagen, H. J. M. (2023). Aneurysm Sac Dynamics and its Prognostic Significance Following Fenestrated and Branched Endovascular Aortic Aneurysm Repair. *European journal of vascular and endovascular surgery*, S1078-5884(23)00963-2. https://doi.org/10.1016/j.ejvs.2023.11.033.

Sulzer, T. A. L., Vacirca, A., Mesnard, T., Baghbani-Oskouei, A., Savadi, S., Kanamori, L. R., van Lier, F., de Bruin, J. L., Verhagen, H. J. M., & Oderich, G. S. (2023). How We Would Treat Our Own Thoracoabdominal Aortic Aneurysm. *Journal of cardiothoracic and vascular anesthesia*, S1053-0770(23)00896-0. Advance online publication. https://doi.org/10.1053/j.jvca.2023.10.034.

Michels, E. H. A., Appelman, B., de Brabander, J., van Amstel, R. B. E., van Linge, C. C. A., Chouchane, O., Reijnders, T. D. Y., Schuurman, A. R., **Sulzer, T. A. L.**, Klarenbeek, A. M., Douma, R. A., Bos, L. D. J., Wiersinga, W. J., Peters-Sengers, H., van der Poll, T., & Amsterdam UMC COVID-19 biobank study group (2023). Host Response Changes and Their Association with Mortality in COVID-19 Patients with Lymphopenia. *American journal of respiratory and critical care medicine*, 10.1164/rccm.202305-0890OC. Advance online publication. https://doi.org/10.1164/rccm.202305-0890OC.

Vacirca, A., **Sulzer, T. A. L.**, Mesnard, T., Baghbani-Oskouei, A., Ocasio, L., Macedo, T. A., Verhagen, H. J. M., Rhee, R., & Oderich, G. S. (2023). Technical pitfalls and proposed modifications of instructions for use for endovascular aortic aneurysm repair using the Gore Excluder conformable device in angulated and short landing zones. *Journal of vascular surgery cases and innovative techniques*, 9(4), 101339. https://doi.org/10.1016/j.jvscit.2023.101339.

Sulzer, T. A. L., Macedo, T. A., Strissel, N., Hesley, G. K., Lekah, A., Tallarita, T., Dias-Neto, M., Huang, Y., Tenorio, E. R., Vacirca, A., Mesnard, T., Baghbani-Oskouei, A., Savadi, S., de Bruin, J. L., Verhagen, H. J. M., Mendes, B., & Oderich, G. S. (2023). Changes in renal-mesenteric duplex ultrasound velocities after fenestrated and branched endovascular

aortic aneurysm repair. *Journal of vascular surgery*, 78(5), 1162-1169.e2. https://doi.org/10.1016/j.jvs.2023.06.106.

Vacirca, A., Wong, J., Baghbani-Oskouei, A., Tenorio, E. R., Huang, Y., Mirza, A., Saqib, N., **Sulzer, T.**, Mesnard, T., Mendes, B. C., & Oderich, G. S. (2023). Outcomes of fenestrated-branched endovascular aortic repair in patients with or without prior history of abdominal endovascular or open surgical repair. *Journal of vascular surgery*, 78(2), 278-288.e3. https://doi.org/10.1016/j.jvs.2023.04.001.

Tenorio, E. R., Vacirca, A., Mesnard, T., **Sulzer, T.**, Baghbani-Oskouei, A., Mirza, A. K., Huang, Y., & Oderich, G. S. (2023). Technical tips and clinical experience with the Cook Triple inner arch branch stent-graft. *The Journal of cardiovascular surgery*, 64(1), 9-17. https://doi.org/10.23736/S0021-9509.22.12569-3.

Vacirca, A., Tenorio, E. R., Mesnard, T., **Sulzer, T.**, Baghbani-Oskouei, A., Mirza, A. K., Huang, Y., & Oderich, G. S. (2023). Technical tips and clinical experience with the Gore Thoracic Branch Endoprosthesis®. *The Journal of cardiovascular surgery*, 64(1), 18-25. https://doi.org/10.23736/S0021-9509.22.12564-4.

Sulzer, T., Tenorio, E. R., Mesnard, T., Vacirca, A., Baghbani-Oskouei, A., de Bruin, J. L., Verhagen, H. J. M., & Oderich, G. S. (2023). Intraoperative complications during standard and complex endovascular aortic repair. *Seminars in vascular surgery*, 36(2), 189-201. https://doi.org/10.1053/j.semvascsurg.2023.04.002.

PhD portfolio

Erasmus University Rotterdam



Titia Anna Louise Sulzer

02-01-1998

Faculteit der Geneeskunde en Gezondheidswetenschappen, 16-07-2026

Description	Organizer	EC
Required		
Excel Course - Basic (2022)		1.00
Rstudio course (2022)		1.00
Meeting: Critical Issues Miami 2023 - Poster presentation (2023)		1.50
Presenting for Medical Students about Vascular Surgery Research (2023)		1.50
Meeting; Houston Aortic Symposium 2023 (2023)		1.50
Meeting: Vascular Annual Meeting 2023 Oral presentation + Poster (2023)		4.00
Presenting at the Vascular Research Meeting at UTHealth Houston (5 times) (2023)		1.00
Meeting: ESVS Annual Meeting 2023 - Three oral presentations (2023)		6.00
Supervising a master student (thesis) (2024)		3.00
Meeting: Vaatdagen 2024 Oral presentation (2024)		2.00
Writing a book chapter on Chronic Mesenteric Ischemia (2024)		3.00
Scientific Integrity (2024)	Erasmus MC Graduate School	0.30
Presenting at the Regional Vascular Rounds of Rotterdam (2024)		1.00
Meeting: Vaatdagen 2025 Oral presentation (2025)		2.00
Presenting at the Vascular Research Meeting Erasmus MC (8 times) (2025)		1.50
Meeting: ESVS Annual Meeting 2025 - Oral presentation (2025)		2.00
		--------- +
Total EC		**32.30**

Dankwoord

De totstandkoming van dit proefschrift was zonder twijfel een gezamenlijke inspanning. De kennis, het enthousiasme, de inzet, de aandacht, het grote geduld en de steun van velen in de afgelopen vier jaar blijven in de overige hoofdstukken grotendeels op de achtergrond. Daarom wil ik in dit hoofdstuk een aantal mensen in het bijzonder bedanken.

Geachte **promotor, prof. dr. Verhagen,** beste **Hence,** ik kan mij onze eerste ontmoeting nog goed herinneren: de sollicitatie voor een wetenschapsstage, noodgedwongen online vanwege COVID-19. We bleken meteen iets gemeen te hebben, u was immers ook ooit spoorstudent, en het klikte direct. Mijn interesse in de vaatchirurgie en mijn wens om naar de VS te gaan werden door u nuchter ontvangen met: "Wie wil dat niet?" Wat begon als een leuk project in het Erasmus MC, kreeg al snel een onverwacht vervolg toen ik enkele maanden later werd gebeld met de mogelijkheid om een jaar naar Houston te gaan. Mijn keuze was snel gemaakt; het avontuur begon nog voordat mijn stage was gestart. Alles wat u mij destijds vertelde over een jaar in het buitenland is uitgekomen. Het was een buitengewone ervaring, en ik ben u zeer dankbaar voor het vertrouwen dat u mij toen heeft gegeven. Bij alle projecten bent u betrokken geweest, steeds met een scherp oog voor detail en met waardevolle, rake inzichten. Daarnaast waardeer ik uw grote bereikbaarheid en betrokkenheid enorm, iets wat niet vanzelfsprekend is. Ons contact is altijd enthousiast en positief geweest, en vaak blijken we op één lijn te zitten. Kortom: ik heb veel geluk gehad.

Dear **Professor Oderich,** thank you for your mentorship over the past few years. I joined the research team in Houston as the only student among research fellows, most of whom were vascular surgeons, yet you never treated me any differently. The learning curve was steep and kept rising; before I knew it, I was presenting cases and publishing articles. The year flew by. I do not know anyone as busy as you, yet still so focused in everything you do. Observing your meticulous work ethic, dedication to patient care, and the way you interact with those around you has been truly inspiring. Even more remarkable is that, above all, you are a devoted family person. I am grateful for the trust you placed in me. Thanks to that trust, I grew not only in independence, skills, and discipline, but also in confidence, something that will stay with me throughout my career. And to top it all off, just a few months ago, we were celebrating your own PhD defense. I doubt many PhD students can say they defended in the same year as their mentor. What a special year it has been!

Geachte **co-promotor,** beste **dr. de Bruin,** beste **Jorg,** ik heb mij aan de afspraak gehouden. Tijdens een van onze eerste gesprekken over Houston had jij mijn planning al uitgetekend: tegelijkertijd zou ik afstuderen én promoveren. Hoewel ik wist dat promotieonderzoek vaak langer duurt dan je hoopt, is het ons toch gelukt. Dank je wel dat je altijd bereikbaar bent om te sparren, zowel over onderzoek als daarbuiten. Bij elk project ben je nauw betrokken geweest, en door de vele teams-meetings voelde het soms alsof je zelf ook in Amerika zat. Mijn collega's in Houston vroegen zich regelmatig af wie toch die "Jorg" was waar ik het steeds over had. Mooi dat we daarnaast ook samen hebben kunnen werken aan de METC-aanvraag voor vrouwen met AAA's. Ik hoop dat we in de toekomst nog veel zullen samenwerken.

Dear **Professor Macedo,** I really appreciate the time we got to spend together on the ultrasound projects. All the numbers and science behind ultrasound often made my head spin, but you have a remarkable way of making complex topics feel accessible. With your patience and guidance, you became one of my most valued mentors, and together we were able to write two articles, the second even more challenging than the first. Working with you has not only been a valuable professional experience but has also sparked a genuine interest in radiology for me (who knows!). Looking back on my time in Houston, I feel especially grateful for how welcome you and Dr. Oderich made me feel. This has left a lasting impression on me.

Dear **co-promotor**, dear **dr. Mesnard, Frenchie**, we arrived at the same time in Houston, you with some more experience and knowledge than I had. It took us a couple of weeks to get along, but we became a great team. You taught me a lot about vascular surgery and helped me out so many times. Every manuscript I wrote was reviewed by you on correct use of the stents, deployment technique and logic. You even had to help me with all my legend titles one day. And actually, you are not the most patient person. Day in day out we were tweaking our models in Rstudio, in our cubicles. It was a great year. I am also very grateful that Nino and I could be part of a special moment this year: celebrating your wedding with Justine in France. I'm happy we are still in touch, and I hope it will stay that way.

Geachte **leden van de leescommissie, prof. dr. Kardys, prof. dr. Blankensteijn** en **prof. dr. Mees**, dank voor de tijd die u heeft genomen om dit proefschrift te lezen en te beoordelen. Geachte **prof. dr. Roos-Hesselink** en **drs. Lelij,** dank dat u zitting neemt in mijn promotiecommissie. Ik kijk uit naar een interessante discussie tijdens mijn verdediging.

Julie en **Pim,** mijn lieve **paranimfen**. Juul, zonder jouw overtuigingskracht was ik überhaupt nooit geneeskunde gaan studeren. Ik blijf me verwonderen over hoe

altruïstisch jij bent en hoe je altijd klaarstaat voor anderen. Pim, zonder jou had ik de bachelor waarschijnlijk niet afgemaakt. Vanaf het allereerste hoorcollege hadden we een klik, en die vriendschap is sindsdien uitgegroeid tot iets heel moois, waar ik heel dankbaar voor ben. Vanaf het begin hebben jullie mijn PhD gevolgd en waren jullie altijd behulpzaam en geïnteresseerd. Ik had niemand anders kunnen kiezen voor deze taak.

Dear **Professor Huang,** I don't know anyone who is as focused or has such an exceptional eye for detail as you. In every manuscript you were able to spot even the smallest errors and inconsistencies. Working with you taught me the importance of consistency, not only in carefully maintaining databases, but also in keeping manuscripts structured from beginning to end. These are lessons that have stayed with me throughout my PhD. And of course, thank you for introducing me to some of Houston's finest Chinese restaurants. I still think about those mooncakes. **Andrea,** you are in fact the most patient person I've met. We've got to know each other quite fast, by sharing a workspace of 1 m^2. You basically taught me everything I had to know to start working in Houston, the databases, the videos, the early mornings with SphygmoCor (which if I'm correct is still your project), the nanodots, the best coffee spots in Houston for espresso macchiato (not many), and the deepfried pizza. Thank you for all the time and energy you put into that. Hopefully we meet again soon in Galveston, since this is your favorite beach in the world. **Aidin, Safa, Lucas R, Lucas K, Dora,** dear team, what a wonderful year we shared in Houston. We worked on great projects together, but what I will remember most is the time we spent as a group. From carefully collecting data in the control room during surgeries to laughing our way through the peculiarities of Texan culture. I share so many great memories with all of you, together with **Aida**: the Houston Rodeo, Friday evenings at Bailesons Brewery, Thanksgiving 'friend-grilling', and many more. Thank you for making Houston feel like a second home. I hope our paths will cross again soon.

Beste **dr. Van Tongerlo-van Rijn, dr. Ten Raa** en **dr. Van der Wilden**, dank voor jullie altijd scherpe vragen en waardevolle input tijdens de research meetings.

Vinamr, vanaf het allereerste moment was jij erbij. Jij hebt mij vrijwel alles geleerd wat ik nodig had om aan mijn PhD te beginnen. De manier waarop jij een database had opgebouwd en meer dan 30 artikelen had geschreven, gaf mij motivatie, maar de lat lag wel hoog! Maandenlang hebben we Teams-meetings gehad (jij vanuit Boston), en je maakte altijd tijd vrij wanneer ik weer eens vastliep. Dank voor al je tijd en betrokkenheid. Zonder jou was dit boekje er niet geweest! **David, Olivier, Alexander**, jullie zijn alle drie veel beter in statistiek (en computers in het algemeen) dan ik, en telkens wanneer ik vastliep stonden jullie klaar om te helpen. Ook de altijd gezellige research

meetings, soms afgesloten door een etentje, en natuurlijk de congressen in Belfast en Istanbul waren hoogtepunten. (Bijna) allemaal hebben we ook een Amerika-ervaring gehad, wat natuurlijk enorm waardevol is. **Rens**, een PhD is voor iedereen in zekere zin een zoektocht vol onzekerheden, en juist daarin heb ik ontzettend veel aan jou gehad. Met je tips en tricks heb je mij vaak voor valkuilen weten te behoeden. Bedankt!

Daantje, we begonnen samen als masterstudenten bij het EMC, allebei onder begeleiding van Vinamr. Wat begon als een stage, groeide uit tot een mooie vriendschap! Het is altijd zo leuk om met jou te sparren wat we eigenlijk met onze carrière willen doen? En hoe de zorg beter geregeld zou kunnen worden. En wie had dat gedacht: je bent zó enthousiast geworden over onderzoek dat je inmiddels zelf een PhD bent begonnen. Ik kijk uit naar jouw grote dag!

Christa, Anna, my Texan roomies, Peveto St truly rocks. I was incredibly lucky to arrive in Houston and land in such a warm and welcoming home. Amazing that I found a townhouse shared by two girls who loved Europe, and especially Amsterdam. That's quite rare in Texas! You have adopted me from day one: we went on weekend trips, you introduced me to all the Texan traditions, and I was lucky enough to celebrate many holidays with your families. Together with the twins **Rachel** and **Delilah**, we explored many bars: there was never a dull moment with y'all.

Lieve **Brecht, Suus, Suz, Aysh, Im, Lot, Lis, Loutje**. Jullie hebben de afgelopen jaren heel veel voor mij betekend. Van meeleven met de ups en downs van mijn PhD, luisteren naar mijn verhalen, of gewoon zorgen voor ontspanning: jullie waren er altijd. Vanaf moment één waren een paar van jullie al bezig met de feestplannen voor mijn promotie, wat ik ook geweldig vond. Samen hebben we de afgelopen jaren veel tripjes gemaakt, jammer dat Houston de ballotage niet heeft gehaald (misschien ooit nog). Samen met heel **OS50**, zoveel leuke vrouwen bij elkaar, was er altijd een plek voor afleiding en gezelligheid. Dank voor jullie vriendschap en alle fijne momenten samen. Love jullie!

Lieve **Claire,** wauw jij hebt veel PhD verhalen aan moeten horen terwijl je er niet veel van begreep. Gelukkig is het met jou ook vaak lachen en lol hebben. Dankjewel voor onze fijne vriendschap. Lieve **Chris,** CTC-buddy, altijd een blije puppy als het over chirurgie gaat. Dank voor je eindeloze enthousiasme. **JC Masaya,** zonder jullie was dit proefschrift nooit afgekomen.

Lotte, Anna, Zoe, Tally, de oudste friends sinds de middelbare school. Met jullie voelt het toch het meest vertrouwd. Dank dat jullie er altijd zijn.

Lieve bonusfamilie, **Carina, Marcel, Mikki, Frank, Andrine** en **Anton,** dank voor jullie altijd lieve betrokkenheid en steun.

Lieve **Mien,** wat is het fijn om een familielid te hebben met zo veel wetenschappelijke kennis. Stiekem heb ik afgelopen jaren ontzettend veel aan je gehad en ik kijk enorm naar je op. Vaak checkte je even in om te vragen hoe het met me ging, of we dronken samen een kop koffie. Dank voor je steun en betrokkenheid! Lieve **Soof,** wat een prachtige tekeningen heb jij gemaakt voor dit proefschrift. Jij hebt duidelijk de creatieve genen meegekregen van opa. Ik ben je superdankbaar.

Lieve **Olie,** oudste broer, je begrijpt nog steeds geen pepernoot van wat voor onderzoek ik precies heb gedaan. Laten we het er maar op houden dat jij een groot deel van mijn PhD in Afrika woonde, dus de details zijn je vergeven. Ik heb je de afgelopen jaren enorm gemist. Voor je naar het buitenland vertrok, kwam ik bijna wekelijks bij je langs. Waar ik vroeger vooral je irritante kleine zusje was ("Megan"), ben ik ontzettend blij dat we nu zo'n goede band hebben. Als jij iets wilt, ga je er voor de volle 200% voor. Die vastberadenheid en doorzettingskracht zijn eigenschappen die jij mij hebt geleerd. Lieve **Mau,** andere dokter in de familie. Jij bent voor mij een soort therapeut: je sleept me regelmatig de deur uit om samen te gaan rennen, luistert naar mijn verhalen en geeft altijd goed advies. Het is natuurlijk ook een enorme luxe om een broer te hebben die een aantal stappen verder is in zijn medische carrière en die begrijpt hoe het is om in het ziekenhuis te werken. Ik kan altijd met je sparren, maar ook gewoon even mijn frustraties kwijt. Ik ben ontzettend trots op hoe hard jij werkt, en dat je nu bent aangenomen voor de opleiding tot KNO-arts is dan ook meer dan verdiend.

Lieve **mam** en **pap,** mijn twee grootste cheerleaders. Waar jullie dit jaar een nieuwe fase ingaan, begint mijn carrière net. Ik voel me vereerd dat ik het stokje een klein beetje mag overnemen. Als jongste kind en enige dochter heb ik misschien altijd nét wat extra aandacht gekregen (en eerlijk gezegd krijg ik die nog steeds, getuige onze actieve Sulzer-mini WhatsAppgroep). Jullie staan altijd voor mij klaar. Of het nu gaat om wijze lessen en grappige feitjes van pap, verhalen uit het ziekenhuis en patiënten die met hem weglopen, of om mam die op de IC alle ballen tegelijk in de lucht weet te houden: jullie hebben mij altijd laten zien wat betrokkenheid, toewijding en zorg voor anderen betekenen. Presentaties, teksten of belangrijke keuzes: ik kan altijd alles met jullie delen, wetende dat jullie het met aandacht zullen lezen en met mij meedenken. Jullie geloof in mij heeft mij enorm veel vertrouwen gegeven. Dank voor alles wat jullie mij hebben geleerd, voor alle steun en voor het altijd klaarstaan. Ik hou van jullie.

Lieve **Nino**, misschien ben jij wel degene geweest die de meeste offers heeft gebracht in de afgelopen jaren. Eerst doordat ik een jaar in het buitenland zat, en later tijdens mijn coschappen, waarin ik ook in de avonden en weekenden vaak bezig was. Toch ben jij er altijd voor mij geweest. Je bent super zorgzaam en weet mij altijd op te vrolijken, juist op de momenten dat ik het nodig heb. Afgelopen jaren ben jij mijn grootste steun en toeverlaat geweest. Jouw geduld, liefde, begrip en onvoorwaardelijke steun hebben voor mij echt het verschil gemaakt. Zonder jou was dit nooit gelukt. Dankjewel dat je altijd naast me staat!

Curriculum vitae



Titia Anna Louise Sulzer was born on January 2nd, 1998 in Haarlem (the Netherlands), as the youngest child of Andrea and Maarten Sulzer and younger sister of Olivier and Maurits. She grew up in Aerdenhout and completed her high school at the Kennemer Lyceum. From an early age, she was drawn to the medical world, a curiosity that led her to write her final high school thesis on antibiotic resistance in poultry, including laboratory work with chicken defecation. Despite this early interest and perhaps influenced by watching her two physician parents work demanding schedules, she initially chose a different path.

In 2017, she enrolled in Law School at Leiden University. Although she considers herself a person with a strong sense of justice, she soon found the programme dry and her heart elsewhere. While remaining in Leiden, she switched to Health Sciences at the VU University Amsterdam, complementing her studies with a part-time position at Eurotransplant in Leiden, where a first interest in surgery quietly took root.

After two years of Health Sciences, she decided to pursue her original ambition and applied for Medical School. She was admitted and began her medical training in 2019 at the University of Amsterdam. When the COVID-19 pandemic disrupted physical education, she used the unexpected time to enroll in the Bachelor Honours Programme and joined the research group of Prof. Tom van der Poll at Amsterdam UMC, as a student researcher contributing to a study on pneumonia. In 2022, she simultaneously completed her Bachelor's degrees in Medicine and Health Sciences.

With a waiting period before clinical rotations, she began her research internship under the supervision of Prof. Hence J.M. Verhagen at the Department of Vascular Surgery, Erasmus MC. Fortunately, a research position became available in Houston, Texas, in the group of Prof. Gustavo S. Oderich at the University of Texas Health Science Center. She spent a year in Houston, where most of the research presented in this thesis on fenestrated and branched endovascular repair of complex aortic aneurysms was conducted.

Upon returning to the Netherlands, she completed her final clinical rotation in general surgery at the BovenIJ Hospital, Amsterdam, and obtained her medical degree in February 2026. She currently works as a resident-not-in-training (ANIOS) in cardiothoracic surgery at the OLVG, Amsterdam. As for what comes next, she is still figuring it out, but promises to keep you posted.