NEW DEVELOPMENTS IN DIAGNOSIS AND TREATMENT OF INTRACRANIAL ANEURYSMS

Sanne Barbara Theresa van Rooij

NEW DEVELOPMENTS IN DIAGNOSIS AND TREATMENT OF INTRACRANIAL ANEURYSMS

Sanne Barbara Theresa van Rooij

ISBN: 978-94-6380-813-2
© Sanne van Rooij, 2020

Cover: Sieger Zuidersma en Hendriks / ProefschriftMaken
Layout: Dennis Hendriks / ProefschriftMaken
Print: ProefschriftMaken / www.proefschriftmaken.nl

All rights reserved. No part of this publication may be reproduced, distributed, or transmitted in any form or by any means, including photocopying, recording, or other electronic or mechanical methods, without the prior written permission of the publisher, except in the case of brief quotations embodied in critical reviews and certain other noncommercial uses permitted by copyright law. For permission requests, write to the publisher, addressed "Attention: Permissions Coordinator," at the address below.

NEW DEVELOPMENTS IN DIAGNOSIS AND TREATMENT OF INTRACRANIAL ANEURYSMS

ACADEMISCH PROEFSCHRIFT

ter verkrijging van de graad van doctor
Aan de Universiteit van Amsterdam
op gezag van de Rector Magnificus
prof. dr. ir. K.I.J. Maex
ten overstaan van een door het College voor Promoties ingestelde commissie,
in het openbaar te verdedigen in de Agnietenkapel
op 2 juli 2020, te 14.00 uur

door

Sanne Barbara Theresa van Rooij
geboren te Utrecht

Promotiecommissie

Promotor:	Prof. dr. C.B.L.M. Majoie	AMC-UvA
Copromotores:	Dr. J.P. Peluso	ETZ Tilburg
	Dr. M.E. Sprengers	AMC-UvA
Overige leden:	Prof. dr. Y.B.W.E.M. Roos	AMC-UvA
	Prof. dr. W.P. Vandertop	AMC-UvA
	Prof. dr. W. van Zwam	Universiteit van Maastricht
	Prof. dr. L. Reneman	AMC-UvA
	Prof. dr. A. van der Zwan	Universiteit van Utrecht
	Dr. R. van den Berg	AMC-UvA

Faculteit der Geneeskunde

Contents

Chapter 1	**General introduction and outline of the thesis**	7
Chapter 2	**Current hospital demographics of subarachnoid hemorrhage based on CT-Angiography and 3D Rotational Angiography in a neurosurgical center** *AJNR Am J Neuroradiol 2019;40:1013-1017*	23
Chapter 3	**CT-Angiography versus 3D rotational angiography in patients with subarachnoid hemorrhage** *Neuroradiology 2015;57:1239-1246*	37
Chapter 4	**Fenestrations of intracranial arteries detected with 3D rotational angiography** *AJNR Am J Neuroradiol 2009;30:1347-1350*	53
Chapter 5	**WEB treatment of ruptured intracranial aneurysms: a single center cohort of 100 patients** *AJNR Am J Neuroradiol 2017;38:2282-2287*	63
Chapter 6	**The Woven EndoBridge (WEB) as primary treatment for unruptured intracranial aneurysms** *Interv Neuroradiol 2018;24:475-481*	79
Chapter 7	**The new low-profile WEB 17 system for treatment of intracranial aneurysms: first clinical experiences** *AJNR Am J Neuroradiol 2018;39:859-863*	95
Chapter 8	**Mid-term 3T MRA follow-up of intracranial aneurysms treated with the Woven EndoBridge** *Interv Neuroradiol 2018;24:601-607*	109
Chapter 9	**A systematic review and meta-analysis of Woven EndoBridge Single Layer for treatment of intracranial aneurysms** *Interv Neuroradiol in press*	121
Chapter 10	**General discussion and future directions**	135
Appendices	**Summary**	149
	Nederlandse samenvatting	153
	List of publications	157
	Dankwoord	158
	About the author	160

CHAPTER

1

General introduction and outline of the thesis

General Introduction

Intracranial aneurysms

Intracranial aneurysms are not congenital but develop in the course of life. The best estimate of the frequency of aneurysms for an average adult without specific risk factors is 2.3% (95% CI1.7–3.1); this proportion increases with age. Saccular aneurysms arise mostly at arterial branching sites at the base of the brain, typically on the circle of Willis. Most intracranial aneurysms will never rupture. The rupture risk increases with the size of the aneurysm, but paradoxically, most ruptured aneurysms are smaller than 1 cm; the explanation for this paradox is that the vast majority of all aneurysms are small and the small fraction of this majority that ruptures outnumbers the greater fraction of the minority of large aneurysms that ruptures.

Modifiable risk factors for rupture are hypertension, smoking, and excessive alcohol intake, all of which more-or-less double the risk. Genetic factors also play a role; in patients with a positive family history of subarachnoid hemorrhage (SAH), the average age at which the hemorrhage occurs is younger than in patients with sporadic SAH, and the aneurysms are more often large and multiple.

Factors that precipitate the rupture of an aneurysm are complex, though a sudden increase in transmural arterial pressure seems a plausible element. Activities with a rise in blood pressure preceding SAH, such as physical exercise, sexual intercourse, or straining are reported in up to 20% [1].

Epidemiology

The incidence of SAH in most populations is 6-7 per 100,000 person-years but is at around 20 per 100,000 much higher in Finland and Japan. Although the incidence increases with age, half the patients are younger than 55 years at the time of bleeding. Ruptured aneurysms are the cause in 85% of patients. In 10% the hemorrhage pattern is perimesencephalic and non-aneurysmal, a relatively harmless condition. The remaining hemorrhages are caused by various rare conditions such as dissections, arteriovenous malformations or dural fistulae and in some patients, no cause can be found.

The case fatality rate of SAH is about 50%, including 10-15% who die at home or during transportation to the hospital. About 25% survives with neurological deficits; the other 25% has a good outcome.

Clinical features of SAH

Sudden severe headache is the most characteristic symptom of SAH. Headache is generally diffuse and often described by patients as by far the most severe headache they have ever had. The headache usually lasts 1–2 weeks, sometimes longer. Seizures at the onset of the hemorrhage occur in one of every 14 patients with SAH and are a strong indicator

for aneurysmal rupture as the cause for the headache. On admission two-thirds of all patients have depressed consciousness, of which half are in a coma. Acute hydrocephalus might be a cause and drainage either by lumbar puncture or ventricular drain is indicated. Neck stiffness is a common symptom, caused by the inflammatory response to blood in the subarachnoid space. Intraocular hemorrhages occur in one in seven patients with a ruptured aneurysm. Patients might complain of large brown blobs obscuring their vision. Focal neurological deficits occur when an aneurysm compresses a cranial nerve or bleeds into the brain parenchyma, or from focal ischemia due to acute vasoconstriction immediately after aneurysmal rupture. Complete or part third-nerve palsy is a well-known sign after rupturing of aneurysms, most of the internal carotid artery at the origin of the posterior communicating artery or on the basilar artery at the origin of the superior cerebellar artery. Systemic features that can be associated with SAH in the acute phase are severe hypertension, hypoxemia, and electrocardiographic (ECG) changes, which can mimic acute myocardial infarction.

CT scanning

CT scanning is the first imaging study if SAH is suspected. The ability to detect SAH is dependent on the amount of subarachnoid blood and the interval after symptom onset. On the first day, extravasated blood will be present in more than 95% of patients but in the following days, this proportion falls sharply as blood in the subarachnoid space is recirculated and cleared. The hemorrhage from an intracranial aneurysm can rupture into the brain tissue, the ventricular system or sometimes the subdural space. The location of the intracerebral hematoma usually indicates the site of the ruptured aneurysm.

Lumbar puncture

In a small minority of patients (about 3%) with sudden headache and normal head CT scan within 12 h the cerebrospinal fluid shows metabolites of hemoglobin and angiography subsequently confirms a ruptured aneurysm. Therefore, a lumbar puncture is necessary for any patient with a sudden headache and a normal head CT scan.

Imaging of intracranial aneurysms

CT Angiography

Angiographic studies, in general, serve to identify an aneurysm as a potential cause of subarachnoid hemorrhage. In addition, the anatomical configuration of the aneurysm is evaluated in relation to adjoining arteries, which allows optimum selection of endovascular or surgical treatment.

CT angiography is a continuously improving technique. The sensitivity for detecting aneurysms is about 90-95%. Small aneurysms of 2-3 mm size are hard to detect with CT angiography. The advantage of CT angiography is that it can be performed immediately

following the scan that diagnosed SAH while the patient is still in the scanner. Although the standard of detection and anatomical evaluation of intracranial aneurysms has long been angiography, non-invasive pretreatment assessment with modern multi-detector CT angiography of intracranial aneurysms is considered equally diagnostic to angiography by many authors. At some institutions, CT angiography has replaced angiography for preoperative evaluations of patients with intracranial aneurysms [2]. However, the value of CT angiography in patients with SAH remains controversial since many comparative studies suffered methodological weaknesses. In some studies, poor quality CT-studies because of patient motion were excluded. In most studies, other possible causes of SAH such as dissections, AVMs, dural fistula, Moya Moya syndrome or reversible vasospasm syndrome were disregarded. In most studies, high-quality CT angiography was compared with conventional 2D angiography, while with 3D rotational angiography substantially more aneurysms can be depicted. Therefore we wanted to compare state-of-the-art multi-detector row CT angiography with the best available image modality, 3D rotational angiography under optimal conditions to assess the real diagnostic value of CT angiography in patients with subarachnoid hemorrhage.

MR Angiography

MR angiography is another non-invasive imaging modality that can be used in patients with intracranial aneurysms. Because of relatively long acquisition times and irritating noise production, MR angiography is not suitable for patients with acute SAH and severe headaches. MR angiography is very useful for the follow-up of treated aneurysms since no radiation is involved and contrast material is not necessary. A disadvantage is that metal devices may cause signal distortion or signal loss. With MR angiography the whole aneurysm with its surroundings can be evaluated including intraluminal thrombus and the aneurysm wall.

Catheter angiography

Catheter angiography is not an innocuous procedure. In patients with subarachnoid hemorrhage, the rate of ischemic neurological complications (transient or permanent) is 1.8%, that of aneurysm rerupture during the procedure 1-2% overall. 3D Rotational Angiography of all vessels, preferably under general anesthesia preceding endovascular treatment, is now the gold standard in aneurysm detection and anatomic evaluation [3]. With 3D angiography, contrast is injected through a catheter in the internal carotid or vertebral artery and image acquisition is done during a 240 degrees rotation of the X-ray tube. This rotational run is sent to a dedicated computer work station. From the rotation, the computer reconstructs a high-resolution volume-rendered 3D image set of the vascular tree that can be freely rotated.

Clinical Management

In patients who survive the initial hours after the hemorrhage, three main neurological complications can threaten the patient with a ruptured intracranial aneurysm: rebleeding, acute hydrocephalus and delayed brain ischemia.

Patients with a large intraparenchymal or subdural hematoma and depressed consciousness might require immediate hematoma evacuation, preferably preceded by endovascular occlusion of the aneurysm or extensive hemicraniectomy that allows external expansion of the brain.

Massive intra-ventricular extension and hydrocephalus can be treated by emergent insertion of an external ventricular drain.

Prevention of rebleeding

In the first few hours after the initial hemorrhage, up to 15% of patients have a sudden deterioration of consciousness that suggests rebleeding. In patients who survive the first day, the risk of rebleeding is more-or-less evenly distributed during the next 4 weeks with a cumulative risk of 40% without intervention. After rebleeding the prognosis is poor: 80% of patients die or remain disabled.

During the past 2 decades, endovascular occlusion by means of detachable coils (coiling) of aneurysms has largely replaced surgical occlusion as the intervention of choice for the prevention of rebleeding. The technique consists of packing the aneurysm with detachable platinum coils. Ideally, after coiling, the remaining lumen becomes occluded by a process of reactive thrombosis, but early or late rebleeding can occur after technically correct procedures. Uncertainty exists about the length of time that patients need to be followed up after coiling, about the most suitable radiological technique for follow-up, and about the need for a second procedure for aneurysm necks that have recanalized by impaction of the coils.

Surgical clipping for occlusion of the aneurysm has now become the second choice for most patients. Surgery is preferably performed within 72 hours but may be delayed in patients in poor clinical condition.

Delayed cerebral ischemia

The diagnosis of delayed cerebral ischemia is often defined poorly. Laboratory examinations and repeat brain CT scans are needed to exclude other causes, especially hydrocephalus and systemic complications. MRI is more sensitive in detecting early changes in the brain, especially with diffusion-weighted imaging, but the procedure is often too long for ill and restless patients. CT perfusion studies may attribute to diagnosis. Induced hypertension, hypervolemia and haemodilution (Triple H) are moderately plausible but unproven intervention strategies.

Systemic complications

Non-neurological complications often occur in patients with aneurysmal subarachnoid hemorrhage. These include fever, anemia, hypertension and hypotension, hyperglycemia, hypernatremia and hyponatremia, hypomagnesemia, cardiac failure and arrhythmias, and pulmonary edema and pneumonia. These complications should be dealt with in close collaboration with physician intensivists.

Long-term complications

Late rebleeding can occur in patients with successfully occluded aneurysms from regrowth or reopening of the aneurysm that caused the first bleed or from additional or de novo aneurysms. The risk of late rebleeding is a concern after coiling and imaging follow-up is necessary. Reopening of the aneurysm to some extent occurs in about 20% of endovascular treated aneurysms and half of these are additionally treated [4].

Cognitive deficits and psychosocial dysfunction in the first year after subarachnoid hemorrhage are common in patients who make a good recovery in terms of self-care. Although improvement occurs between 4 and 18 months after the hemorrhage, many former patients and their partners experience deficits and reduced quality of life 1-2 years after the hemorrhage. Many patients report changes in personality, most commonly increased irritability, emotionality and memory dysfunction.

Prevention

Incidental unruptured aneurysms

If an intracranial aneurysm is a surprise finding on an imaging study undertaken for another purpose, the dilemma arises whether the risk associated with preventive clipping or coiling of the aneurysm is outweighed by the risk of death or disability from rupture of the untreated aneurysm sometime later in life. Age is the most helpful factor, because the potential gain in life years decreases with increasing age, whereas the risk of complications of preventive treatment increases. On the other hand, the risk of rupture increases with age. Other factors that should be taken into account are the size of the aneurysm (increased risk of rupture with increasing size), the location of the aneurysm (greater risk of rupture if in the posterior circulation), sex (women have a higher risk of rupture), country (risk is higher in Japan and Finland), comorbidity, and family history. The anatomy of the aneurysm in relation to adjacent vessels is important to estimate the complication risk of endovascular treatment: a small posterior communicating artery aneurysm with a well-defined neck has a lower complication risk than a wide-necked large basilar artery aneurysm with vessels arising from the sac.

Additional unruptured aneurysms in patients with a ruptured aneurysm

Patients, who survive an episode of SAH and in whom the ruptured aneurysm is occluded, might have additional unruptured aneurysms. In general, treatment by endovascular or operative route will be offered, except if the treatment risk is high in aneurysms with unfavorable anatomy.

Screening for aneurysms in relatives of patients with subarachnoid hemorrhage

Individuals with an affected first-degree relative have a 5-12 times greater lifetime risk of subarachnoid hemorrhage than the general population, corresponding with a lifetime risk of 2-5%. The chance of finding an aneurysm by screening in an individual with a single affected relative is only 1.7 times higher than in the general population[1]. The aim of screening is not so much to detect or to treat an aneurysm, but to increase the number of quality years of life. Before any intracranial vessels are imaged, the risks and benefits of screening should be weighed against the considerable psychosocial effects, both positive and negative.

Treatment of intracranial aneurysms

Treatment of intracranial aneurysms is aimed at the prevention of first or recurrent hemorrhage. It has been proven that endovascular treatment of both unruptured and ruptured aneurysms provides better outcomes as compared to surgical clipping [5,6]. Following SAH, coil embolization provides a 7% less poor outcome as compared to surgical clipping [5]. Endovascular treatment is therefore recommended as the first choice of treatment for recently ruptured aneurysms. Depending on aneurysm morphology, relation to adjacent vessels and rupture status different endovascular methods are being used to achieve aneurysm occlusion. Coil embolization using detachable micro-coils was first proposed by Guido Guglielmi in the early 1990-s [7]. Since then, multiple modifications of coil technology have been introduced such as different thicknesses, shapes, lengths, softness, and coating and detachment systems. The major weakness of coiling as compared to clipping is the relatively high rate of incomplete occlusion and recurrence. A systematic review showed that 21% of all coiled intracranial aneurysms show reopening of which half is retreated [4]. Another study showed that late reopening (>6 months after treatment) occurs in 3% of coiled aneurysms with large size and location on the basilar tip as risk factors for this event [8].

In order to overcome the problem of incomplete occlusion and recurrence and to make it possible to treat more aneurysm types (including dissection aneurysms and wide-necked aneurysms), new techniques have been introduced such as parent vessel occlusion, coil embolization with a balloon- or stent assistance, flow diverters and most recently intrasaccular flow disrupters.

A stent implanted within the parent artery across the neck of the aneurysm may not only facilitate treatment but also improve packing density. Flow characteristics may be

altered stimulating spontaneous thrombosis. The stent mesh may initiate intimal growth that could seal the aneurysm cavity from the parent artery. Stent assisted coil packing is, however, a more complex procedure, requiring aggressive antiplatelet treatment. These procedures have been associated with a higher rate of procedural complications, especially in ruptured aneurysms [9,10].

Flow diverters are high-density wire mesh tubes that are designed to divert and disrupt flow into intracranial aneurysms to a degree where thrombosis will occur over time. Treatment with flow-diverters also requires a rigorous anti-platelet protocol and might be complicated by thromboembolic and hemorrhagic complications. A meta-analysis [11] showed a complete occlusion rate of 76% at 6 months. Procedure-related morbidity and mortality were high with 5% and 4%, respectively. The rate of postoperative subarachnoid hemorrhage was 3%, the rate of intra-parenchymal hemorrhage was 3% and the ischemic stroke rate was 6%.

The Woven EndoBridge (WEB) was the first intrasaccular flowdiverter introduced in 2010. The WEB is a self-expanding, oblong or spherical shaped, braided nitinol mesh. This device is specially designed to treat wide-necked aneurysms without the support of a stent or balloon and without the need for antiplatelet medication. This makes the WEB especially useful in the setting of ruptured aneurysms.

Aims and outlines of this thesis

This thesis is based on two pillars: imaging with state-of-the-art 3D angiography and endovascular therapy with the new Woven EndoBridge intrasaccular flow-diverter.

3D Rotational Angiography

Until now, several aspects of patients with intracranial vascular disorders remained not fully elucidated because of limitations in imaging with CT and 2D angiography. CT and CT angiography have limited spatial resolution and with 2D angiography, only a limited number of projections can be made. With the introduction of 3D angiography, a new modality with high resolution and an infinite number of projections became available in clinical practice. Therefore, we wanted to use 3D angiography to shed new light on existing clinical issues.

First, we wanted to evaluate the impact of 3D angiography on the diagnosis of aneurysms and other vascular disorders and variations in patients with SAH. Data were collected from all patients with brain CT angiography performed for intracranial hemorrhage and suspected aneurysms or other vascular causes of this hemorrhage. With (suspected) aneurysms, 3D angiography was performed of all cerebral vessels, mostly under general anesthesia preceding endovascular treatment. These data were used to assess the clinical value of CT angiography in patients with SAH. Secondly, we used these

3D data to assess the prevalence and locations of fenestrations of intracranial arteries and the possible relation of fenestrations with aneurysms. Finally, hospital demographics of patients with SAH were assessed.

The Woven EndoBridge

The endovascular treatment of wide-necked intracranial aneurysms remains a technical challenge. Conventional techniques such as balloon- or stent assistance and intravascular flow-diverters have several disadvantages such as catheterization difficulties and the need for longstanding dual antiplatelet medication. The new intrasaccular flow-diverter Woven EndoBridge (WEB) was developed for single-step endovascular treatment of wide-necked aneurysms without the need for antiplatelet medication. In the St Elisabeth Hospital in Tilburg, clinical results of endovascular treatment with stents and flowdiverters of patients with ruptured intracranial aneurysms were poor because of hemorrhagic and thrombotic complications in relation to the antiplatelet medication. The WEB was introduced for the treatment of both ruptured and unruptured aneurysms without the need for antiplatelet medication. Clinical and imaging results were collected and used for studies of ruptured and unruptured aneurysms treated with the WEB in relation to previous results.

Part 1: Advances in Imaging: 3D Rotational Angiography

Between March 2013 and April 2015, patients with SAH on a native CT scan or with positive lumbar puncture and who underwent CT angiography were entered into a database. Patients were categorized according to medical history and blood distribution on CT as aneurysmal SAH, perimesencephalic SAH, trauma and SAH, no blood on CT and positive lumbar puncture. Perimesencephalic bleeding pattern was defined as blood confined to the cisterns around the midbrain in the prepontine, interpeduncular, and ambient cistern. CT angiography was performed on multi-detector row scanners and 2D and 3D reconstruction sets were made for diagnosis. Patients with aneurysms diagnosed on CT angiography or with negative CT angiography but aneurysmal bleeding pattern underwent 3D angiography of all cerebral vessels. In uncooperative or intubated patients, 3D angiography was performed under general anesthesia. The rotational angiographic data were transferred to an independent workstation for the instant generation of 3D reformatted images.

In this way, a unique dataset was obtained of patients with intracranial hemorrhage and suspected vascular disorders with 3D angiographic images of all brain vessels as the golden standard. This dataset was used for the following studies:

To reliably assess hospital demographics of patients with intracranial hemorrhage and suspected vascular disorders, in **Chapter 2**, we documented 3D angiographic diagnostic findings and treatment of all patients presenting to the St Elisabeth Ziekenhuis

in Tilburg with intracranial hemorrhage and CT angiography performed over a time-span of 2 years. Hospital demographics of patients with SAH have changed substantially in the last 2 decades. Endovascular treatment has largely replaced surgery and new 3D angiographic techniques provide a more accurate diagnosis.

To evaluate the prevalence and location of fenestrations of intracranial arteries and the relation with aneurysms, in **Chapter 3**, we review 3D angiographic data in a cohort of 140 patients with suspected aneurysms. Fenestrations are segmental duplications of the lumen of intracranial arteries with two distinct channels. Some suggest that altered flow-dynamics in the presence of fenestrations may promote aneurysm development, though the exact relationship is not well understood. With conventional 2D angiography, most fenestrations remain undetected but with modern 3DRA, fenestrations are easily visible. This allows for accurate assessment of frequency and locations.

To assess the diagnostic accuracy of CT angiography in the detection of intracranial aneurysms and other vascular disorders in patients with acute SAH, in **Chapter 4**, we compared CT angiography with 3D angiography of all cerebral vessels under optimal conditions, mostly under general anesthesia. Previous studies about diagnostic performance of CT angiography had methodological weaknesses such as the exclusion of poor-quality studies by motion artifacts and comparison with 2D angiography instead of the gold standard 3D angiography. Our robust dataset provides the most reliable data about the true performance of CT angiography as a diagnostic test in patients with subarachnoid hemorrhage.

Part 2: Advances in treatment: WEB device

The Woven EndoBridge intrasaccular flowdiverter was introduced in the St Elisabeth Hospital in Tilburg in early 2015 as an alternative for supportive stents or balloons in wide-necked aneurysms without the need for antiplatelet medication. Following good results in unruptured wide-necked aneurysms, the indication was gradually expanded to all aneurysms suitable for the device, also ruptured aneurysms and aneurysms with a small neck. In December 2016 the new low-profile WEB 17 system was introduced for better performance in tortuous vessels and small aneurysms.

Of all patients treated between 2015 and 2018 with endovascular techniques, patient- and aneurysm characteristics were prospectively recorded in a database. This database was used for several clinical studies.

To assess the clinical value of the WEB in patients with ruptured intracranial aneurysms, in **Chapter 5**, we evaluated the clinical- and imaging results of the first 100 patients with ruptured aneurysms treated with the WEB. Our strategy was to treat ruptured (wide neck) aneurysms by the WEB or, when WEB placement was not possible, by coiling or surgery. In this way, we avoided the use of stents and flow-diverters with inherent dual anti-platelet medication and associated complications. In this study, we

present the results of this treatment strategy in a cohort of 100 patients with ruptured aneurysms treated with the WEB.

To assess the clinical value of the WEB in patients with unruptured aneurysms, in **Chapter 6**, we evaluated the clinical and imaging results of the WEB used as primary treatment for unruptured intracranial aneurysms. Although the WEB was initially developed for wide-necked bifurcation aneurysms, we treated all aneurysms suitable for the device, regardless of neck size and location and without the use of supporting balloons or stents. The results of 59 unruptured aneurysms are presented.

To evaluate the clinical performance of the new low-profile WEB 17, in **Chapter 7**, we present the first clinical and follow-up imaging results of treatment of both ruptured and unruptured aneurysms with this new WEB 17. While the former generation WEBs needed a 0.021-inch microcatheter in the small sizes, the new WEB 17 system consisted of a lower-profile range of WEBs compliant with a 0.017-inch microcatheter. The WEB 17 was developed to improve technical performance in tortuous vasculature and for (very) small aneurysms. In this study, we present the first clinical results of 46 ruptured and unruptured small aneurysms treated with the new WEB 17 system.

In **Chapter 8**, Magnetic Resonance Angiography (3T MRA) was used for mid-term follow-up of WEB-treated aneurysms that were adequately occluded at 3 months angiographic follow-up at 3 months. Included were 52 patients with 53 aneurysms treated with the WEB between February 2015 and July 2016. There were 29 women and 23 men with a mean age of 60 years. Mean aneurysm size was 6.2 mm. 3T MRA follow-up was mean 19.6 months (median 18, range 18–36 months). One patient had an aneurysm remnant at three-month angiography that was additionally coiled and with stable complete occlusion at 18 months' 3T MRA follow- up. At three-month follow-up angiography, 44 aneurysms were completely occluded and eight had a neck remnant. At latest 3T MRA, stable complete occlusion was present in 43 aneurysms and stable neck remnant in eight. One posterior cerebral artery (PCA) dissection aneurysm was stable at three and six months but was enlarged and reopened at 18 months, confirmed with angiography. Focal signal loss by the proximal marker of the WEB was apparent in four patients without compromising diagnostic evaluation. WEB-treated aneurysms with adequate occlusion at three-month angiography remained stable during serial 3T MRA follow-up of 18–36 months. One PCA aneurysm reopened during the 6- to 18-month interval. Once the WEB-treated aneurysm is adequately occluded in the short term, later reopening is uncommon.

To evaluate clinical results of the WEB Single Layer for intracranial aneurysms with narrow confidence limits, in **Chapter 9**, a systematic review was performed about the results of the treatment of intracranial aneurysms with the latest generations of WEB with a single layer of the braid (WEB-SL). When the WEB was first introduced in 2010, it consisted of a dual-layer of nitinol braid (WEB-DL). This made the system high profile with the need for relatively large microcatheters of 0.027-0.038 inch. All reviews to date included the

results of both WEB-DL and SL. Since WEB-DL is no longer available, a new review with the exclusion of WEB-DL would be a more realistic way to evaluate the current results.

Finally, **Chapter 10**, comprises a general discussion of the thesis.

References

1. Van Gijn J, Kerr RS, Rinkel GJ. Subarachnoid haemorrhage. Lancet 2007;369:306-18
2. Westerlaan HE, van Dijk JM, Jansen-van der Weide MC, et al. Intracranial aneurysms in patients with subarachnoid hemorrhage: CT angiography as a primary examination tool for diagnosis-systematic review and meta-analysis. Radiology 2011;258:134-145
3. van Rooij WJ, Sprengers ME, de Gast AN, et al. 3D Rotational Angiography: the new gold standard in the detection of additional intracranial aneurysms. AJNR Am J Neuroradiol 2008;29:976-9
4. Ferns SP, Sprengers ME, van Rooij WJ, et al. Coiling of intracranial aneurysms: a systematic review on initial occlusion and reopening and retreatment rates. Stroke 2009;40:e523-9
5. Molyneux A, Kerr R, Stratton I, et al. International Subarachnoid Aneurysm Trial (ISAT) of neurosurgical clipping versus endovascular coiling in 2143 patients with ruptured intracranial aneurysms: a randomized trial. Lancet 2002;360:1267-74
6. Brinkjikji W, Rabenstein AA,Nasr DM et al. Better outcomes with treatment by coiling relative to clipping of unruptured aneurysms in the United States, 2001-2008. AJNR Am J Neuroradiol 2011;32:1071-5
7. Guglielmi G, Vinuela F, Dion J, et al. Electrothrombosis of saccular aneurysms via endovascular approach. Part 2: Preliminary clinical experience. J Neurosurg 1991;75:8-14
8. Ferns SP, Sprengers ME, van Rooij WJ, et al. LOTUS Study Group. Late reopening of adequately coiled intracranial aneurysms: Frequency and risk factors in 400 patients with 440 aneurysms. Stroke 2011;42:1331-7
9. Piotin M, Blanc R, Spelle L, et al. Stent-assisted coiling of intracranial aneurysms: clinical and angiographic results in 216 consecutive aneurysms. Stroke 2010;41:110-5
10. Bechan RS. Sprengers ME, Majoie CB, et al. Stent-assisted coil embolization of intracranial aneurysms: complications in acutely ruptured versus unruptured aneurysms. AJNR Am J Neuroradiol 2016;37:502-7
11. Brinjikji W, Murad MH, Lanzino G et al. Endovascular treatment of intracranial aneurysms with flow diverters: a meta-analysis. Stroke 2013;44:442-7

CHAPTER

2

Current hospital demographics of subarachnoid hemorrhage based on CT-Angiography and 3D Rotational Angiography in a neurosurgical center

van Rooij SBT, Bechan RS, van Rooij WJ, Sprengers ME

AJNR Am J Neuroradiol 2019;40:1013-1017

Background and purpose

Aneurysmal subarachnoid hemorrhage (SAH) is a significant cause of mortality and morbidity. Modern hospital demographics are scarce. We evaluate diagnosis and treatment of patients with SAH in a neurosurgical referral center.

Material and methods

Between March 2013 and April 2015, 284 patients with SAH diagnosed on CT scan or lumbar puncture were admitted. All patients had 64-128 detector row CT Angiography. Additional imaging was with 3D Rotational Angiography of all vessels. In patients with aneurysms, characteristics and mode of treatment were recorded.

Results

In 197 of 220 patients with an aneurysmal bleeding pattern a cause of the bleeding was found: 195 patients had a ruptured aneurysm (98%), 1 patient a micro AVM and 1 patient reversible vasoconstriction syndrome. Of 195 ruptured aneurysms, 6 were dissection aneurysms and 3 were AVM associated flow aneurysms. In 23 of 204 patients (11%) with an aneurysmal bleeding pattern and 3DRA performed no cause was found. In 8 of 9 patients (89%) with positive lumbar puncture but negative CT no cause was found.

Of 180 patients with a ruptured aneurysm eligible for treatment, 147 (82%) were treated endovascular and 30 (17%) were clipped.

Of 204 patients with an aneurysmal bleeding pattern and 3DRA, 72 (35%) had multiple aneurysms. These 72 patients had altogether 117 additional aneurysms of which 24 (21%) were treated either by coiling or clipping.

Conclusion

This study provides robust data on hospital demographics of SAH in a neurosurgical referral center, based on CTA and 3D Rotational Angiography of all vessels.

Introduction

Aneurysmal subarachnoid hemorrhage (SAH) is a significant cause of mortality and continuing morbidity in the population worldwide. The annual incidence of SAH in Western Europe and North America is 6-8 per 100,000 person-years [1]. More than 30% of patients with aneurysmal SAH will die within the first 24 hours and another 25-30% will die in the following 4 weeks without some form of intervention [1]. Hospital demographics of SAH have dramatically changed in the last 2 decades. With endovascular techniques, more aneurysms in more patients can be treated than in the era that surgical clipping was the only treatment modality. Aneurysm diagnosis has immensely improved with acute CTA screening and the implementation of 3D angiographic techniques [2-4]. This results in detection of more and smaller ruptured and (additional) unruptured aneurysms.

In this study, we prospectively collected demographic, diagnostic and treatment data of patients admitted with SAH in a 2-year period in a large neurosurgical referral center.

Materials and methods

Patient population

This observational study with prospectively collected data was compliant with institutional privacy policy and approved by the Institutional Review Board.

Between March 2013 and April 2015, patients with SAH on native CT scan or with positive lumbar puncture and who underwent CTA were entered into a database, as previously described [3,4]. The St. Elisabeth Hospital in Tilburg, the Netherlands is a large neurosurgical referral center with a recruitment population of 2.5 million and a level I trauma center.

Patients were categorized according to medical history and blood distribution on CT as aneurysmal SAH, perimesencephalic SAH, trauma and SAH, no blood on CT and positive lumbar puncture (xanthochromia). Perimesencephalic bleeding pattern was defined as blood confined to the cisterns around the midbrain in the prepontine, interpeduncular, and ambient cistern. Patient- and aneurysm characteristics and modes of treatment were recorded.

CT Angiography

CTA was performed on either one of three CT scanners: Philips Brilliance iCT 256 detector-row, Philips Ingenuity 128 detector-row (Philips Healthcare, Best, the Netherlands) and Siemens Somatom Definition AS 64 detector-row (Siemens, Erlangen, Germany). Volume CT was routinely performed at 130 mA and 100-120 kVp. Collimation, rotation time and pitch were optimized for the individual CT scanner according to recommendations of the manufacturer. A 90 mL dose of iodinated contrast medium (iopromide, 270 mg of

iodine/mL, Visipaque 270; GE Healthcare, Cork, Ireland) was injected at a rate of 4.0 mL/sec into an antecubital vein via a 20-gauge catheter, followed by 40 mL of saline solution. CT scanning was triggered by using a bolus-tracking technique, with the region of interest placed in the aortic arch. Image acquisition started 8 seconds after the attenuation reached the predefined threshold of 130-150 HU. The scanning time was approximately 5.0-7.0 seconds. Images were reconstructed with a 0.9-1.0 mm section thickness and a 0.45- 0.5 mm increment with an UB or I26f kernel. Volume CT dose index and dose-length product were 25.3-26.7 mGy and 475-576 mGy·cm, respectively.

3D Rotational Angiography

Patients with aneurysms diagnosed on CTA or with negative CTA but aneurysmal bleeding pattern underwent 3DRA of all cerebral vessels. Angiography was performed on a biplane angiographic system (Allura Xper FD 20/10, Philips Healthcare, Best, the Netherlands). In uncooperative or intubated patients, 3DRA was performed under general anesthesia. A single 3D rotational angiographic run was acquired of both internal carotid arteries and one vertebral artery with hand injection of 12-20 ml of contrast material. When the contralateral distal vertebral artery was not visualized, an additional 2D biplane run was performed of this vertebral artery. The tube rotation arc was 240° (one rotation used), with a rotation time of 4.1 seconds. The images were reconstructed in a 256 × 256 matrix. The rotational angiographic data were transferred to an independent workstation (Integris 3D, Philips Healthcare) for instant generation of 3D reformatted images.

Analysis of CT Angiography and 3D Rotational Angiography

CTA data were reformatted on an independent 3D workstation (Philips IntelliSpace Portal). Three neuroradiologists evaluated maximum intensity projection-, volume rendered-, and multiplanar reformatted images. Source images, post-processed images and 3D reconstructions with bone removal were transferred to PACS (IDS7, Sectra, Linköping, Sweden).

3DRA reformatted images were reviewed on the workstation by the first and senior authors in consensus. Presence, location and size of aneurysms were recorded in a database. Other vascular disorders that might be responsible for the subarachnoid hemorrhage such as arterial dissections, arteriovenous malformations, moyamoya phenomenon or reversible vasospasm syndrome were separately recorded. In patients without an obvious vascular disorder that might be responsible for the SAH, 3DRA was repeated after 1 week [4].

Treatment

When logistically possible, 3DRA was followed immediately by endovascular treatment under general anesthesia. Patients with aneurysms not suitable for coiling (wide neck anterior circulation, fusiform, vessels arising from the sac) were scheduled for surgery.

When logistically possible, good grade (non-comatose) patients were clipped within 24 hours. In poor grade patients, surgery was delayed.

Statistical analysis

Results were expressed with descriptive statistics and categorical variables as frequencies or percentages with 95%CI.

Results

Of 284 patients with SAH, 220 (77%) had an aneurysmal bleeding pattern, 39 (14%) had a perimesencephalic-bleeding pattern, 9 (3%) had a negative CT and a positive lumbar puncture and 16 (6%) had a trauma and a subarachnoid hemorrhage.

Of 284 patients, 280 underwent CTA as first diagnostic modality to detect the cause of the SAH. Four patients with SAH directly proceeded to angiography without CTA. Fig 1 illustrates diagnosis and treatment of the study population in a flow-chart.

Aneurysmal bleeding pattern

Of 220 patients with an aneurysmal bleeding pattern, 16 patients with confirmed aneurysm on CTA (7%) were in moribund clinical condition and died before angiography could be performed.

The remaining 204 patients had 3DRA after CTA. In 29 of 204 patients (14%) initial 3DRA was negative and was repeated after 1 week. Repeated 3DRA showed an aneurysm in 6 of these 29 patients: 8 mm supraclinoid dissection aneurysm, 2 superior cerebellar artery aneurysm (1 and 2 mm), 2 mm posterior communicating aneurysm, one 1 mm A1 aneurysm, and one vertebral dissection.

In 195 of 220 patients with an aneurysmal bleeding pattern (87%; 95%CI 84-92%), at least 1 aneurysm was detected. Seventy-two of 204 patients with 3DRA (35%; 95%CI 29-42%) had multiple aneurysms. Forty-three patients had 2 aneurysms, 18 patients had 3 aneurysms, 10 patients had 4 aneurysms and 1 patient had 5 aneurysms.

Of 220 patients with an aneurysmal bleeding pattern, 184 had saccular aneurysms, 6 had a dissection aneurysm (PICA 1, vertebral artery 3, and internal carotid artery 2), and 3 patients had an AVM related ruptured flow aneurysm.

Of the 25 patients with aneurysmal SAH and no aneurysm, 1 patient (0.5%) had a cervical spinal micro AVM and 1 patient (0.5%) had a reversible vasoconstriction syndrome. In 23 of 220 patients with aneurysmal SAH (10%; 95%CI 7-15%) no aneurysm of other vascular disorder was found.

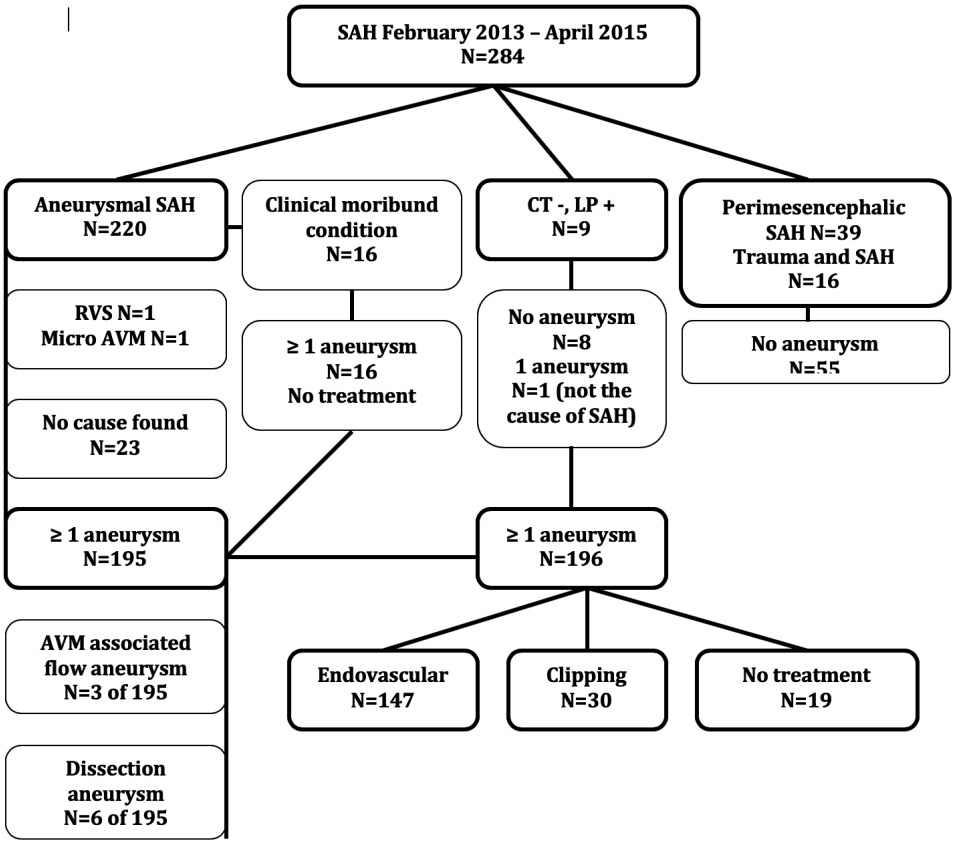

Figure 1. Diagnosis and treatment in 284 consecutive patients with SAH
RVS=Reversible Vasospasm Syndrome
AVM=Arterio-Venous Malformation
LP=Lumbar Puncture

Perimesencephalic bleeding pattern

Of 284 patients, 39 (14%; 95%CI 10-18%) had a perimesencephalic-bleeding pattern on native CT. Fifteen of 39 had 3DRA in addition to CTA. CTA and 3DRA were negative for aneurysms in all 39.

Positive lumbar puncture

Of 284 patients, 9 (3%) had no blood on CT but had positive lumbar puncture. All 9 had CTA and 2 patients also had 3DRA. In 1 patient a 7 mm dysplastic fusiform middle cerebral artery aneurysm was found that was not considered the cause of SAH.

Trauma and SAH

Of 284 patients, 16 (6%) had trauma and SAH and unknown cause and effect. CTA was normal in all 16 patients.

Treatment

Ruptured aneurysm treatment

Of 180 patients eligible for treatment with a ruptured aneurysm (including 6 dissection aneurysms), in 147 (82%) this aneurysm was treated endovascular. Of 141 saccular aneurysms, 115 (82 %) were treated with simple coiling, 24 (17 %) with balloon- or stent-assisted coiling, and 2 (1%) were treated with an intrasaccular flow disrupter (WEB device, Sequent Medical, Irvine CA).

Of 6 dissection aneurysms, 3 vertebral dissections and 1 PICA dissection were treated with parent vessel coil occlusion. Of 2 internal carotid artery dissection aneurysms 1 was treated with stent-assisted coiling and the other with a flowdiverter.

Of 3 patients with a ruptured AVM related flow-aneurysm, 2 were treated with parent vessel coil occlusion and 1 with selective coiling.

Of 180 patients with a ruptured aneurysm, 30 (17 %) were clipped.

Characteristics of patients with endovascular treated versus clipped aneurysms

Patient- and aneurysm characteristics of patients with endovascular treated and clipped aneurysms are displayed in the Table. Reasons to proceed with surgery instead of endovascular treatment in 30 patients were wide neck aneurysms in 27, failed coiling procedure in 2 and no endovascular access in 1.

Patients who were not treated

Nineteen of 196 patients with a saccular aneurysm (10%) were not treated: 16 patients were in a clinical moribund condition and 3 patients were >90 years old. It was decided not to treat the cervical micro AVM.

Tabel 1. Clinical variables at admission of patients with ruptured aneurysms eligble for treatment

	Endovascular N=147 (82%)	**Surgery N=30 (17%)**
Age (yrs)	mean 58, median 58, range 27-86	mean 58, median 59, range 28-84
Sex	106 female (72%)	23 female (77%)
HH at admission		
1	54	11
2	22	8
3	33	4
4	21	6
5	17	1
Aneurysm size		
≤ 3 mm	25	13
4-6 mm	63	9
7-10 mm	39	6
≥10 mm	20	2
Aneurysm location		
Anterior cerebral artery	61	17
Middle cerebral artery	21	8
Internal carotid artery	43	3
Posterior circulation	22	2

Timing of treatment

Mean time between the ictus and endovascular treatment was 1 day, median 1 day, range 0-20 days. Mean time between diagnosis and endovascular treatment was 1 day, median 0 days, range 0-11 days. Reasons for a delay between ictus and endovascular treatment were admission or referral from other hospitals several days after the ictus, clinical condition that did not allow angiography directly after admission, or initial negative angiography. The vast majority of patients (111 of 146, 76%) were treated within 24 hours after the ictus.

Mean time between the ictus and clipping was 10 days, median 9 days, range 0-31 days.

Mean time between diagnosis of the ruptured aneurysm and clipping was 8 days, median 8 days, range 0-30 days.

Treatment of additional aneurysms

Of the 204 patients with an aneurysmal bleeding pattern and 3DRA, 72 (35%) had multiple aneurysms. These 72 patients had altogether 117 additional aneurysms indicating a

mean of 1.6 bystander aneurysms next to the index aneurysm. Of these 117 additional aneurysms 24 (21%) were treated either by coiling or clipping.

Discussion

In this prospective observational study we found in 69% of patients with SAH (195 of 284) a ruptured aneurysm as a cause. This is much lower than in the literature of the early millennium with a ruptured aneurysm as cause of SAH in 85% [5,6]. Our incidence is lower because of zero yield of aneurysms in patients with perimesencephalic bleeding pattern, with trauma and SAH and with CT negative/lumbar puncture positive SAH. Of 220 patients with an aneurysmal bleeding pattern on CT, an aneurysm was found in 195 (89%) and no cause was found in 23 (10%), not even after repeated 3D angiography.

In our study 39 of 284 patients (14%) had a perimesencephalic-bleeding pattern on native CT. CTA was negative for aneurysms in all 39. Fifteen of 39 had 3DRA in addition to CTA, all negative for aneurysms. The cause of perimesencephalic haemorrhage is likely not aneurysmal but may be venous and the patients have no risk of rebleed [7-9]. Cerebral angiography is not needed in patients with perimesencephalic haemorrhage who had negative CTA findings [10].

The presence of multiple aneurysms was found in 72 of the 204 patients (35.3%) with an aneurysmal bleeding pattern and 3DRA performed. These 72 patients had altogether 117 additional aneurysms indicating a mean of 1.6 bystander aneurysms. These figures are in the same range as in a recent large Swiss study [11] in which multiplicity was found in 474 of 1787 patients (26.5%). Patients with multiple aneurysms had a mean of 1.4 bystander aneurysms in addition to the index aneurysm. In older autopsy and angiographic studies, a prevalence of multiplicity of about 12% was found, substantial less than in the current study [12]. The excellent sensitivity of detecting aneurysms with 3D angiography indicates that multiplicity of intracranial aneurysms is in the order of 1 in 3 instead of 1 in 8 patients as previously believed.

Ruptured aneurysms were treated endovascular in 82%; this proportion is relatively high compared to other reports [13]. Although there have been several studies on changes and trends in the management of SAH since publication of the International Subarachnoid Aneurysm Trial (ISAT), scarce data exists on characteristics of patients for surgical treatment [13-16]. The majority of the aneurysms in our population that were referred to surgery were anterior circulation wide-necked aneurysms with vessels coming from the sac. We found that the majority of the clipped aneurysms were anterior communicating artery aneurysms; this is in concordance to another study [14].

AVM associated flow aneurysms are a rare cause of SAH [15]. In our study, 3 out of 195 patients (1.5%) with a ruptured aneurysm had an AVM associated ruptured flow aneurysm. One AVM was supratentorial and 2 AVMs were located in the posterior fossa. Posterior

fossa AVMs are infrequent, comprising 7-15% of intracranial AVMs [15]. Infratentorial AVM location is independently associated with hemorrhagic AVM presentation [16].

Dissection aneurysms are also a rare cause of SAH (17,18). In our study it was the cause of SAH in 6 of 195 patients (3%) .

In our study 9 of 284 patients (3%) had CT negative, lumbar puncture positive SAH. In 1 of 9 patients an aneurysm was found that was not considered the cause of hemorrhage. Another prospective study found in 40 of 94 patients (43%) an intracranial aneurysm or dissection [19]. The small patient groups make comparison invalid.

In our study 16 of 284 patients (6%) had trauma and SAH and unknown cause and effect. CTA was normal in all 16 patients. In a recent retrospective study, 186 of 617 patients with traumatic SAH underwent CTA. They found 8 ruptured aneurysms, these patients all had blood in the in the subarachnoid cisterns and Sylvian fissures. They found 5 unruptured aneurysms; these patients only had peripheral subarachnoid blood. Their data suggest a more selective approach to screening CTAs in patients with trauma and SAH [14].

Of note, our results are based of SAH demographics in a neurosurgical referral center and thus cannot be generalized to demographics of SAH in general.

In conclusion, our study provides robust hospital demographic data on SAH based on CTA for screening and 3DRA of all cerebral vessels. The excellent depiction of aneurysms with 3DRA shows a shift of some data: aneurysm multiplicity is in the order of 1 in 3 (instead of 1 in 8), and 11% of patients with an aneurysmal bleeding pattern on CT has no aneurysm, not even after repeated 3DRA.

References

1. Linn FH, Rinkel GJ, Algra A, van Gijn J. Incidence of subarachnoid hemorrhage: role of region, year, and rate of computed tomography-a meta-analysis. Stroke 1996; 27:625–629
2. van Rooij WJ, Sprengers ME, de Gast AN, Peluso JP, Sluzewski M. 3D rotational angiography: the new gold standard in the detection of additional intracranial aneurysms. AJNR Am J Neuroradiol 2008;29:976-9
3. Bechan RS, van Rooij SB, Sprengers ME, Peluso JP, Sluzewski M, Majoie CB, van Rooij WJ. CT-angiography versus 3D rotational angiography in patients with subarachnoid hemorrhage. Neuroradiology 2015;57:1239-46
4. Bechan RS, van Rooij WJ, Peluso JP, Sluzewski M. Yield of repeat 3D angiography in patients with aneurysmal-type subarachnoid hemorrhage. AJNR Am J Neuroradiol 2016;37:2299-2303
5. van Gijn J, Rinkel GJ. Subarachnoid haemorrhage: diagnosis, causes and management. Brain 2001 Feb;124(Pt 2):249-78.
6. Van Gijn J, Kerr RS, Rinkel GJ. Subarachnoid hemorrhage. Lancet 2007;369:306-18
7. Mensing LA, Vergouwen MDI, Laban KG, Ruigrok YM, Velthuis BK, Algra A, Rinkel GJE. Perimesencephalic Hemorrhage: A review of epidemiology, risk factors, presumed cause, clinical course, and outcome. Stroke 2018;49:1363-70
8. Rinkel GJ, van Gijn J, Wijdicks EF. Subarachnoid hemorrhage without detectable aneurysms: a review of the causes. Stroke 1993;24:1403-09
9. van der Schaaf IC, Velthuis BK, Gouw A, et al. Venous drainage in perimesencephalic haemorrhage. Stroke 2004;35:1614-18
10. Velthuis BK, Rinkel GJ, Ramos LM, et al. Perimesencephalic haemorrhage: exclusion of vertebrobasilar aneurysms with CT angiography. Stroke 1999;30:1103-09
11. Roethlisberger M, Achermann R, Bawarjan S, Stienen MN, Fung C, D'Alonzo D, Maldaner N, Ferrari A, Corniola MV, Schöni D, Goldberg J, Valsecchi D, Robert T, Maduri R, Seule MA, Burkhardt JK, Marbacher S, Bijlenga P, Blackham KA, Bucher HC, Mariani L, Guzman R, Zumofen DW; Swiss SOS group Predictors of Occurrence and Anatomic Distribution of Multiple Aneurysms in Patients with Aneurysmal Subarachnoid Hemorrhage. World Neurosurg 218;111:e199-e205
12. Rinkel GJ, Djibuti M, Algra A, van Gijn J. Prevalence and risk of rupture of intracranial aneurysms; A systematic review. Stroke 1998;29:251-256
13. Qureshi AI, Vazquez G, Tariq N et al. Impact of International Subarachnoid Aneurysm Trial results on treatment of ruptured intracranial aneurysms in the United States. Clinical article. J Neurosurg. 2011 ;114):834-41
14. Kozba-Gosztyla M, Czapiga B, Jarmundowicz W. Aneurismal subarachnoid hemorrhage: who remains for surgical treatment in the post-ISAT era? Arch Med Sci 2015; 11: 536–543

15. Flett LM, Chandler CS, Giddings D et al. Aneurysmal subarachnoid hemorrhage: management strategies and clinical outcomes in a regional neuroscience center. AJNR Am J Neuroradiol 2005;26: 367-372.
16. Arnaout OM, Gross BA, Eddleman CS, et al. Posterior fossa arteriovenous malformations. Neurosurg Focus. 2009;26:E12.
17. Gonzalez AM, Narata AP, Yilmaz H et al. Blood blister-like aneurysms: single center experience and systematic literature review. Eur J Radiol 2014;83:197-205
18. Peluso JP, van Rooij WJ, Sluzewski et al. Endovascular treatment of symptomatic intradural vertebral dissecting aneurysms. AJNR Am J Neuroradiol 2008;29:102-6
19. Bakker NA, Uyttenboogaart M, Eshghi OS et al. Appreciation of CT-negative, lumbar puncture-positive subarachnoid haemorrhage: risk factors for presence of aneurysms and diagnostic yield of imaging. J Neurol Neurosurg Psychiatry 2014;85:885-8
20. Balinger KJ, Elmously A, Hoey BA et al. Selective computed tomographic angiography in traumatic subarachnoid haemorrhage: a pilot study. J Surg Res 2015;199:183-9

CHAPTER

3

CT Angiography versus 3D Rotational Angiography in patients with subarachnoid hemorrhage

Bechan RS, van Rooij SB, Sprengers ME, Peluso JP, Sluzewski M, Majoie CB, van Rooij WJ

Neuroradiology 2015;57:1239-1246

Introduction
CTA is increasingly used as primary diagnostic tool to replace DSA in patients with SAH. However, 3D Rotational Angiography has substituted DSA as reference standard. In this prospective observational study, we compare CTA with 3DRA of all cerebral vessels in a large cohort of patients with SAH.

Methods
Of 179 consecutive patients with SAH admitted between March 2013 and July 2014, 139 underwent 64-256 detector-row CTA followed by complete cerebral 3DRA within 24 hours. In 86 patients (62%), 3DRA was performed under general anesthesia. Two observers from outside hospitals reviewed CTA data.

Results
In 118 of 139 patients (85%), 3DRA diagnosed the cause of hemorrhage: 113 ruptured aneurysms, 3 arterial dissections, 1 micro-AVM and 1 reversible vasoconstriction syndrome. On CTA, both observers missed all 5 non-aneurysmal causes of SAH. Sensitivity of CTA in depicting ruptured aneurysms was 0.88-0.91 and accuracy was 0.88-0.92. Of 113 ruptured aneurysms, 28 were ≤3 mm (25%) and of 95 additional aneurysms, 71 were ≤3 mm (75%). Sensitivity of depicting aneurysms ≤3 mm was 0.28-0.43. Of 95 additional aneurysms, the two raters missed 65 (68%) and 58 (61%). Sensitivity in detection was lower in aneurysms of the internal carotid artery than in other locations.

Conclusion
CTA had some limitations as primary diagnostic tool in patients with SAH. All non-aneurysmal causes for SAH and one in 10 ruptured aneurysms were missed. Performance of CTA was poor in aneurysms ≤ 3mm. The majority of additional aneurysms were not depicted on CTA.

Abstract

Introduction

Subarachnoid hemorrhage is a serious disease with high morbidity and mortality. Approximately 80% of subarachnoid hemorrhages are caused by ruptured intracranial aneurysms [1]. Early endovascular or surgical treatment is advocated to prevent recurrent hemorrhage. The standard of detection and anatomic evaluation of intracranial aneurysms has long been DSA. With modern multi detector CT techniques, non-invasive pretreatment assessment of intracranial aneurysms is considered equally diagnostic to DSA by many authors [2]. At some institutions, multi-detector CT angiography (CTA) has replaced DSA in the preoperative evaluations of patients with intracranial aneurysms. Many previous studies comparing the diagnostic accuracy in depicting intracranial aneurysms of CTA with DSA have been conducted [2]. However, the value of CTA in patients with acute subarachnoid hemorrhage remains controversial because of methodological weaknesses in many studies. For example, most studies excluded CT studies with poor image quality because of patient motion. With modern 3D Rotational Angiography (3DRA), substantially more aneurysms can be depicted than with conventional 2D DSA but most studies have used 2D DSA as standard reference [3,4,5]. In most studies other possible cause of subarachnoid hemorrhage like arterial dissections, arterio-venous malformations, moyamoya syndrome, dural fistula or reversible vasospasm syndrome are disregarded. In this study, we evaluate the diagnostic accuracy of CTA in the detection of intracranial aneurysms or other vascular disorders in a large consecutive cohort of patients with acute subarachnoid hemorrhage. In particular, we compare daily practice CTA acquired with 3 different multi-detector CT scanners with 64-, 128- and 256-detector rows with 3DRA under optimal conditions, including general anesthesia in intubated and uncooperative patients.

Materials and Methods

Patient population

This observational study with prospectively collected data was compliant with institutional privacy policy. The Institutional Review Board gave exempt status for approval and informed consent.

Between March 2013 and July 2014, 179 patients with SAH were admitted. Diagnosis of SAH was established with CT scan or lumbar puncture. Four patients with SAH directly proceeded to angiography without CTA. Of the remaining 175 patients, 139 underwent CTA followed by 3DRA within 24 hours. In 36 patients, 3DRA was not performed because of perimesencephalic hemorrhage pattern (n=15), moribund clinical condition (n=10), trauma and SAH (n=9) or doubtful positive liquor puncture (n=2). There were 99 women (71%) and 40 men (29%) with a mean age of 58 ± 12 years. In 86 patients (62%), 3DRA was performed under general anesthesia. CTA was done under general anesthesia in 1 patient.

CT Angiography

CTA was performed on either one of three CT scanners: Philips Brilliance iCT 256 detector-row, Philips Ingenuity 128 detector-row (Philips Healthcare, Best, the Netherlands) and Siemens Somatom Definition AS 64 detector-row (Siemens, Erlangen, Germany). Volume CT was routinely performed at 130 mA and 100-120 kVp. Collimation, rotation time and pitch were optimized for the individual CT scanner according to recommendations of the manufacturer. A 90 mL dose of iodinated contrast medium (iopromide, 270 mg of iodine/mL, Visipaque 270; GE Healthcare, Cork, Ireland) was injected at a rate of 4.0 mL/sec into an antecubital vein via a 20-gauge catheter, followed by 40 mL of saline solution. CT scanning was triggered by using a bolus-tracking technique, with the region of interest placed in the aortic arch. Image acquisition started 8 seconds after the attenuation reached the predefined threshold of 130-150 HU. The scanning time was approximately 5.0-7.0 seconds. Images were reconstructed with a 0.9-1.0 mm section thickness and a 0.45- 0.5 mm increment with an UB or I26f kernel. Volume CT dose index and dose-length product were 25.3-26.7 mGy and 475-576 mGy·cm, respectively.

3D Rotational Angiography

Angiography was performed on a biplane angiographic system (Allura Xper FD 20/10, Philips Healthcare, Best, the Netherlands). In 86 uncooperative or intubated patients (62%), 3DRA was performed under general anesthesia. A single 3D rotational angiographic run was acquired of both internal carotid arteries and one vertebral artery with hand injection of 12-20 ml of contrast material. When the contralateral distal vertebral artery was not visualized, an additional 2D biplane run was performed of this vertebral artery. The tube rotation arc was 240° (one rotation used), with a rotation time of 4.1 seconds. The images were reconstructed in a 256 × 256 matrix. The rotational angiographic data were transferred to an independent workstation (Integris 3D, Philips Healthcare) for instant generation of 3D reformatted images. When possible, angiography was followed immediately by endovascular treatment under general anesthesia. Patients with aneurysms not suitable for coiling were scheduled for surgery.

Analysis of CT Angiography

CTA data were reformatted on an independent 3D workstation (Philips IntelliSpace Portal). Maximum intensity projection, volume rendering, and multiplanar reformatting was performed by three neuroradiologists (WR, JP and MS with 12, 10 and 12 years of post-processing experience). Source images, post-processed images and 3D reconstructions with bone removal were transferred to PACS (IDS7, Sectra, Linköping, Sweden). Native CTs and CTA data were collected in a dedicated work list in PACS and were reviewed by two observers from outside hospitals (SR with 4 years experience and MES with 15 years experience). Both observers had all raw data and reconstructions available and could make new reconstructions on the 3D workstation. Both observers were blinded

for additional imaging or clinical findings. Aneurysms were allocated according to 18 predefined locations and in 4 vascular territories: Anterior cerebral artery, middle cerebral artery, internal carotid artery and posterior circulation. Aneurysms were classified as ruptured or as additional unruptured. Other vascular disorders were separately recorded.

Analysis of 3D Rotational Angiography

3D reformatted images were reviewed on the workstation by the senior author (WR with 26 years experience in neuroradiology) and served as reference standard. Presence, location and size of aneurysms were recorded in a database. Aneurysms were allocated to one of 18 predefined locations. In patients with multiple aneurysms, the ruptured aneurysm was identified based on bleeding pattern on CT, aneurysm size and angiographic morphology. Other vascular disorders that might be responsible for the subarachnoid hemorrhage such as arterial dissections, arteriovenous malformations, moyamoya phenomenon or reversible vasospasm syndrome were separately recorded. In patients without an obvious vascular disorder that might be responsible for the SAH, 3DRA was repeated after 1 week.

Statistical analysis

Quantitative variables were expressed as mean ± standard deviation, and categorical variables were expressed as frequencies or percentages. In this study, 3DRA was considered a diagnostic standard for the evaluation of cerebral aneurysms and other vascular disorders. Sensitivity, specificity, and accuracy of CTA in depicting cause of SAH and aneurysms (overall, ≤3 mm and 4mm and larger) were calculated on per-patient basis. Agreement between the two raters was assessed using Kappa statistics (poor agreement, $\kappa = 0$; slight agreement, $\kappa = 0.01–0.20$; fair agreement, $\kappa = 0.21–0.40$; moderate agreement, $\kappa = 0.41–0.60$; good agreement, $\kappa = 0.61–0.80$; and excellent agreement, $\kappa = 0.81–1.00$). Statistical analysis was performed with MedCalc Statistical Software version 14.12.0 (MedCalc Software bvba, Ostend, Belgium; http://www.medcalc.org; 2014).

Results

Results of 3DRA

In 118 of 139 patients (85%), 3DRA diagnosed the cause of hemorrhage, in 114 patients at initial 3DRA and in 4 after repeated 3DRA. There were 113 patients with a ruptured aneurysm, 2 patients with a supraclinoid carotid artery dissection, 1 patient with a vertebral dissection, 1 patient with a cervical micro-AVM and 1 patient with a reversible vasoconstriction syndrome (this patient also had a 3 mm middle cerebral artery aneurysm not considered the cause of hemorrhage). In 25 patients, initial 3DRA was negative. In 9 patients with probable perimesencephalic bleeding pattern, 3DRA was not repeated. In 16 patients with definite aneurysmal bleeding pattern repeated 3DRA showed a ruptured aneurysm that was not visible on first 3DRA in 4: 8 mm supraclinoid dissection aneurysm

(fig. 1), 1 mm distal superior cerebellar artery aneurysm, 2 mm posterior communicating aneurysm, 1 mm A1 aneurysm (fig. 2). 3DRA detected 208 aneurysms (113 ruptured, 94 additional and 1 unruptured) in 114 patients. Sixty-two patients had 1 aneurysm (54%), 24 patients had 2 aneurysms (21%), 16 patients had 3 aneurysms (14%), 11 patients had 4 aneurysms (10%), and 1 patient had 5 aneurysms (0.9%). Of 113 ruptured aneurysms, 28 were ≤3 mm (25%) and of 95 additional aneurysms, 71 were ≤3 mm (75%).

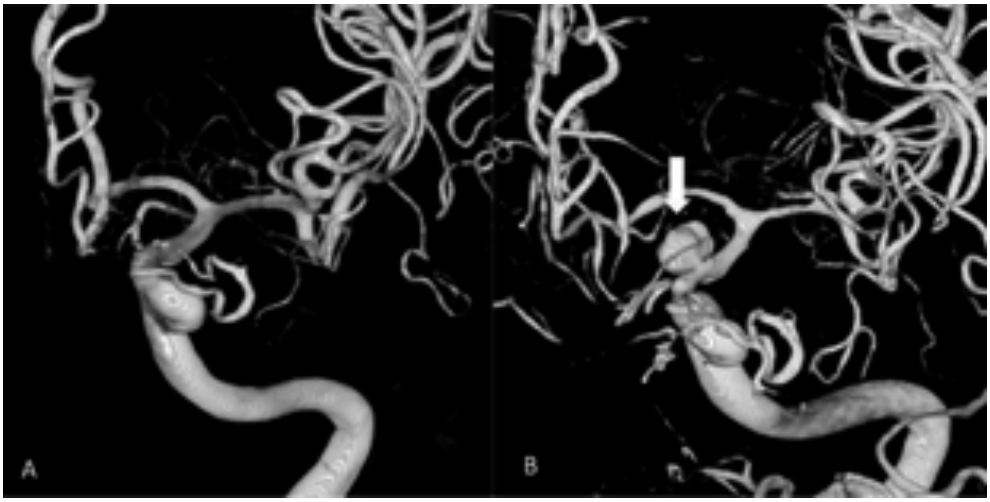

Figure 1. A 43-year-old woman with acute SAH
A: 3DRA of the right internal carotid artery is normal several hours after the ictus
B: repeat 3DRA one week later demonstrates 8 mm dissecting aneurysm of the supraclinoid carotid artery (arrow)

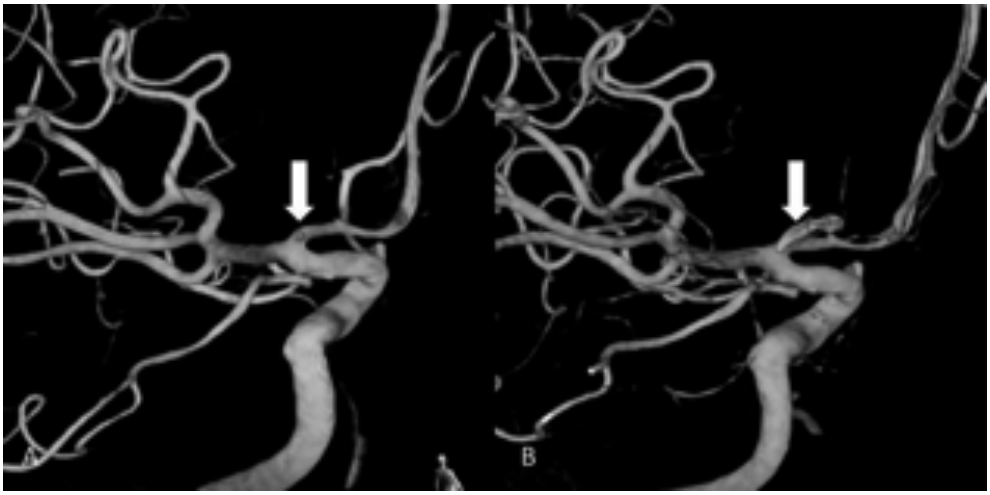

Figure 2. A 56-year-old woman with acute SAH
A: repeat 3DRA one week after ictus demonstrates a 1 mm aneurysm on the A1 (arrow)
B: 3DRA after clipping confirms obliteration of the small aneurysm (arrow)

Diagnostic performance of CTA

Results of CTA of both readers are summarized in Tables 1 and 2.

Tabel 1. Results of CT Angiography in depicting aneurysms

	Sensitivity	Specificty	PPV	NPV	Accuracy
Cause of SAH					
Rater 1	0.88 (0.80-0.93)	0.87 (0.66-0.97)	0.97 (0.92-0.99)	0.57 (0.39-0.74)	0.87
Rater 2	0.84 (0.76-0.90)	0.87 (0.66-0.97)	0.97 (0.92-0.99)	0.51 (0.35-0.68)	0.84
All aneurysms					
Rater 1	0.68 (0.61-0.74)	0.78 (0.56-0.92)	0.97 (0.92-0.99)	0.21 (0.13-0.31)	0.69
Rater 2	0.59 (0.52-0.66)	0.74 (0.52-0.90)	0.95 (0.90-0.98)	0.17 (0.10-0.25)	0.61
Ruptured aneurysms					
Rater 1	0.91 (0.84-0.96)	0.96 (0.78-0.99)	0.99 (0.95-1)	0.69 (0.50-0.84)	0.92
Rater 2	0.88 (0.80-0.93)	0.87 (0.66-0.97)	0.97 (0.92-0.99)	0.59 (0.41-0.75)	0.88
Additional aneurysms					
Rater 1	0.38 (0.28-0.49)	0.83 (0.61-0.95)	0.90 (0.76-0.97)	0.25 (0.16-0.36)	0.47
Rater 2	0.31 (0.22-0.41)	0.87 (0.6-0.97)	0.91 (0.75-0.98)	0.24 (0.15-0.34)	0.42
Aneurysms ≤3 mm					
Rater 1	0.43 (0.33-0.53)	0.83 (0.61-0.94)	0.91 (0.79-0.97)	0.25 (0.16-0.37)	0.50
Rater 2	0.28 (0.19-0.38)	0.83 (0.61-0.95)	0.87 (0.70-0.96)	0.21 (0.13-0.31)	0.38
Aneurysms > 3mm					
Rater 1	0.90 (0.83-0.95)	0.96 (0.78-0.99)	0.99 (0.95-1)	0.67 (0.48-0.82)	0.91
Rater 2	0.86 (0.79-0.92)	0.91 (0.72-0.99)	0.98 (0.93-1)	0.58 (0.41-0.75)	0.87

Tabel 2. Diagnostic performance of CTA in detecting aneurysms per location in major vascular territories.

	Sensitivity	Specificty	PPV	NPV	Accuracy
Anterior Cerebral A					
Rater 1	0.76 (0.64-0.86)	1 (0.88-1)	1 (0.93-1)	0.65 (0.49-0.79)	0.84
Rater 2	0.65 (0.52-0.77)	1 (0.88-1)	1 (0.91-1)	0.57 (0.42-0.71)	0.76
Internal Carotid A					
Rater 1	0.55 (0.42-0.68)	0.89 (0.72-0.98)	0.92 (0.78-0.98)	0.48 (0.34-0.62)	0.66
Rater 2	0.38 (0.26-0.52)	0.97 (0.82-0.99)	0.96 (0.79-0.99)	0.43 (0.31-0.56)	0.57
Middle Cerebral A					
Rater 1	0.77 (0.63-0.87)	0.89 (0.72-0.98)	0.93 (0.81-0.99)	0.68 (0.50-0.82)	0.81
Rater 2	0.66 (0.52-0.78)	0.86 (0.68-0.96)	0.90 (0.76-0.97)	0.58 (0.42-0.73)	0.57
Posterior Circulation					
Rater 1	0.55 (0.36-0.72)	1 (0.88-1)	1 (0.81-1)	0.65 (0.49-0.79)	0.75
Rater 2	0.51 (0.33-0.69)	0.86 (0.68-0.96)	0.81 (0.58-0.94)	0.61 (0.45-0.76)	0.68

A=Artery, PPV=positive predictive value, NPV= negative predictive value. 95% CI between brackets

Results of CTA in detecting the cause of SAH

Of 139 patients with a SAH who underwent 3DRA and CTA, a cause for the SAH was established in 118 patients.

Both raters missed all 5 non-aneurysmal causes (cervical micro AVM, vertebral dissection, 2 supraclinoid carotid artery dissections and reversible vasoconstriction syndrome).

Rater 1 missed 10 of 113 ruptured aneurysms (9%): 2 posterior communicating artery aneurysms (2 and 6 mm), 2 anterior communicating aneurysms (2 and 3 mm), 2 superior cerebellar artery aneurysms of 1 mm (fig 3) and 2 mm, 1 PICA aneurysm (2 mm), 1 A1 aneurysm (1 mm), 1 pericallosal artery aneurysm (2 mm), and 1 basilar tip aneurysm (7 mm). Rater 1 diagnosed 3 false positive findings: one dural fistula, 1 arteriovenous malformation, and 1 middle cerebral artery aneurysm.

Rater 2 missed 14 of 113 ruptured aneurysms (12%): 5 anterior communicating artery aneurysms (2, 2, 3, 3 and 6 mm), 4 posterior communicating aneurysms (2, 2, 5, and 5 mm), 2 superior cerebellar artery aneurysms (1 and 2 mm), 1 A1 aneurysm (1 mm), 1 PICA aneurysm (2 mm), and 1 pericallosal artery aneurysm (2 mm). Rater 2 diagnosed

3 false positive aneurysms: 1 basilar tip aneurysm, 1 posterior communicating aneurysm and 1 PICA aneurysm.

The Kappa coefficient between the two raters in establishing the cause of SAH was 0.83 (95%CI, 0.73-0.93) indicating excellent agreement.

Results of CTA in aneurysm detection

Diagnostic performance of CTA in aneurysms ≤3 mm and >3 mm is displayed in Table 1 and diagnostic performance per location in Table 2. Sensitivity and specificity of detecting aneurysms larger than 3 mm was good especially in the anterior and middle cerebral artery territory. Sensitivity in detection was lower in aneurysms of the internal carotid artery than in other locations (fig. 4). Diagnostic value was low in detecting aneurysms ≤3 mm (fig. 3). Diagnostic value was also low in detecting additional aneurysms, as the majority of additional aneurysms were ≤3 mm. The Kappa coefficient between the two raters in detecting all aneurysms was 0.75 (95%CI, 0.67-0.83) indicating good agreement and in detecting additional aneurysms Kappa coefficient was 0.40 (95%CI, 0.19-0.60), indicating fair agreement.

Clinical relevance of missed vascular disorders on CTA

Rater 1 missed all 5 non-aneurysmal causes of SAH and 10 ruptured aneurysms. Furthermore, 58 of 95 (61%) additional aneurysms were missed on CTA. Twelve of 55 missed additional aneurysms in 10 patients were treated either by coiling or clipping. Five additional aneurysms in 4 patients were not treated because these patients died during hospital admission. Thirteen aneurysms in 14 patients are monitored by MRA. Treatment was judged not necessary in 25 aneurysms in 21 patients.

Rater 2 missed all 5 non-aneurysmal causes of SAH and 14 ruptured aneurysms. Furthermore, 65 of 95 (68%) additional aneurysms were missed on CTA. Seventeen of 68 missed additional aneurysms in 14 patients were treated either by coiling or clipping. Six additional aneurysms in 4 patients were not treated because these patients died during hospital admission. Twenty aneurysms in 14 patients are monitored by MRA. Treatment was judged not necessary in 28 aneurysms in 22 patients.

Figure 3. 1 mm ruptured aneurysm on the superior cerebellar artery missed on CTA in a 51-year-old man (arrow)

Figure 4. A 63-year-old woman with a ruptured large middle cerebral artery aneurysm
A: CTA demonstrates the large right middle cerebral artery aneurysm; there are no visible additional aneurysms
B: 3DRA of the left internal carotid artery reveals 4 mm additional para-ophthalmic carotid artery aneurysm (arrow), not visible on CTA

Discussion

In this prospective study comparing CTA and 3DRA, we found that diagnostic performance of CTA in a clinical setting of patients with SAH is hampered by limitations. In 139 patients, all 5 non-aneurysmal causes of SAH and one in 10 ruptured aneurysms were missed. Moreover, the majority of aneurysms that were additionally found on 3DRA were missed on CTA. Although positive predictive value of CTA seems acceptable both in very small and larger aneurysms, the exclusion of vascular pathology with CTA is unreliable. Overall, 30-40% of aneurysms diagnosed on 3DRA were missed on CTA. Most missed aneurysms were ≤3 mm but some missed aneurysms were 6-7 mm large in patients with poor image quality.

Our findings are in contrast to many previous studies. Several meta-analyses of the accuracy of CTA for diagnosing intracranial aneurysms have been published [2,6,7,8] with pooled sensitivities and specificities of >95% in the most recent studies [2,7]. There are several factors that can explain this discrepancy in sensitivity to detect the ruptured aneurysm in our study and in previous studies. First, in our study we used 3DRA under optimal clinical circumstances as a reference standard. It has been shown that 3DRA detects substantially more aneurysms than conventional 2D DSA, the reference used in almost all previous studies [3,4,5]. The complete cerebral vasculature was imaged with 3DRA in all patients. The majority of 3DRAs were performed under general anesthesia thereby eliminating image degradation by patient motion. This resulted in excellent 3D image quality with high aneurysm conspicuity; even 1 mm aneurysms were easily detected (figs 2 and 3). For example, in our patient cohort we found mean 1.8 aneurysm per patient (208 aneurysms in 114 patients) while in a comparable, although retrospective, study by Lu et al [9], mean 1.1 aneurysm per patient were found (459 aneurysms in 407 patients), which is substantially lower than in our study. Second, in patients with aneurysmal SAH and initial 3DRA negative findings, 3DRA was repeated one week later. Third, CTA was performed 24/7 in a daily clinical setting on 3 scanners with 64-, 128-, and 256-detector rows. Some CTA studies had poor image quality because of patient motion or suboptimal contrast bolus timing and these studies were not excluded. This explains why both observers missed some larger aneurysms. Our findings suggest that previous data in general overestimate the diagnostic performance of CTA in patients with SAH. Next to publication bias [2], methodology in many studies favors good results of CTA for example by using suboptimal reference standards such as 2D DSA and operative findings [14,15], exclusion of poor quality CTAs [6], exclusion of previously coiled or clipped patients [6], retrospective study design [14,16], selection of patients with aneurysms only [17], only performing angiography in patients with negative or inconclusive CTA [15], or comparing DSA and CTA in CT negative but CSF positive patients only [18]

Performance of CTA in our study was poor in detecting non-aneurysmal causes of SAH: both observers missed one cervical micro-AVM, one reversible vasospasm syndrome and 3 arterial dissections. Little is known in literature about sensitivity of CTA in arterial dissections since most studies of CTA in patients with SAH excluded other causes than aneurysms. In one study, CTA missed most carotid artery dissections causing SAH [10]. There are no data about CTA and SAH from vertebral artery dissections.

CTA was also poor in depicting aneurysms of ≤3 mm. In our patient cohort, a quarter (28 of 113) of ruptured aneurysms were ≤3 mm. Most additional aneurysms were ≤3 mm and most of these additional aneurysms were missed on CTA (fig. 4). Previous studies also found low sensitivities for detecting small aneurysms on CTA [11,12], especially, as in our study, aneurysms located on the internal carotid artery (13). This poor performance of CTA in small aneurysms makes CTA less suitable as a primary diagnostic tool in patients with SAH. Detecting all aneurysms that are present is important in clinical practice. Additional aneurysms can be treated at the same time as the ruptured aneurysm, either by a surgical or endovascular approach. Given the morbidity and costs associated with cerebral aneurysm treatment, accurate detection of all aneurysms before making a treatment decision is essential. Many missed additional aneurysms on CTA in our study were actually treated with clipping or coiling, either in the same session as the ruptured aneurysm or later after evaluation in a multidisciplinary team of neurosurgeons, neuroradiologists and neurologists.

Our data indicate that CTA is not suitable to replace 3DRA in the diagnostic work-up of patients with SAH. Too many aneurysms remain undetected, and other causes of SAH besides aneurysms are generally missed. Ruling out vascular pathology with CTA is impossible. At best, CTA can be useful to obtain a quick general impression of the vascular pathology for instance in patients who need emergency evacuation of a cerebral hematoma before angiography can be performed. When CTA identifies the ruptured aneurysm, 3DRA may be limited to the vessel harboring the aneurysm in selected patients for example very old patients in poor clinical condition. The use of CTA is even questionable in patients with SAH and a low a priori chance of having an aneurysm such as patients with trauma and SAH and patients with a perimesencephalic bleeding pattern. In these patients, CTA as a sole diagnostic tool may provide a false sense of security.

We agree with several of our colleagues who question the role of CTA in patients with SAH because both in patients with negative and positive CTA, catheter angiography still needs to be performed [19,20,21]. Although CTA is considered a non-invasive investigation, the extra load of contrast material can have a negative effect on renal function. In patients with SAH, CTA should be interpreted with restraint and 3DRA of at least the one cerebral vessel with the ruptured aneurysm should follow in all patients. Exclusion of vascular pathology with CTA is impossible.

References

1. Byyny RL, Mower WR, Shum N, et al. Sensitivity of noncontrast cranial computed tomography for the emergency department diagnosis of subarachnoid hemorrhage. Ann Emerg Med 2008;51:697-703
2. Westerlaan HE, van Dijk JM, Jansen-van der Weide MC, et al. Intracranial aneurysms in patients with subarachnoid hemorrhage: CT angiography as a primary examination tool for diagnosis-systematic review and meta-analysis. Radiology 2011;258:134-145
3. van Rooij WJ, Sprengers ME, de Gast AN, et al. 3D rotational angiography: the new gold standard in the detection of additional intracranial aneurysms. AJNR Am J Neuroradiol 2008;29:976-9
4. van Rooij WJ, Peluso JP, Sluzewski M, et al. Additional value of 3D rotational angiography in angiographically negative aneurysmal subarachnoid hemorrhage: how negative is negative? AJNR Am J Neuroradiol 2008;29:962-6
5. Ishihara H, Kato S, Akimura T, et al. Angiogram-negative subarachnoid hemorrhage in the era of three dimensional rotational angiography. J Clin Neurosci 2007;14:252-5
6. Chappell ET, Moure FC, Good MC: Comparison of computed tomographic angiography with digital subtraction angiography in the diagnosis of cerebral aneurysms: a meta-analysis. Neurosurgery 2003;52:624-631
7. Menke J, Larsen J, Kallenberg K: Diagnosing cerebral aneurysms by computed tomographic angiography: meta-analysis. Ann Neurol 2011;69: 646-654
8. van Gelder JM: Computed tomographic angiography for detecting cerebral aneurysms: implications of aneurysm size distribution for the sensitivity, specificity, and likelihood ratios. Neurosurgery 53:597-605, 2003
9. Lu L, Zhang LJ, Poon CS, et al. Digital subtraction CT angiography for detection of intracranial aneurysms: comparison with three-dimensional digital subtraction angiography. Radiology 2012;262:605-12
10. Gonzalez AM, Narata AP, Yilmaz H, et al. Blood blister-like aneurysms: single center experience and systematic literature review. Eur J Radiol 2014;83:197-205
11. Dammert S, Krings T, Moller-Hartmann W, et al. Detection of intracranial aneurysms with multi-slice CT: comparison with conventional angiography. Neuroradiology 2004;46:427-434
12. White PM, Wardlaw JM, Easton V: Can non-invasive imaging accurately depict intracranial aneurysms? A systematic review. Radiology 2000;217: 361-370
13. Romijn M, Gratama van Andel HA, van Walderveen MA, et al. Diagnostic accuracy of CT angiography with matched mask bone elimination for detection of intracranial aneurysms: comparison with digital subtraction angiography and 3D rotational angiography. Am J Neuroradiol 2008; 29:134-139

14. Nijjar S, Patel B, McGinn G, et al. Computed tomographic angiography as the primary diagnostic study in spontaneous subarachnoid hemorrhage. J Neuroimaging 2007;17:295–299
15. Westerlaan HE, Gravendeel J, Fiore D, et al. Multislice CT angiography in the selection of patients with ruptured intracranial aneurysms suitable for clipping or coiling. Neuroradiology 2007;49:997-1007
16. Colen TW, Wang LC, Ghodke BV, et al. Effectiveness of MDCT angiography for the detection of intracranial aneurysms in patients with nontraumatic subarachnoid hemorrhage. AJR Am J Roentgenol 2007;189:898-903
17. Zhang LJ, Wu SY, Niu JB, et al. Dual-energy CT angiography in the evaluation of intracranial aneurysms: image quality, radiation dose, and comparison with 3D rotational digital subtraction angiography. AJR Am J Roentgenol 2010;194:23-30
18. Lim LK, Dowling RJ, Yan B, Mitchell PJ. Can CT angiography rule out aneurysmal subarachnoid haemorrhage in CT scan-negative subarachnoid haemorrhage patients? J Clin Neurosci 2014;21:191-3
19. Kallmes DF, Layton K, Marx WF, et al. Death by nondiagnosis: why emergent CT angiography should not be done for patients with subarachnoid hemorrhage. AJNR Am J Neuroradiol 2007;28:1837-8
20. Pradilla G, Wicks RT, Hadelsberg U, et al. Accuracy of computed tomography angiography in the diagnosis of intracranial aneurysms. World Neurosurg 2013;80:845-52
21. Moran CJ. Aneurysmal subarachnoid hemorrhage: DSA versus CT angiography-is the answer available? Radiology 2011;258:15-7

CHAPTER

4

Fenestrations of intracranial arteries detected with 3D rotational angiography

van Rooij SB, van Rooij WJ, Sluzewski M, Sprengers ME

AJNR Am J Neuroradiol 2009;30:1347–50

Abstract

Background and Purpose

Fenestrations of intracranial arteries are variants resulting from incomplete fusion of primitive vessels. An association with aneurysms is suggested in many studies. On conventional angiography, fenestrations are rarely visible. 3D rotational angiography (3DRA) provides improved visualization of cerebral vessels from any desired angle. We used 3DRA to assess the frequency and location of fenestrations of intracranial arteries and a possible relationship with aneurysms.

Materials and Methods

In 208 patients with suspected intracranial aneurysms, 3DRA of 1, 2, or 3 cerebral vessels (in 143, 16, and 49 patients) was reviewed for the presence and location of fenestrations and aneurysms. When fenestrations were present in combination with aneurysms, we noted the relationship of the locations.

Results

In 59 of 208 patients, 61 fenestrations were detected (28%). Fenestrations were more frequent in the anterior than in the posterior circulation (23% versus 7%), and the most common location was the anterior communicating artery (AcomA) (43 of 61, 70%). The frequency of fenestrations in 185 patients with aneurysms was not different from the frequency in 23 patients without aneurysms. Of 220 aneurysms present in 208 patients, 10 aneurysms (4.5%) were located on a fenestration. Of 61 fenestrations, 51 (84%) were not associated with an aneurysm.

Conclusions

With 3DRA, fenestrations were found in 28% of patients. In our study, fenestrations occurred more often in the anterior than in the posterior circulation, and the most common location was the AcomA. A definite relationship between fenestrations and aneurysms cannot be concluded from our data.

Introduction

Fenestrations of intracranial arteries are segmental duplications of the lumen into 2 distinct endothelium-lined channels, which may or may not share their adventitial layer [1]. They can range from a small focus of divided tissue to long-segment duplication. Fenestrations are the result of partial failure of fusion of paired primitive embryologic vessels or incomplete obliteration of different anastomosis in a primitive vascular network [1,2]. The association of fenestrations with aneurysms has been suggested in many small case series, though the exact relationship is not well defined. Surgical and anatomic studies indicate that fenestrations of intracranial arteries occur commonly, especially in the anterior communicating artery (AcomA) complex [3-6]. Demonstration of fenestrations on conventional angiography is exceptional. Most fenestrations are only visible from 1 specific viewing angle, which is likely not present in the limited available projections of conventional angiography [1-7]. Because with 3D imaging any desired viewing angle is on hand, the detection rate of fenestrations has improved [8-12]. Few data are available on the frequency and distribution of locations of fenestrations. In this study, we assessed the frequency, location, and relationship with aneurysms of fenestrations of intracranial arteries by using 3D rotational angiography (3DRA) performed in patients with suspected intracranial aneurysms.

Materials and Methods

3DRA

In our practice, in all patients with suspected intracranial aneurysms in whom treatment is being considered, an intra-arterial digital subtraction angiography is performed of all cerebral vessels. When an aneurysm is apparent or suspected, additional 3DRA is performed of the vessel harboring the aneurysm to evaluate its presence and anatomy and to determine the type of treatment (coiling, surgery, or parent vessel occlusion). In patients with aneurysms allocated to coiling, 3DRA is repeated immediately before coiling with the patient under general anesthesia, to find out the best working projection. Angiographic imaging was performed on a biplane neuro-angiographic unit (Integris BN 3000 Neuro; Philips Healthcare, Best, the Netherlands). 3DRA was performed with an 8-second 180° rotational run with acquisition of 200 images and with injection of 3– 4 mL of contrast material per second in the internal carotid or vertebral artery. On a dedicated workstation, 3D reconstructions were made in a maximal matrix of 512 x 512 x 512 [3].

Patients

For the purpose of this retrospective study, we included patients who had undergone 3DRA and who had the raw 3DRA dataset available for review on a hard disk or a compact disk. Raw datasets were required to make high-resolution reconstructions on the workstation

with new sophisticated software to evaluate the presence of fenestrations. Patients were thus not consecutive. We included 208 3DRA datasets that were made between June 2004 and October 2008. The following patient and imaging characteristics were recorded in a data base: examination date, patient name and sex, date of birth, presence and location of aneurysms visible on the 3DRA dataset, presence and location of fenestrations, and number of vessels with rotational runs. In patients with both aneurysms and fenestrations, we classified the relation of the location of the fenestration with the location of the aneurysms as remote from the fenestration, adjacent but unrelated to the fenestration, or on the fenestration itself (Fig 1). In addition, we assessed whether detected fenestrations were visible in retrospect on standard projections of 2D angiographic images.

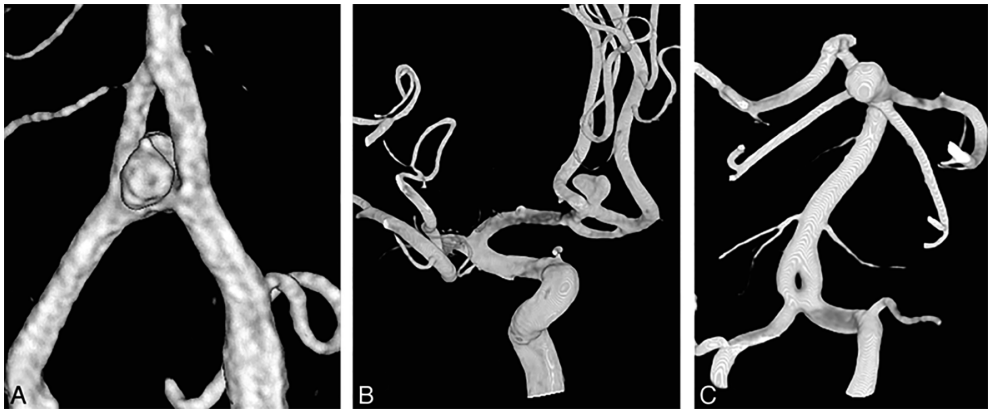

Figure 1. Classification of the relation of the location of the fenestration with the location of the aneurysm. A, Aneurysm is located on the fenestration in a patient with a vertebrobasilar junction aneurysm and a proximal basilar fenestration. B, Aneurysm is located adjacent to (but not on) a fenestration in a patient with an AcomA aneurysm and a fenestration of the AcomA. C, Aneurysm is located remote from a fenestration in a patient with a basilar tip aneurysm and a proximal basilar fenestration.

Data analysis

We compared sex distribution in patients with and without fenestrations. In patients with and without intracranial aneurysms, we compared the proportion of patients with a fenestration with those without a fenestration. In patients with fenestrations, we compared the proportion of fenestrations in the anterior circulation with the pro- portion of fenestrations in the posterior circulation. For comparison of proportions, the x^2 test was used.

Results

Patients

Of 208 patients with re-evaluated 3DRA datasets, 71 (34%) were men and 137 (66%) were women, with a mean age of 52.8 years (range, 14 – 84 years). Of 208 patients, 49 had 3DRA of 3 vessels (both carotid arteries and a vertebral artery), 16 had 3DRA of 2 vessels (14 patients with both carotid arteries and 2 patients with a carotid and a vertebral artery), and 143 patients had 3DRA of 1 vessel (carotid artery in 122 patients and vertebral artery in 21 patients). Altogether, 248 carotid arteries and 72 vertebral arteries were imaged with 3DRA. In 23 patients, no aneurysm was detected. The remaining 185 patients had 218 aneurysms with the following locations: AcomA, 62 (28%); middle cerebral artery, 49 (22%); posterior communicating artery, 40 (18%); basilar artery, 13 (6%); cavernous sinus, 11 (5%); carotid tip, 11 (5%); anterior choroidal artery, 9 (4%); ophthalmic artery, 8 (4%); posterior inferior cerebellar artery, 6 (3%); superior cerebellar artery, 4 (2%); vertebral artery, 3 (1%); P1 segment of the posterior cerebral artery, 1 (1%); and anterior inferior cerebellar artery, 1 (1%).

Fenestrations

Results are summarized in Fig 2. Sixty-one fenestrations were present in 59 of 208 patients (28%, 2 patients had 2 fenestrations) with the following locations: AcomA in 43 (70%), middle cerebral artery in 12 (20%), posterior cerebral artery in 2 (3%), carotid artery in 1 (2%), vertebral artery in 1 (2%), superior cerebellar artery in 1 (2%), and basilar artery in 1 (2%). Of 59 patients with fenestrations, 22 (37%) were men and 37 (63%) were women. Sex distribution did not differ between patients with and without fenestrations. Of 61 fenestrations, 56 were located in the anterior circulation, diagnosed on 248 carotid artery 3DRAs, (23%), and 5 were located in the posterior circulation, diagnosed on 72 vertebral artery 3DRAs (7%). This difference was significant (P=.0043). Fifty-six fenestrations were present in 54 of the 185 patients (29%) with aneurysms. Five fenestrations were present in 5 of the 23 patients (22%) without aneurysms. This difference was not significant. The anatomic relationship of the 56 fenestrations and the aneurysms in 54 patients with aneurysms was as follows: aneurysm located on the fenestration itself in 10 (18%), aneurysm adjacent to the fenestration in 12 (21%), and aneurysm remote from the fenestration in 34 (68%). In 208 patients with 218 aneurysms, 10 aneurysms (4.5%) were located on a fenestration and 210 were not. Of 61 fenestrations, 51 (84%) were not associated with an aneurysm. Of 61 fenestrations detected on 3DRA, 10 (16%) were in retrospect visible on 2D angiographic images.

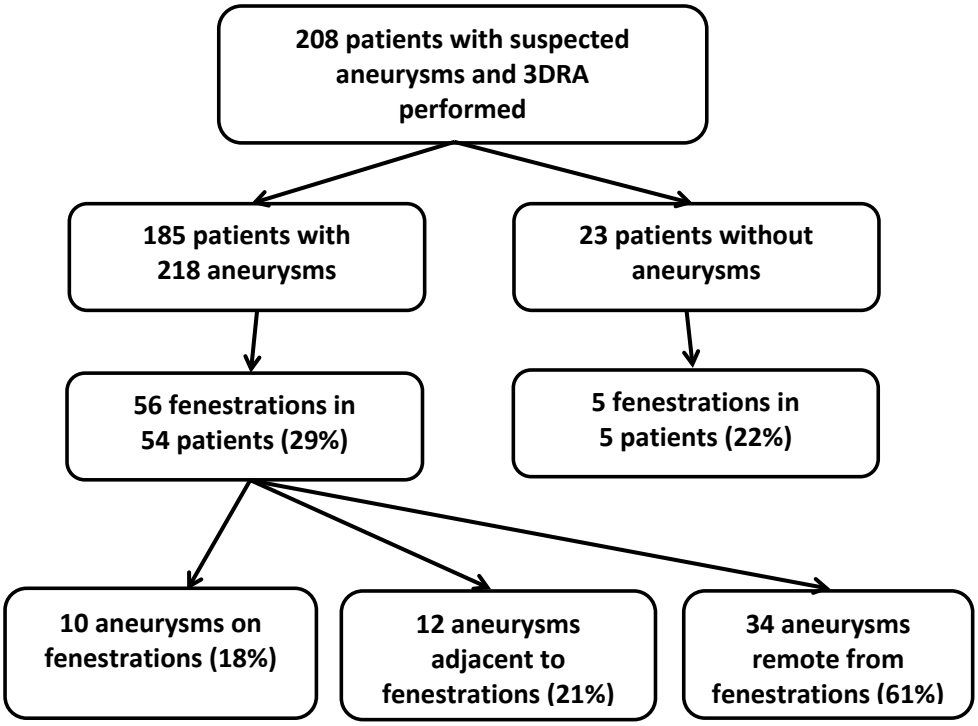

Figure 2. Flow chart of 208 patients with 3DRA.

Discussion

In this study, we found that fenestrations of intracranial arteries are commonly found with 3DRA imaging. The frequency of 28% for the presence of fenestrations found in this study is an underestimation because most patients had only 1 vessel territory imaged with 3DRA. With complete 3DRA evaluation of all cerebral vessels, a frequency of approximately 40% would probably be a realistic estimate. Although fenestrations can be located anywhere in the intracranial circulation (Fig 3), they occur more often in the anterior circulation than in the posterior circulation. The most common location is the AcomA, followed by the middle cerebral artery (Fig 4). Although most fenestrations are located on or near the circle of Willis, distal cerebral arteries can also be fenestrated (Fig 4C). The common occurrence of fenestrations of intracranial arteries, especially in the AcomA complex, is well known from anatomic and surgical studies [3-6]. However, with 2D angiography, fenestrations are rarely found: In 2 studies of 5190 and 4500 cerebral angiograms, fenestrations were reported in 0.7% and 0.07%, respectively [1,7]. Apparently, with 2D imaging, most fenestrations are overlooked or are invisible because of over projecting vessels, preferential flow in 1 limb,

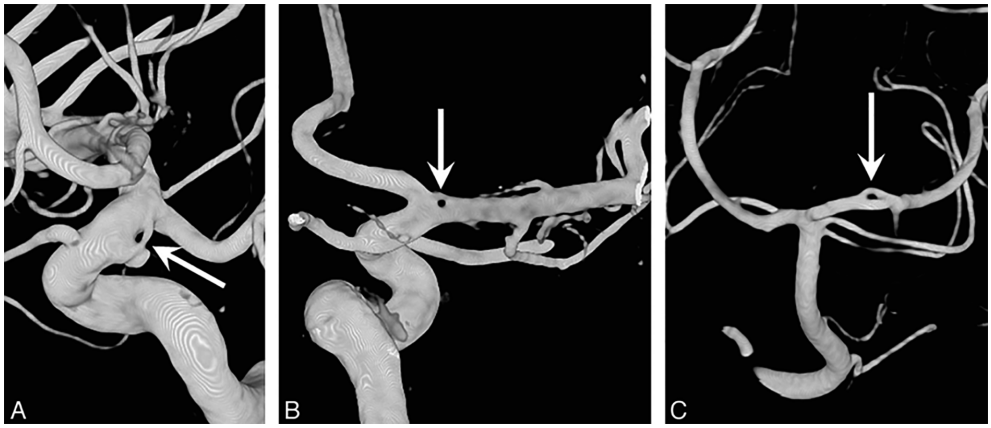

Figure 3. Unusual locations of fenestrations of intracranial arteries. A, Fenestration of the supraclinoid internal carotid artery associated with an aneurysm. B, A very small fenestration on the proximal middle cerebral artery. C, A short-segment fenestration of the posterior cerebral artery.

or location remote from the region of interest. Many fenestrations are only visible from specific viewing angles that are usually not available on 2D imaging. Also in our study, just a small minority of fenestrations was, in retrospect, visible on standard 2D angiographic projections. With the advanced postprocessing techniques of 3DRA, cerebral vessels can be evaluated from any desired angle, and complex vascular anatomy can be unraveled effectively, allowing detection of many vessel fenestrations. The advantage of 3D imaging in the detection of fenestrations has recently also been demonstrated in a study using CT angiography [8]. In this study, fenestrations were reported in 11% of patients. The lower reported frequency of intracranial fenestrations with CTA compared with 3DRA (despite complete imaging of the brain vasculature with CTA) reflects the lower resolution of

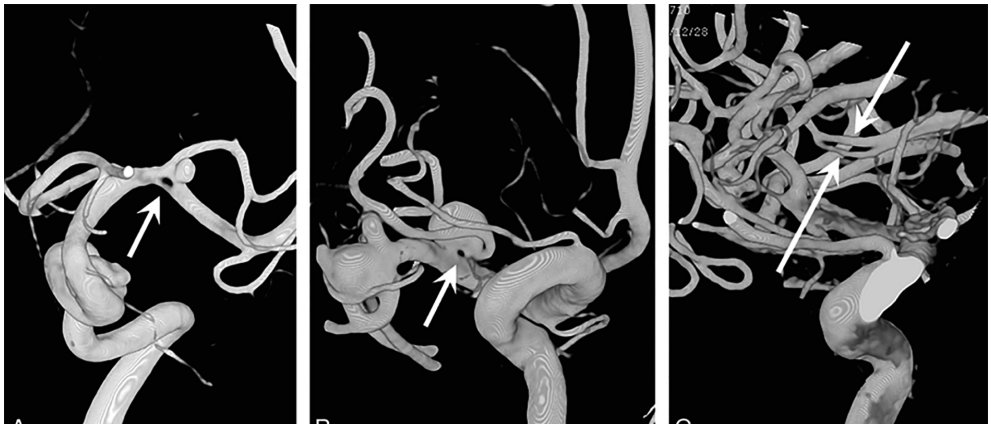

Figure 4. Examples of middle cerebral artery fenestrations (arrows). A, Fenestration at the bifurcation with an associated aneurysm. B, Small fenestration at the neck of an aneurysm in a patient with 2 middle cerebral artery aneurysms. C, A 10-mm segment fenestration in a distal middle cerebral artery (M3).

CTA combined with less sophisticated postprocessing software. Few data are available on the detection of fenestrations with MR angiography (MRA), but the frequency seems lower as reported with both 3DRA and CTA [10-12]. The association of aneurysms with fenestrations has been extensively documented, though the reason for this relationship is not well understood: Vessel wall microstructure at fenestrations is not different from that of normal cerebral vessels. At branching points, medial defects are equally as common in fenestrations as in normal vessel branching points. Aneurysms associated with fenestrations are classically thought to arise at the proximal end of a fenestration due to a combination of a medial defect and hemodynamic stresses, similar to aneurysm formation in the circle of Willis [13]. In our study, the frequency of fenestrations was not different in patients with or without aneurysms. Most fenestrations were not associated with an aneurysm on the fenestration itself, and most aneurysms were not located on a fenestration. Our patient group was selected on the suspicion or presence of intracranial aneurysms. These criteria resulted in a maximal bias toward patients with aneurysms and to an overrepresentation of aneurysms in respect to fenestrations. Therefore, a definite relationship between fenestrations and aneurysms cannot be concluded from our data. Also in a recent CTA study [8], fenestrations were found to be equally common in patients with and without aneurysms and an association of fenestrations and aneurysms could not be established either. On the other hand, a probable relation of aneurysms with fenestrations has been suggested for vertebral junction aneurysms because most of these rare aneurysms are associated with a proximal basilar fenestration [14-16]. Also, some unusual locations of fenestrations in combination with aneurysms in our patient group might suggest a relationship (Figs 3A and 4A, -B). Although fenestrations might not be related to aneurysms in general, fenestrations on specific locations could, nevertheless, be associated with aneurysms. Without the avail- ability of robust data on the frequency and location of fenestrations in the general population as a control, no definite relationship between fenestrations and aneurysms can be established. Perhaps, specific aneurysms (for example vertebral junction aneurysms) might be associated with a fenestration at that site. Presently available data indicate that the detection rate of fenestrations with 3DRA is higher than that with CTA or MRA.

Conclusions

With 3DRA, fenestrations were found in 28% of patients. Fenestrations occur more often in the anterior circulation than in the posterior circulation, and the most common location is the AcomA. A definite relationship between fenestrations and aneurysms cannot be concluded from our data.

References

1. Sanders WP, Sorek PA, Mehta BA. Fenestration of intracranial arteries with special attention to associated aneurysms and other anomalies. AJNR Am J Neuroradiol 1993;14:675– 80
2. Padget DH. The development of the cranial arteries in the human embryo. Contrib Embryol 1948;212:207– 61
3. Gomes FB, Dujovny M, Umansky F, et al. Microanatomy of the anterior cerebral artery. Surg Neurol 1986;26:129 – 41
4. Serizawa T, Saiki N, Yamaura A. Microsurgical anatomy and clinical significance of the anterior communicating artery and its perforating branches. Neurosurgery 1997;40:1211–16
5. Tao X, Yu XJ, Bhattarai B, et al. Microsurgical anatomy of the anterior communicating artery complex in adult Chinese heads. Surg Neurol 2006;65: 155– 61
6. Wollschlaeger G, Wollschlaeger PB, Lucas FV, et al. Experience and result with post-mortem cerebral angiography performed as routine procedure of the autopsy. AJR Am J Roentgenol 1967;101:68 – 87
7. Teal JS, Rumbaugh CL, Bergeron RT, et al. Angiographic demonstration of fenestrations of the intradural intracranial arteries. Radiology 1973;106:123
8. Bharatha A, Aviv RI, White J, et al. Intracranial arterial fenestrations: frequency on CT angiography and association with other vascular lesions. Surg Radiol Anat 2008;30:397– 401
9. de Gast AN, van Rooij WJ, Sluzewski M. Fenestrations of the anterior communicating artery: incidence on 3D angiography and relationship to aneurysms. AJNR Am J Neuroradiol 2008;29:296 –98
10. Uchino A, Kato A, Abe M, et al. Association of cerebral arteriovenous malformation with cerebral arterial fenestration. Eur Radiol 2001;11:493–96
11. Uchino A, Nomiyama K, Takase Y, et al. Anterior cerebral artery variations detected by MR angiography. Neuroradiology 2006;48:647–52
12. Uchino A, Takase Y, Nomiyama K, et al. Fenestration of the middle cerebral artery detected by MR angiography. Magn Reson Med Sci 2006;5:51–55
13. Finlay HM, Canham PB. The layered fabric of cerebral artery fenestrations. Stroke 1994;25:1799 – 806
14. Peluso JP, van Rooij WJ, Sluzewski M, et al. Aneurysms of the vertebrobasilar junction: incidence, clinical presentation, and outcome of endovascular treatment. AJNR Am J Neuroradiol 2007;28:1747–51
15. Campos J, Fox AJ, Vinuela F, et al. Saccular aneurysms in basilar artery fenestration. AJNR Am J Neuroradiol 1987;8:233
16. Kowada M, Yamaguchi K, Takahashi H. Fenestration of the vertebral artery with a review of 23 cases in Japan. Radiology 1972;103:343– 46

CHAPTER

5

WEB Treatment of Ruptured Intracranial Aneurysms: a Single Center Cohort of 100 Patients

van Rooij SBT, van Rooij WJ, Peluso JP, Sluzewski M, Bechan RS, Kortman HG, Beute GN, van der Pol B, Majoie CB

AJNR Am J Neuroradiol 2017;38:2282-2287

Introduction

The WEB device was recently introduced for intrasaccular treatment of wide necked aneurysms without the need for adjunctive devices. We present our results of primary treatment of ruptured aneurysms with the WEB, regardless of location or neck size.

Materials and Methods

Between February 2015 and April 2017, 100 ruptured aneurysms were selectively treated with the WEB. No supporting stents or balloons were used. There were 71 women, mean patient age 59 years (median 60, range 23-82).

Results

Mean aneurysm size was 5.6 mm (range 3-13 mm) and 42 aneurysms were ≤ 4mm. Sixty-six aneurysms (66%) had a wide neck defined as ≥4 mm or dome-neck ratio ≤ 1.5. There was 1 procedural rupture without sequelae. In 9 patients (9%), thrombo-embolic complications occurred. One poor grade patient died, neurological deficits remained in 3. Overall treatment related morbi-mortality was 4% (4 of 100, 95%CI 1.2-10.2%).

Two of 100 aneurysms were initially incompletely occluded and were additionally treated early. Of 80 eligible patients, 74 (93%) had 3 months' angiographic follow-up. Fifty-four aneurysms (73%) were completely occluded, 17 (23%) had a small neck remnant and 3 (4%) were incompletely occluded. One patient was additionally treated with a second WEB and in 2 patients additional treatment is scheduled. Overall reopening/retreatment rate was 6.8% (5 of 74, 95%CI 2.6-15.2%). There were no rebleeds during follow-up.

Conclusion

WEB treatment of small ruptured aneurysms was safe and effective. The WEB proved to be a valuable alternative to coils without the need for stents or balloons.

Introduction

Endovascular treatment with coils of wide-necked intracranial aneurysms mostly requires the use of a temporary protection balloon or a stent. However, this makes the procedure more complicated with a higher chance of complications [1-4]. With stents, periprocedural dual antiplatelet therapy is required and has to be prolonged for 3-6 months. With this anti-aggregation regimen, stent assisted coiling in ruptured aneurysms has a higher inherent risk for early rebleed or hemorrhage in the postoperative period. Despite anti-aggregation, thrombo-embolic complications still occur [5].

Recently, the intrasaccular flowdisruptor Woven EndoBridge (WEB, MicroVention, Tustin, CA, USA) device has been developed, primary for the treatment of (bifurcation) wide-necked aneurysms without the need for adjunctive devices. First clinical results of the WEB device show good safety and efficacy profiles. Most of the published series comprised wide-necked, unruptured aneurysms [6-24].

In a previous publication we presented our first results of the use of the WEB for all ruptured aneurysms suitable for the device, regardless of location or neck size [25]. Our intention was to avoid stents in the treatment of ruptured aneurysms. Our strategy was to treat ruptured wide neck aneurysms by the WEB or, when WEB placement was not possible, by coiling or surgery. In this study we present the results of this treatment strategy with an extended cohort of 100 patients with ruptured aneurysms treated with the WEB.

Materials and Methods

General

This observational study with prospectively collected data was compliant with institutional privacy policy. The Institutional Review Board gave exempt status for approval and informed consent.

The WEB device

The Woven EndoBridge system is a self-expanding, spherical or pumpkin-shaped, braided mesh of platinum cored nitinol wires that can be deployed in the aneurysm sac. The design of the WEB device has evolved from a dual-layer configuration (WEB- DL) into a single-layer version (WEB-SL) with a higher number of nitinol wires. The WEB-SL device is available in diameters ranging between 4 to 11 mm and heights ranging between 3 to 9 mm. The WEB-SLS (Single-Layer Sphere) has a spherical shape and is available in diameters ranging between 4 to 11 mm, each with a fixed height ranging between 2.6 and 9.6 mm. The WEBs with diameters 4-7 mm can be delivered through a 0.021-inch internal diameter micro catheter, the WEBs 8-9 mm through an 0.027 inch and the WEBs 10-11 mm through a 0.033-inch micro catheter (VIA 21, 27 and 33, MicroVention). Recently, a lower profile

range of WEBs compliant with a 0.017-inch micro catheter (VIA 17) has become available in clinical practice.

Placed in the aneurysm, the WEB modifies the blood flow at the level of the neck and induces aneurysmal thrombosis. The WEB can be fully retrieved until final detachment by an electrothermal detachment system contained in a hand-held controller.

General indications in this study

In our institution, treatment of patients with ruptured aneurysms is primarily endovascular within 24 hours after admission. Because of previous poor results with stent-assisted coiling in ruptured aneurysms (5), from January 2015 onwards we decided not to use stents with inherent antiplatelet medication anymore. Wide necked aneurysms were treated either with the WEB, with coiling or by surgery. Surgery was always an option in good grade patients with wide necked anterior circulation aneurysms. In poor grade patients with wide necked aneurysms not suitable for endovascular treatment, surgery was generally postponed several days.

The WEB device was initially developed for the treatment of wide-necked intracranial aneurysms as an alternative to balloon- or stent assisted treatment. After our first encouraging experiences in unruptured wide-necked aneurysms, during the study period we gradually expanded the indication to all aneurysms suitable for the WEB, regardless

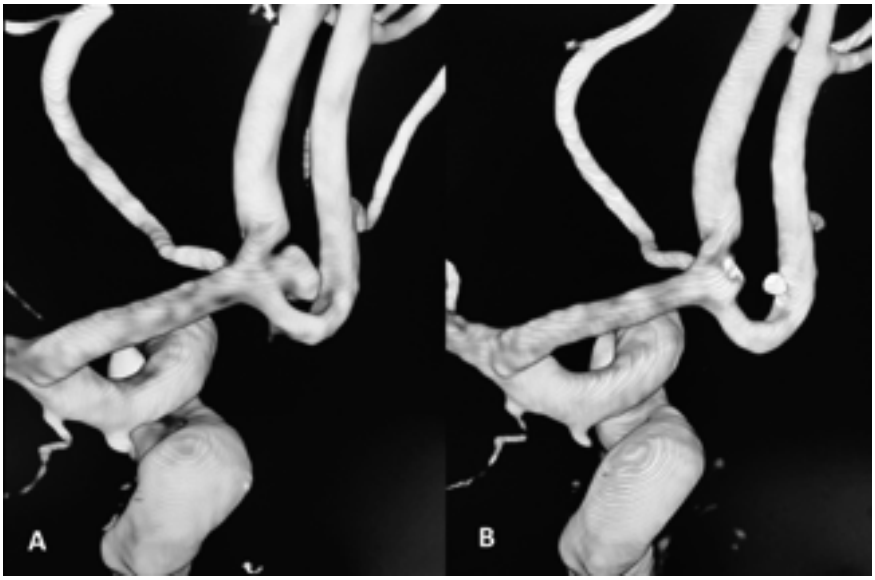

Figure 1. Ruptured anterior communicating artery aneurysm in a 52-year-old man treated with the WEB
A: 3 mm aneurysm with a relatively small neck treated with WEB SLS 4 mm.
B: 3 months' follow-up angiogram shows complete occlusion.

neck size, location or rupture status. Examples of WEB treatment of ruptured aneurysms are provided in Figures 1-3.

Under general anesthesia, a micro catheter was advanced into the aneurysm via a coaxial or triaxial approach. Hence, the aneurysm was occluded with coils or with a WEB. The WEB was slightly oversized according to recommendations of the manufacturer. WEB sizes and shapes were recorded. Apart from Heparin in the pressure bags for flushing (1000 IU/L), no anticoagulation was used.

Patient demographics and treatment- and aneurysm characteristics were collected. Clinical grading during admission was according to the Hunt and Hess scale (HH) and clinical follow-up was classified in Modified Rankin Scale (mRS). For surviving patients, angiographic follow-up was scheduled at 3 months and 3T MRA follow-up at 6 months. Quantitative variables were expressed with descriptive statistics, and categorical variables were expressed as frequencies or percentages with 95% CIs.

Figure 2. Ruptured wide necked posterior communicating artery aneurysm in a 62-year-old woman
A and B: 3D and 2D angiogram of a small wide necked aneurysm on a fetal posterior cerebral artery. Note 2 blebs on the aneurysm.
C and D: the WEB fills the aneurysm with bridging of the neck.
E and F: contrast stasis in the aneurysm after WEB placement.

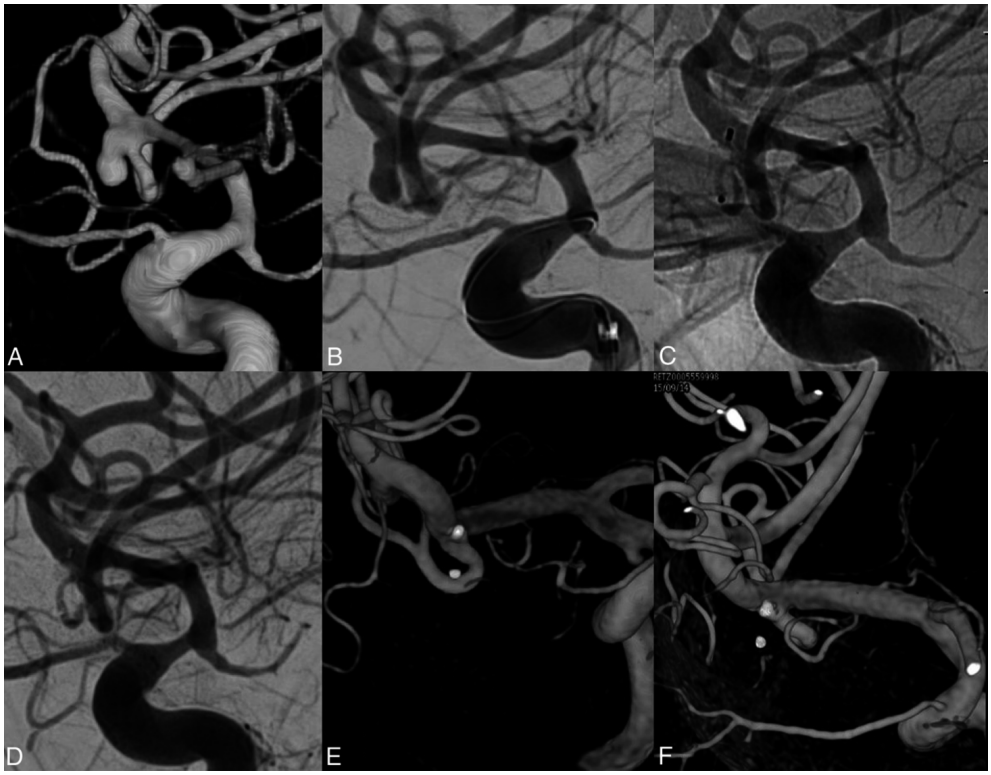

Figure 3. Small ruptured MCA aneurysm in a 58-year-old woman.
A and B: 3D and 2D angiogram shows downwards pointing small MCA aneurysm.
C and D: native and subtracted angiogram after WEB placement.
E and F: 3D angiogram at 3 months shows persistent complete occlusion.

Results

Patients

Between February 2015 and April 2017, 242 patients with a ruptured aneurysm were treated in our institution (Fig 4). Of 242 aneurysms, 189 (78%) were treated with endovascular techniques and 104 of those with the WEB device. Four patients with vertebral dissection aneurysms were treated with parent vessel occlusion using the WEB and these were excluded from further analysis. The remaining 100 patients with ruptured aneurysms selectively treated with the WEB form the subject of this study.

There were 29 men and 71 women with a mean age of 59 years (median 60, range 23-82). Clinical condition at the time of treatment was Hunt and Hess (HH) 1-2 in 53, HH 3 in 24 and HH 4-5 in 23 patients. Timing of treatment after SAH was 0-1 day in 77, 2-4 days in 16 and >4 days in 7 patients. Aneurysm location was anterior communicating artery in 46, posterior communicating artery in 22, middle cerebral artery in 16, pericallosal artery in 7, basilar tip in 5, superior cerebellar artery in 2, carotid tip in 1, and vertebral artery in 1. Mean aneurysm size was 5.6 mm (median 5, range 3-13 mm) and 42 aneurysms were ≤ 4mm. Of 100 aneurysms, 66 (66%) had a wide neck defined as ≥4 mm or dome-neck ratio ≤ 1.5. Four patients had one additional unruptured aneurysm treated in the same session, 1 with WEB and 3 with coils. One patient had 3 additional unruptured aneurysms treated with the WEB in the same session.

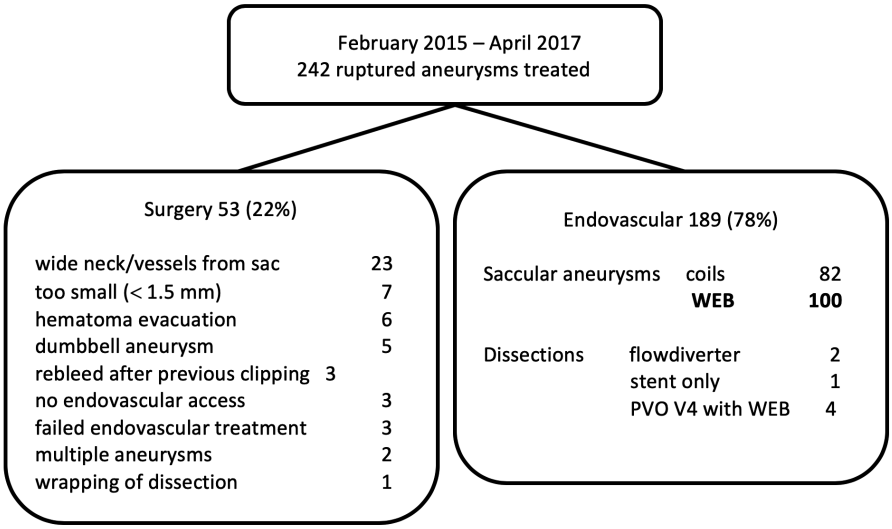

Figure 4. Flow chart of 242 ruptured aneurysms treated between February 2015 and April 2017 including main reasons to proceed to surgery.
PVO = parent vessel occlusion
V4 = vertebral artery segment 4

Initial results and complications

After WEB placement with sealing of the aneurysm neck, the position of the WEB inside the aneurysm was judged good in 98 of 100 aneurysms without filling of aneurysm remnants. In 1 patient with a 13 mm ruptured pericallosal artery aneurysm, a WEB was placed to protect the dome only. This aneurysm was later additionally clipped. In 1 patient the WEB was undersized but this was only noticed after detachment. Follow-up angiography after 1 week showed an aneurysm remnant that was then occluded with coils.

In 2 patients, coils were placed in the aneurysm dome through a jailed second micro catheter before detachment of the WEB.

WEB sizes and shapes used are displayed in Fig 5. The vast majority of WEBs used (91 of 100) were in the smaller ranges suitable for the VIA 21 micro catheter and the most frequent used size was 4 mm (43 of 100).

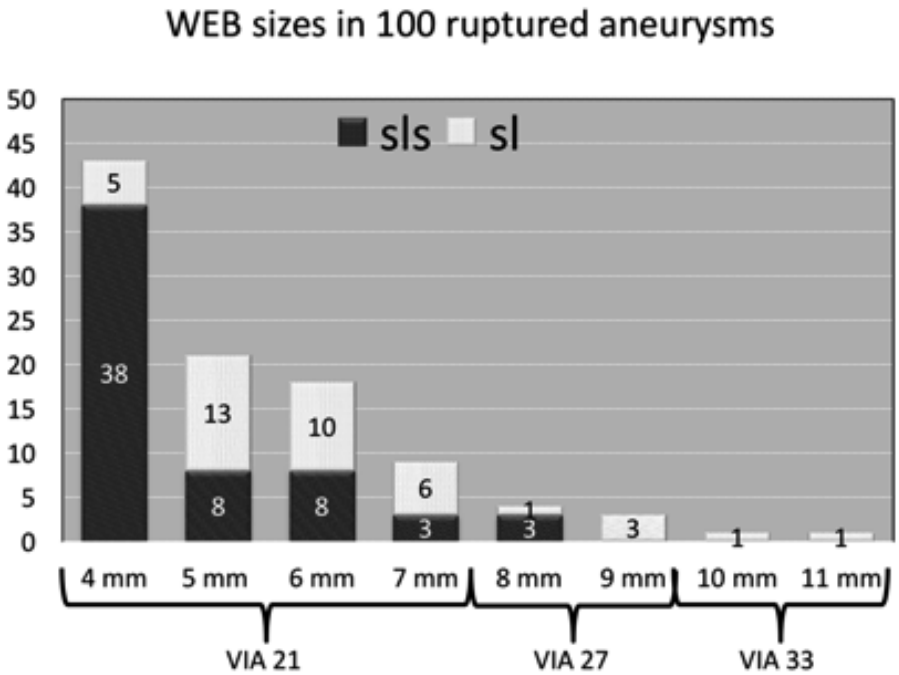

Figure 5. WEB sizes and shapes used in 100 ruptured aneurysms. VIA indicates the microcatheter used.

There was 1 procedural rupture by puncture of the dome of a posterior communicating artery aneurysm with the undeployed WEB. The bleeding stopped after WEB deployment; the patient remained unchanged in good grade. In 9 patients, thrombo-embolic complications occurred. In 7 of those 9 patients, thrombus was present before WEB placement. Five patients were treated with thrombosuction (followed by Tirofiban

in 2) and 4 with Tirofiban only. One poor grade patient with incomplete result after thrombosuction developed a partial middle cerebral artery infarction and died (mortality 1 of 100, 1%). Neurological deficits remained in 3 patients with outcomes mRS 3 in 2 and mRS 2 in 1 (morbidity 3 of 100, 3%). In 1 patient catheterization caused a dissection of the internal carotid artery, which was successfully treated with a stent. Overall treatment related permanent morbi-mortality was 4% (4 of 100, 95%CI 1.2-10.2%).

Clinical follow-up

Of 100 patients, 17 died during hospital admission on the sequelae of SAH. Of these 17 patients, 15 were admitted in poor grade (HH 4-5) and 2 in HH-3. One other poor grade patient died after a thrombo-embolic complication in a M2 branch during treatment leading to partial right frontal brain infarction. Clinical follow-up in the 82 patients who survived the hospital admission period was mRs 0-2 in 75 and mRs 3-5 in 7. There were no rebleeds from the ruptured aneurysm during follow-up.

Angiographic follow-up

Two patients had early additional treatment of the WEB treated ruptured aneurysm. Of the remaining surviving 80 patients, 74 (93%) had 3 months' angiographic follow-up. Three patients refused follow-up angiography. In 3 patients imaging follow-up is pending. Of the 74 patients with angiographic follow-up, 54 aneurysms (73%) were completely occluded, 6 of those with some proximal WEB recess filling [26-28]. Seventeen aneurysms (23%) had a small neck remnant. In 3 patients (4%) the aneurysm was incompletely occluded. In one of those 3 patients the aneurysm remnant was additionally treated with a second WEB and in 2 patients additional treatment is scheduled. Reopening/retreatment rate was 6.8% (5 of 74, 95%CI 2.6-15.2%).

Discussion

Our results show that we succeeded in our primary aim to avoid the use of stents in the treatment of acutely ruptured aneurysms by introducing the WEB. No stents were used in the endovascular treated ruptured aneurysms and in coiled ruptured aneurysms even balloon assistance was not used. One might argue that a larger proportion of wide necked aneurysms were allocated to surgery. However, less than one in ten ruptured aneurysms (23 of 242) were referred to surgery for anatomical reasons mostly because of branches coming from the aneurysm sac or aneurysms with limited height (overwide or under tall) (29). In our practice, 78% of ruptured aneurysms were treated endovascular. This proportion is higher than the 66% from a recent survey in Germany [30]. This indicates that the avoidance of the use of stents by introduction of the WEB was probably not counterweighted by increased referral to surgery.

With the use of stents in ruptured aneurysms, complication rates tend to be higher than with selective coiling because of the thrombogenicity of the devices and the need for dual antiplatelet medication with inherent risk in the postoperative period. Most operators are reluctant to use antiplatelet therapy in the setting of subarachnoid hemorrhage owing to the potential need for a ventriculostomy, the potential for infarction secondary to vasospasm, and the high likelihood of future invasive interventions. Therefore, stent placement is better avoided in acutely ruptured aneurysms in favor of endovascular techniques that do not mandate dual antiplatelet therapy or clipping.

With our patient selection for endovascular treatment with the WEB the complication rate with this device was low and the anatomical results were good. Complications consisted mainly of thrombo-embolic events. This may be related to the need for a more distal access with use of the WEB compared to coiling. With use of the WEB a distal access-guiding catheter is indispensable to achieve a stable position of the micro catheter and manipulations for distal access may promote thrombo-embolic events. Also the more frequent need of a triaxial approach with long sheets may have attributed. Of 9 patients with thrombo-embolic complications, 6 remained without clinical sequelae. In 5 patients with thrombi in MCA or PCA, thrombosuction was successful. This recent therapeutic achievement thus limited the clinical consequences of thrombo-embolic complications in our cohort. Procedural rupture with the WEB occurred only once, despite the fact that many aneurysms were small or very small. After deployment of the WEB the bleeding stopped within a minute. Rupture with the WEB can only occur at a point when the undeployed WEB begins to exit the micro catheter. Once the WEB is partially deployed inside the aneurysm, the WEB is soft and rupture can hardly occur.

An essential aspect of the WEB treatment was the sizing. Oversizing the WEB seems crucial to obtain stable results. With oversizing, the WEB anchors itself against the aneurysm wall while bridging the neck completely. Oversizing causes compression of the WEB width, which in turn results in increased height, and one has to be sure that the aneurysm can accommodate this augmented height. Oversizing protects against displacement and overturning and possibly against compression of the WEB during follow-up. In small aneurysms oversizing of about 1 mm will usually be sufficient, while in larger aneurysms 2 mm oversizing is recommended for stable securing in the neck.

Anatomical and clinical results with the WEB were good: adequate occlusion (defined as complete occlusion or neck remnant) at 3 months' angiographic follow-up was obtained in 96% (71 of 74 patients with angiographic follow-up). Only 3 aneurysms had reopened at 3 months' follow-up. Most important, during follow-up, no rebleeds occurred.

Our anatomical and clinical results in ruptured aneurysms treated with the WEB are better than in previous WEB series and also better than general results of coiling [10,22,31]. The technique of WEB treatment has improved from the first WEB series by introduction of lower profile micro-catheters and imperative oversizing. Our aneurysm population includes small-necked aneurysms and most aneurysms were small with only a few larger

than 10 mm. Since reopening over time after coiling occurs more frequently in larger aneurysms, long-term results tend to be better in a population of small aneurysms.

Limitations of this study include self-reporting of angiographic results and the limited number of patients, keeping confidence intervals rather wide. A strong point of the study is the almost complete imaging follow-up with use of angiography.

WEB treatment of ruptured intracranial aneurysms is in our opinion feasible, effective and safe. The WEB proved a valuable alternative to coils in many ruptured aneurysms regardless of location or neck size. Introduction of the WEB allowed us to refrain from the use of adjunctive stents and supporting balloons. Anticoagulation in the peri-procedural period was not necessary. This was a great advantage in view of surgical procedures that were needed in patients with acutely ruptured aneurysms.

In view of our encouraging experiences with the WEB for ruptured aneurysms, this treatment has become first choice in our practice for ruptured aneurysms in sizes between 2 and 10 mm. In larger aneurysms coiling is the first option and in exceptional cases surgery is performed.

References

1. Piotin M, Blanc R, Spelle L, et al. Stent-assisted coiling of intracranial aneurysms: clinical and angiographic results in 216 consecutive aneurysms. Stroke 2010;41:110-5
2. Bartolini B, Blanc R, Pistocchi S, et al. "Y" and "X" stent-assisted coiling of complex and wide-neck intracranial bifurcation aneurysms. AJNR Am J Neuroradiol 2014;35:2153–58
3. Chalouhi N, Jabbour P, Singhal S, et al. Stent-assisted coiling of intracranial aneurysms: predictors of complications, recanalization, and outcome in 508 cases. Stroke 2013;44:1348–53
4. Chung J, Lim YC, Suh SH, et al. Stent-assisted coil embolization of ruptured wide-necked aneurysms in the acute period: incidence of and risk factors for periprocedural complications. J Neurosurg 2014;121:4–11
5. Bechan RS, Sprengers ME, Majoie CB, et al. Stent-assisted coil embolization of intracranial aneurysms: Complications in acutely ruptured versus unruptured aneurysms. AJNR Am J Neuroradiol 2016;37:502-7
6. Lubicz B, Klisch J, Gauvrit JY et al. WEB-DL endovascular treatment of wide-neck bifurcation aneurysms: short- and midterm results in a European study. AJNR Am J Neuroradiol 2014;35:432-8
7. Colla R, Cirillo L, Princiotta C et al. Treatment of wide-neck basilar tip aneurysms using the WEB II device. Neuroradiol J 2013;6: 669-77
8. Pierot L, Moret J, Turjman F, et al. WEB treatment of intracranial aneurysms: clinical and anatomic results in the French Observatory. AJNR Am J Neuroradiol 2016;37:655-9
9. Pierot L, Spelle L, Molyneux A, et al. Clinical and anatomical follow-up in patients with aneurysms treated with the WEB device: 1-year follow-up report in the cumulated population of 2 prospective, multicenter series (WEBCAST and French Observatory). Neurosurgery 2016;78:133-41
10. L. Pierot, I. Gubucz, J.H. Buhk et al. Safety and efficacy of aneurysm treatment with the WEB: Results of the WEBCAST 2 study. AJNR Am J Neuroradiol 2017 Apr 27 [Epub ahead of print]
11. Liebig T, Kabbasch C, Strasilla C et al. Intrasaccular flow disruption in acutely ruptured aneurysms: a multicenter retrospective review of the use of the WEB. AJNR Am J Neuroradiol 2015;36:1721-7
12. Bozzetto Ambrosi P, Gory B, Sivan-Hoffmann R et al. Endovascular treatment of bifurcation intracranial aneurysms with the WEB SL/SLS: 6-month clinical and angiographic results. Interv Neuroradiol 2015;4:462-9
13. Pierot L, Costalat V, Moret J et al. Safety and efficacy of aneurysm treatment with WEB: results of the WEBCAST study. J Neurosurg 2016;124:1250-6

14. Sivan-Hoffmann R, Gory B, Riva R et al. One-year angiographic follow-up after WEB-SL endovascular treatment of wide-neck bifurcation intracranial aneurysms. AJNR Am J Neuroradiol 2015;36:2320-4
15. Leyon JJ, Chavda S, Lamin S et al. Corking the WEB and coiling through a jailed microcatheter: WEB assisted coiling, a useful technique avoiding the use of stents in treating wide-necked large intracranial aneurysms. J Neurointerv Surg 2016;8:e18
16. Gherasim DN, Gory B, Sivan-Hoffmann R et al. Endovascular treatment of wide-neck anterior communicating artery aneurysms using WEB-DL and WEB-SL: short-term results in a multicenter study. AJNR Am J Neuroradiol 2015;36:1150-4
17. Caroff J, Mihalea C, Dargento F et al. Woven endobridge (WEB) device for endovascular treatment of ruptured intracranial wide-neck aneurysms: a single-center experience. Neuroradiology 2014;56:755-61
18. Armoiry X, Turjman F, Hartmann DJ, et al. Endovascular treatment of intracranial aneurysms with the WEB Device: A systematic review of clinical outcomes. AJNR Am J Neuroradiol 2016;37:868-72
19. Fiorella, Molyneux, Coon, et al. Demographic, procedural and 30-day safety results from the WEB Intra-saccular Therapy Study (WEB-IT). J Neurointerv Surg 2017 Jan 17; Epub ahead of print
20. Muskens, Senders, Dasenbrock, et al. The Woven Endobridge Device for Treatment of Intracranial Aneurysms: A Systematic Review. World Neurosurg 2017; 98:809-817
21. Herbreteau D, Bibi R, Narata AP, et al. Are Anatomic Results Influenced by WEB Shape Modification? Analysis in a Prospective, Single-Center Series of 39 Patients with Aneurysms Treated with the WEB. AJNR Am J Neuroradiol 2016;37:2280-2286
22. Asnafi S, Rouchaud A, Pierot L, et al. Efficacy and Safety of the Woven EndoBrigde (WEB) Device for the Treatment of Intracranial Aneurysms: A Systemic Review and Meta-Analysis. AJNR Am J Neuroradiol 2016;37:2287-2292
23. Lawson A, Goddard T, Ross S, et al. Endovascular treatment of cerebral aneurysms using the Woven EndoBridge technique in a single center: preliminary results. J Neurosurg 2017;126:17-28
24. Clajus C, Strasilla C, Fiebig T, et al. Initial and mid-term results from 108 consecutive patients with cerebral aneurysms treated with the WEB device. J Neurointerv Surg 2017;9:411-417
25. van Rooij WJ, Peluso JP, Bechan RS, Sluzewski M. WEB treatment of ruptured intracranial aneurysms. AJNR Am J Neuroradiol 2016;37:1679-83
26. Caroff J, Mihalea C, Tuillier T, et al. Occlusion assessment of intracranial aneurysms treated with the WEB device. Neuroradiology 2016;58:887-91
27. Pierot L. Letter. WEB aneurysm treatment: Occlusion stability and "compression". Neurosurgery 2015;77:E666-7
28. Cognard C, Januel AC. Remnants and recurrences after the use of the WEB intrasaccular device in large-neck bifurcation aneurysms. Neurosurgery 2015;76:522-30

29. Brinjikji W, Cloft HJ, Kallmes DF. Difficult aneurysms for endovascular treatment: overwide or undertall? AJNR Am J Neuroradiol 2009;30:1513-7
30. Janssen H, Berlis A, Lutz J, Thon N, Brückmann H. State of practise: Endovascular treatment of acute aneurysmal SAH in Germany. AJNR AM J Neuroradiol June 15, 2017 [Epub ahead of print]
31. Ferns SP, Sprengers ME, van Rooij WJ et al. Coiling of intracranial aneurysms: a systematic review on initial occlusion and reopening and retreatment rates. Stroke 2009;40:e523-9

CHAPTER

6

The Woven EndoBridge (WEB) as Primary Treatment for Unruptured Intracranial Aneurysms

van Rooij SB, van Rooij WJ, Peluso JP, Sluzewski M

Interv Neuroradiol 2018;24:475-481

Purpose

The intrasaccular flowdisruptor Woven EndoBridge (WEB) device is developed for the treatment of wide-necked aneurysms without supportive devices. We used the WEB as primary treatment for unruptured aneurysms suitable for the device, regardless of neck size.

Methods

Between February 2015 and June 2017, 59 aneurysms in 51 patients (73%) were selectively treated with the WEB. There were 15 men and 36 women with a mean age of 59 years. Mean aneurysm size was 7.0 mm (range 3-22 mm). Of 59 aneurysms, 45 (76%) had a wide neck defined as ≥4 mm or dome-neck ratio ≤ 1.5. No stents or supporting balloons were used.

Results

Initial WEB position was judged good in all 59 unruptured aneurysms.

One patient with a basilar tip aneurysm had a late thrombotic posterior cerebral artery occlusion by protrusion of the WEB over the artery. There were no procedural ruptures. Overall complication rate was 2.0% (1 of 51, 95%CI 0.01-11.3%). Imaging follow-up was available in 55 of 59 aneurysms (93%). At 3 months, 41 of 57 aneurysms (72%) were completely occluded, 12 (21%) had a neck remnant and 4 (7%) were incompletely occluded.

Conclusion

WEB treatment is safe and effective in selected unruptured aneurysms suitable for the device, regardless of neck size or location. There was no need for supportive devices. Three-quarters of all unruptured small aneurysms could be treated with the WEB. In our opinion, the WEB is a valuable alternative to coils, especially in wide necked aneurysms.

Introduction

Endovascular coil treatment of wide-necked intracranial aneurysms commonly requires the use of a temporary protection balloon or a stent to avoid compromising the parent vessel. In general, this makes the procedure more complicated with inherent higher chance of procedural complications [1-4]. With use of stents, periprocedural antiplatelet therapy consisting of clopidogrel and aspirin is required and this has to be prolonged for 3-6 months.

Recently, the intrasaccular flowdisruptor Woven EndoBridge (WEB, MicroVention, Tustin, CA, USA) device has been developed for the treatment of wide-necked aneurysms without the need for supporting devices. First clinical results of the WEB device show good safety and efficacy profiles. Most of the published series comprised wide-necked, unruptured aneurysms [5-24]. The first generation of WEBs consisted of dual layer devices (WEB-DL) with high profile needing 0.027- or 0.033-inch micro catheters. The next generation came with single layer design (WEB-SL) and lower profile, suitable for a 0.021-inch micro catheter (WEB 21). The latest generation WEBs is suitable for a 0.017-inch micro catheter (WEB 17) and was introduced in clinical practice in December 2016 [25].

In February 2015, just after introduction of the WEB 21 system, we started to use WEBs for wide necked unruptured intracranial aneurysms with the intention to avoid the use of stents. Our first results in wide necked aneurysms were encouraging and we decided to expand the indication to all aneurysms suitable for the WEB, regardless of neck size, rupture status or location [16]. We hypothesized that the WEB can occlude selected unruptured aneurysms at a low complication rate.

In this study we present the results of the first 59 unruptured aneurysms treated with the WEB in our institution.

Materials and Methods

General

This is a retrospective observational study without defined inclusion and exclusion criteria. Endpoints are occlusion status at 3 months imaging follow-up and procedural complications leading to morbidity or mortality.
The study was performed in the St. Elisabeth Ziekenhuis in Tilburg.

The WEB device

The Woven EndoBridge system (WEB, MicroVention) is a self-expanding, spherical (SLS) or pumpkin-shaped (SL), braided mesh of platinum cored nitinol wires that can be delivered through a micro catheter and deployed in the aneurysm sac. The WEBs with diameters 4-7 mm can be delivered through a 0.021-inch internal micro catheter, the WEBs 8-9 mm through an 0.027-inch and the WEBs 10-11 mm through a 0.033-inch micro catheter

(VIA 21, 27 and 33, MicroVention). Recently, a lower profile range of WEBs compliant with a 0.017-inch micro catheter (VIA 17) has become available in clinical practice. These comprise smaller and shallower sizes including some half mm sizes.

Placed in the aneurysm, the WEB alters the blood flow at the level of the neck and induces aneurysmal thrombosis. The WEB is attached to a pusher wire and can be fully retrieved until final detachment by an electrothermal detachment system contained in a hand-held controller.

General indications in this study

Patients with unruptured aneurysms are discussed in a weekly joint meeting with neurosurgeons, neurologists and neuroradiologists. When treatment is indicated, the primary modality is endovascular selective treatment or parent vessel occlusion. When stents or flowdiverters are foreseen, the patient is preloaded with dual anti-aggregation therapy. Surgery is considered in patients with aneurysms with unfavorable anatomy for endovascular treatment such as aneurysms with vessels coming from the sac and shallow wide necked aneurysms, defined as aneurysms with height/width ratio of ≤0.5 (overwide or undertall). In aneurysms 10 mm or smaller, the WEB was the primary treatment modality. Although the maximum size of the WEB is 11 mm, the WEB may be used in larger aneurysms. This can be due to aneurysm shape (tall aneurysms) where the WEB may be used to occlude the neck only and the fundus may or may not be filled with coils. Partially thrombosed aneurysms can also be larger but with a small lumen that can be occluded with the WEB.

In aneurysms too large for the WEB, coiling was the treatment of choice.

Under general anesthesia, a micro catheter was advanced into the aneurysm via a coaxial or triaxial approach. Hence, the WEB was placed inside the aneurysm. The WEB was slightly oversized according to recommendations of the manufacturer. WEB sizes and shapes were recorded. Apart from Heparin in the pressure bags for flushing (1000 IU/L), in the beginning of the procedure a bolus of 2,500 -5,000 IU Heparin was administered. Post procedural anticoagulation was not routinely administered, only in exceptional cases low dose aspirin was prescribed during 3 months.

Patient demographics and treatment- and aneurysm characteristics were collected. Modified Rankin Scale (mRS) at 3 months was assessed by the multidisciplinary treatment group. Angiographic follow-up was scheduled at 3 months and 3T MRI/MRA follow-up at 6 and 18 months. MRA follow-up was performed on a 3.0-Tesla system (Philips Intera R10, Philips Medical Systems, Best, The Netherlands) using the sensivity encoding (SENSE) phased array head coil (MRI Devices, Gainesville, Florida, USA) according to a previously validated protocol [26].

Quantitative variables were expressed with descriptive statistics, and categorical variables were expressed as frequencies or percentages with 95% CIs.

Results

Patient-and aneurysm characteristics are summarized in online Table 1

Patients

Between February 2015 and June 2017, 292 aneurysms were treated with endovascular techniques at our institution. Of these, 204 (70%) were ruptured and 88 (30%) were unruptured. Of 88 unruptured aneurysms, 57 were an incidental finding, 16 were symptomatic by mass effect and 15 were additional to another ruptured aneurysm.

Of 88 unruptured aneurysms, 22 were selectively coiled (25%) and 66 (75%) were treated with the WEB, of which 7 with parent vessel occlusion of ICA or vertebral artery [27].

The 22 aneurysms that were selectively coiled consisted of 12 aneurysms considered too small for the WEB (1.5-4mm) and 10 aneurysms too large with anatomy unsuitable for coiling and neck occlusion with the WEB.

Fifty-nine unruptured aneurysms in 51 patients were selectively treated with the WEB device and these patients form the subject of this study. Five patients had 2 aneurysms and 1 patient had 4 aneurysms treated with the WEB. Two patients with posterior communicating artery aneurysms presented with mass effect on the third cranial nerve. There were 15 men and 36 women with a mean age of 59 years (median 61, range 30-76).

Aneurysm location was middle cerebral artery in 17, anterior communicating artery in 10, basilar tip in 8, posterior communicating artery in 7, pericallosal artery in 5, carotid tip in 5, PICA in 2, superior cerebellar artery in 2 and ophthalmic artery, cavernous sinus and extra cranial internal carotid artery each in 1. Mean aneurysm size was 7.0 mm (median 6, range 3-22 mm). Ten aneurysms were large (≥ 10 mm). One large aneurysm was partially thrombosed (fig.1) and 8 were taller than wide. In larger aneurysms, the WEB was placed in the base/neck of the aneurysm and in 4 aneurysms additional coils were placed in the fundus. Six unruptured aneurysms were treated in the same session in patients with a ruptured aneurysm. Of 59 aneurysms, 45 (76%) had a wide neck defined as ≥4 mm or dome-neck ratio ≤ 1.5 (figs 2 and 3). No stents or supporting balloons were used.

Initial results and complications

After WEB placement with sealing of the aneurysm neck, the position of the WEB inside the aneurysm was judged good in all 59 unruptured aneurysms.
The WEB sizes 4 and 7 mm were the most frequently used.

In 1 patient, an ischemic adverse event occurred; a 70-year-old woman with a 10-mm basilar tip aneurysm had a thrombotic posterior cerebral artery occlusion as a result of protrusion of the WEB over the origin of the artery. Her outcome after 3 months was mRs 4. There were no procedural ruptures. Overall complication (morbidity) rate was 2.0% (1 of 51, 95%CI 0.01-11.3%).

Clinical and imaging follow-up

In 6 patients, the WEB treated unruptured aneurysm was additional to a ruptured aneurysm and was treated in the same session. One of these patients died on the sequelae of SAH. The other 5 patients had mRs 2 in 3 and mRs 1 in 2 at 3 months follow-up, all five as a result of SAH.

At 3 months, the one patient with a procedural complication had mRs 4, the remaining 44 patients were clinically intact with mRs 0. The two patients who presented with mass effect on the oculomotor nerve were cured.

Of 50 eligible patients, 47 with 55 aneurysms had 3 months' angiographic follow-up. Two patients had MRA follow-up only at 3 months. The one patient with a complication refused follow-up imaging. Overall, imaging follow-up was available in 55 of 59 aneurysms (93%).

At 3 months imaging follow-up, 41 of 57 aneurysms (72%) were completely occluded, 12 (21%) had a neck remnant and 4 (7%) were incompletely occluded. One incompletely occluded aneurysm was a trilobar 6 mm AcomA aneurysm (patient #9). One lobe was not thrombosed on follow-up and was additionally coiled. The second incompletely occluded aneurysm was an 11-mm wide necked V4 aneurysm in a 73-year-old woman (patient #7) and this aneurysm is being followed with imaging. The third incompletely occluded aneurysm was a 10 mm PcomA aneurysm in a 51-year old patient (patient #57) with compression of the WEB and was additionally treated with a second WEB. The fourth patient was a 65-year old woman (patient #19) with a 8mm carotid tip aneurysm and a bleb on the base. At follow-up the bleb was not occluded and was additionally coiled.

Extended MRA follow-up was available in 45 patients with 52 aneurysms. In one patient with additionally clipped aneurysms, artifacts disturbed MRA. MRA follow-up ranged from 6-24 months (mean 11.6 months). Extended MRA follow-up showed no changes in 51 aneurysms.

Overall reopening/retreatment rate was 7.0% (4 of 57, 95%CI 2.3-17.2%).

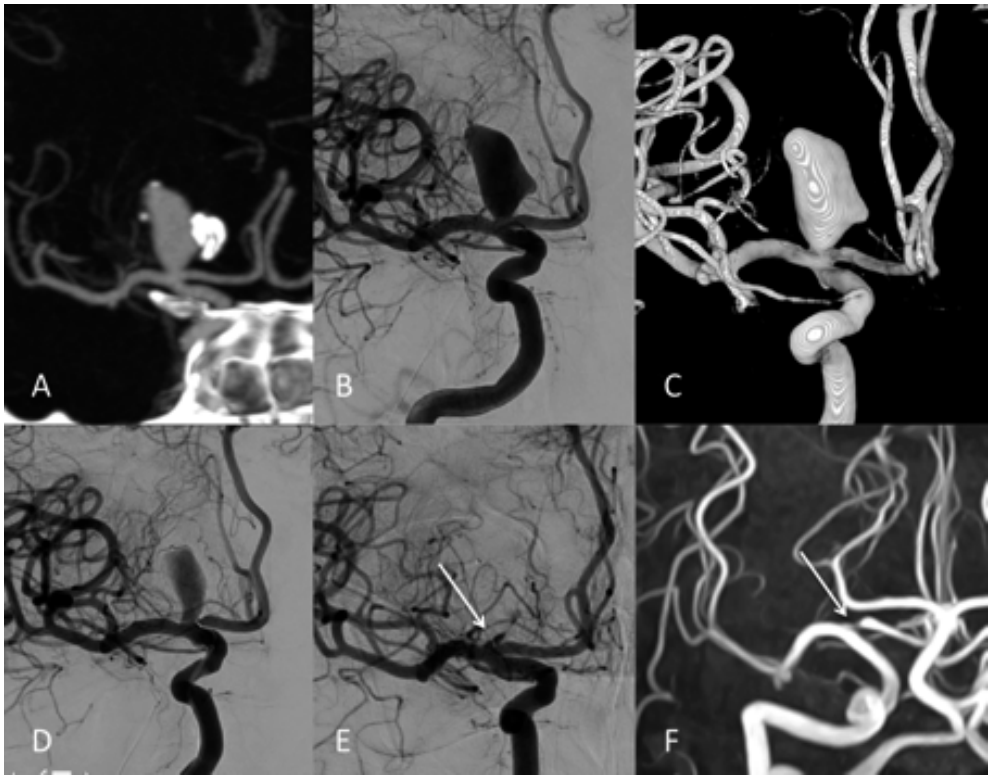

Figure 1. 63-year-old man with an incidentally discovered carotid tip aneurysm treated with the WEB.
A-C: Coronal CT angiogram (A) and AP carotid angiogram (B) with 3D (C) shows large, partially thrombosed and calcified carotid tip aneurysm with a small neck.
D: Immediately after WEB placement reduced filling of the aneurysm.
E: 3 months' follow up angiogram shows almost complete occlusion with slide filling at the base of the WEB (arrow).
F: MRA at 6months. Note signal loss in A1 by WEB-marker (arrow). Since the WEB behaves as a cage of Faraday possible persistent inflow in the WEB may not be visible.

Figure 2. 52-year-old man with incidental anterior communicating artery aneurysm treated with the WEB.
A: Oblique right internal carotid angiogram shows small AcomA aneurysm with wide neck.
B: Immediately after WEB placement reduced aneurysm filling.
C: 3 months' follow up angiogram shows complete occlusion.
D: MRA at 18 months with persistent complete occlusion.

Figure 3. 64-year-old man with incidental AcomA aneurysm.
A: 3D carotid angiogram shows small AcomA aneurysm with very wide neck.
B: WEB placement with complete covering of the aneurysm neck.
C and D: 3 months' follow up angiogram (C) with 3D (D) demonstrates complete occlusion.

Discussion

Our first results using the WEB as primary treatment for unruptured aneurysms are in line with other studies using WEB or coils [5,9,12-14,16-18,21-24]. In a meta-analysis by Asnafi et al [13], 15 uncontrolled series were included totaling 565 patients with 588 aneurysms treated with the WEB, of which 127 were ruptured. Initial complete and adequate occlusion rates were 27% and 59%, respectively. Midterm complete and adequate occlusion rates after a median of 7 months were 39% and 85%, respectively. Perioperative morbidity and mortality rates were 4% and 1%, respectively. Midterm adequate occlusion rates for ruptured aneurysms were 85%, compared with 84% for unruptured aneurysms. Both patients with ruptured aneurysms and patients with unruptured aneurysms had perioperative morbidity of 2%. Our results of 93% adequate occlusion at 3 months are in the same range as in this meta-analysis.

In our limited patient cohort confidence intervals are wide and more patients are needed to confirm or refute our encouraging results concerning procedural complications and occlusion rates over time. In the study period, three-quarters of all endovascular treated unruptured aneurysms were treated with the WEB, either selectively or with parent vessel occlusion [25]. Only very small aneurysms (1.5-4 mm) or large aneurysms with anatomy unsuitable for coiling and neck occlusion with the WEB were primarily treated with coiling. Also shallow aneurysms with height/width ratio ≤0.5 were treated otherwise. Most of the treated aneurysms (76%) had a wide neck and with use of the WEB, no additional stents or balloons were needed. This was a great advantage. The anticoagulation protocol with WEB treatment was limited to periprocedural heparinization and thrombo-embolic complications did not occur.

Wide necked aneurysms are among the most challenging aneurysms encountered for endovascular treatment. Their treatment commonly requires either craniotomy for clipping of the aneurysm or the use of implanted adjunctive devices. Such complex treatment strategies are technically demanding, time intensive, require multiple catheter manipulations, and are likely to be associated with higher complication rates.

Intrasaccular flow disruption theoretically addresses the shortcomings of established endovascular methods for the treatment of wide necked aneurysms. The WEB allows for a single-step treatment in a procedure that is technically more similar to straightforward coil embolization than stent-assisted coiling or balloon remodeling. Once the micro catheter is placed inside the aneurysm, the deployment of the WEB is a matter of minutes. The position of the WEB can be checked with angiography and additional 3D rotational angiography when needed. Once implanted, the WEB provides a metal surface area coverage at the aneurysm neck ranging from 55% to 100%, increasing centripetally. This high metal coverage provides substantial flow disruption and forms a physical matrix for neo-intimal growth. These physical characteristics theoretically may have a favorable effect on occlusion rates and durability at follow-up. A drawback of WEB treatment is

that initial occlusion cannot always be assessed since in most aneurysms there is still slow inflow of contrast material when the procedure is terminated. With 10-20 minutes pause, virtually all aneurysms will be occluded when the WEB has been placed correctly. In our practice, we end the procedure after accurate WEB placement and subsequent detachment.

The vast majority of unruptured aneurysms treated with the WEB in our cohort were adequately occluded at short- or midterm follow-up. Only 4 aneurysms were incompletely occluded: 3 aneurysms had a very unfavorable anatomy and in one large aneurysm there was compression of the WEB [10, 28-29].

Although the use of the WEB has some technical issues, these can readily be learned by anyone with some experience with endovascular aneurysm treatment. The procedure is more or less similar to simple coiling. Proper training on phantoms and proctoring of the first few cases can largely avoid a learning curve. We recommend first-time users to start with the simplest aneurysms with a small neck and not with wide necked aneurysms. With growing confidence, more challenging aneurysms can be treated, sometimes surprisingly easy.

A limitation of our single center study is the limited number of patients keeping confidence intervals wide. We established occlusion status of the aneurysms ourselves, not a core lab. Strong points of the study are the multidisciplinary treatment with neurosurgeons and neurologists, the complete clinical and almost complete imaging follow-up.

Conclusions

Our results indicate that WEB treatment is safe and effective in unruptured small aneurysms, regardless of neck size or location. There was no need for adjunctive devices and the anticoagulation protocol was simple and effective using Heparin only. Three-quarters of all unruptured aneurysms could be treated with the WEB. In our opinion, the WEB is a valuable alternative to coils, especially in wide necked aneurysms.

References

1. Piotin M, Blanc R, Spelle L, et al. Stent-assisted coiling of intracranial aneurysms: clinical and angiographic results in 216 consecutive aneurysms. Stroke 210;41:110-5
2. Bartolini B, Blanc R, Pistocchi S, et al. "Y" and "X" stent-assisted coiling of complex and wide-neck intracranial bifurcation aneurysms. AJNR Am J Neuroradiol 2014;35:2153–58
3. Chalouhi N, Jabbour P, Singhal S, et al. Stent-assisted coiling of intracranial aneurysms: predictors of complications, recanalization, and outcome in 508 cases. Stroke 2013;44:1348–53
4. Chung J, Lim YC, Suh SH, et al. Stent-assisted coil embolization of ruptured wide-necked aneurysms in the acute period: incidence of and risk factors for periprocedural complications. J Neurosurg 2014;121:4–11
5. Armoiry X, Turjman F, Hartmann DJ, et al. Endovascular treatment of intracranial aneurysms with the WEB Device: A systematic review of clinical outcomes. AJNR Am J Neuroradiol 2016; 37:868-72
6. Sivan-Hoffmann R, Gory B, Riva R et al. One-year angiographic follow-up after WEB-SL endovascular treatment of wide-neck bifurcation intracranial aneurysms. AJNR Am J Neuroradiol 2015;36:2320-4
7. Lawson A, Goddard T, Ross S, et al. Endovascular treatment of cerebral aneurysms using the Woven EndoBridge technique in a single center: preliminary results. J Neurosurg 2017;126:17-28
8. Leyon JJ, Chavda S, Lamin S et al. Corking the WEB and coiling through a jailed microcatheter: WEB assisted coiling, a useful technique avoiding the use of stents in treating wide-necked large intracranial aneurysms. J Neurointerv Surg 2016;8:e18
9. Lawson A, Molyneux A, Sellar R et al. Safety results from the treatment of 109 cerebral aneurysms using the Woven EndoBridge technique: preliminary results in the United Kingdom. J Neurosurg 2018;128:144-53
10. Caroff J, Mihalea C, Tuillier T, et al. Occlusion assessment of intracranial aneurysms treated with the WEB device. Neuroradiology 2016;58:887-91
11. Gherasim DN, Gory B, Sivan-Hoffmann R et al. Endovascular treatment of wide-neck anterior communicating artery aneurysms using WEB-DL and WEB-SL: short-term results in a multicenter study. AJNR Am J Neuroradiol 2015;36:1150-4
12. Fiorella D, Molyneux A, Coon A et al. Demographic, procedural and 30-day safety results from the WEB Intra-saccular Therapy Study (WEB-IT). J Neurointerv Surg 2017;9:1191-96.
13. Asnafi S, Rouchaud A, Pierot L, et al. Efficacy and Safety of the Woven EndoBrigde (WEB) Device for the Treatment of Intracranial Aneurysms: A Systemic Review and Meta-Analysis. AJNR Am J Neuroradiol 2016;37:2287-2292
14. Pierot L, Moret J, Turjman F, et al. WEB treatment of intracranial aneurysms: clinical and anatomic results in the French Observatory. AJNR Am J Neuroradiol 2016;37:655-9

15. van Rooij WJ, Peluso JP, Bechan RS, Sluzewski M. WEB treatment of ruptured intracranial aneurysms. AJNR Am J Neuroradiol 2016;37:1679-83
16. van Rooij SB, van Rooij WJ, Peluso JP, Sluzewski M, et al. WEB treatment of ruptured intracranial aneurysms: A single center cohort of 100 patients. AJNR Am J Neuroradiol 2017;38:2282-87
17. Pierot L, Spelle L, Molyneux A, et al. Clinical and anatomical follow-up in patients with aneurysms treated with the WEB device: 1-year follow-up report in the cumulated population of 2 prospective, multicenter series (WEBCAST and French Observatory). Neurosurgery 2016;78:133-41
18. Pierot L, Costalat V, Moret J et al. Safety and efficacy of aneurysm treatment with WEB: results of the WEBCAST study. J Neurosurg 2016;124:1250-6
19. Clajus C, Strasilla C, Fiebig T, et al. Initial and mid-term results from 108 consecutive patients with cerebral aneurysms treated with the WEB device. J Neurointerv Surg 2017;9:411-417
20. Pierot L, Gubucz I, Buhk JH et al. Safety and efficacy of aneurysm treatment with the WEB: Results of the WEBCAST 2 study. AJNR Am J Neuroradiol 2017;38:1151-55
21. Lubicz B, Klisch J, Gauvrit JY et al. WEB-DL endovascular treatment of wide-neck bifurcation aneurysms: short- and midterm results in a European study. AJNR Am J Neuroradiol 2014;35:432-8
22. Liebig T, Kabbasch C, Strasilla C et al. Intrasaccular flow disruption in acutely ruptured aneurysms: a multicenter retrospective review of the use of the WEB. AJNR Am J Neuroradiol 2015;36:1721-7
23. Popielski J, Berlis A, Weber W, et al. Two-center experience in the endovascular treatment of ruptured and unruptured aneurysms using the WEB device: a retrospective analysis. AJNR Am J Neuroradiol 2018;39:111-117
24. Ferns SP, Sprengers ME, van Rooij WJ, et al. Coiling of intracranial aneurysms: a systematic review on initial occlusion and reopening and retreatment rates. Stroke 2009;40:e523-9
25. van Rooij SB, Peluso JP, Sluzewski M, Kortman HG, van Rooij WJ. The new low-profile WEB 17 system for treatment of intracranial aneurysms: first clinical experiences. AJNR Am J Neuroradiol 2018 Mar 22 doi: 10.3174/ajnr.A5608. [Epub ahead of print]
26. Majoie CB, Sprengers ME, van Rooij WJ, et al. MR angiography at 3T versus digital subtraction angiography in the follow-up of intracranial aneurysms treated with detachable coils. AJNR Am J Neuroradiol 2005;26:1349-56
27. van Rooij WJ, Sluzewski M, Bechan R, Peluso JP. Therapeutic internal carotid or vertebral artery occlusion using the WEB device. Interv Neuroradiol 2016;22:365-7
28. Pierot L. Letter. WEB aneurysm treatment: Occlusion stability and "compression". Neurosurgery 2015;77:E666-7
29. Cognard C, Januel AC. Remnants and recurrences after the use of the WEB intrasaccular device in large-neck bifurcation aneurysms. Neurosurgery 2015;76:522-30

patient #	age	Gender	Location	Indication	Wide neck	Size wxwxh	Max. size	WEB size *	WEB shape	Coils	Complications	Angio FU months	Result	mRS	Additional treatment	MRA FU months
1	66	M	Anterior communicating artery	incidental	yes	6x5x5	6	w2-6-3	sl	x	x	4	Complete occlusion	0	x	24
2	62	F	Basilar tip	incidental	yes	7x8x10	10	w2-9-5	sl	x	x	3	Neck remnant	0	x	18
3	56	F	Basilar tip	incidental	yes	6x7x20	20	w2-8-6	sl	yes	x	3	Neck remnant	0	x	9
3	48	F	Basilar tip	incidental	yes	7x5x5	7	w2-7-3	sl	x	x	3	Complete occlusion	0	x	12
5	51	F	Basilar tip	incidental	yes	5x7x5	7	w4-7-3	sl	x	x	4	Complete occlusion	0	x	24
6	62	F	Middle cerebral artery	incidental	yes	6x7x6	7	w2-8-4	sl	x	x	3	Complete occlusion	0	x	6
7	73	F	Vertebral artery	incidental	yes	9x10x9	10	w2-11-7	sl	x	x	4	Aneurysm remnant	0	no	12
8	41	M	Basilar tip	incidental	yes	3x4x4	4	w4-4-3	sl	x	x	3	Complete occlusion	0	x	6
9	55	F	Anterior communicating artery	incidental	no	5x11x7	11	w4-7-4	sl	x	x	3	Aneurysm remnant	0	coiling	18
10	66	M	Middle cerebral artery	incidental	yes	6x6x7	7	w4-7-5	sl	x	x	3	Neck remnant	0	x	24
11	59	F	Posterior communicating artery	incdental	yes	6x6x5	6	w4-7-3	sl	x	x	3	Complete occlusion	0	x	clipartefacts
12	60	F	Anterior communicating artery	incidental	yes	5x5x5	5	w4-6-3	sl	x	x	3	Complete occlusion	0	x	24
	60	F	Pericallosal artery	incidental	yes	4x5x5	5	w4-5-3	sl	x	x	3	Complete occlusion	0	x	24
13	57	F	Basilar tip	incidental	yes	8x10x15	15	w4-5-4	sl	yes	x	3	Complete occlusion	0	x	6
14	61	F	Posterior communicating artery	incidental	yes	16x18x22	22	w2-11-9	sl	yes	x	3	Neck remnant	0	x	6
15	30	M	Middle cerebral artery	incidental	yes	7x8x6	8	w2-9-4	sl	x	x	4	Complete occlusion	0	x	12
16	64	F	Carotid tip	incidental	no	4x5x6	6	w4-6-s	sls	x	x	3	Complete occlusion	0	x	24
17	63	M	Anterior communicating Artery	incidental	yes	4x5x6	6	w4-6-3	sl	x	x	3	Complete occlusion	0	x	18
18	65	F	Carotid tip	incidental	no	5x5x8	8	w4-6-4	sl	x	x	3	Aneurysm remnant	0	coiling	18
19	54	F	Cavernous internal carotid artery	additional at SAH	no	3x3x4	4	w4-4-s	sls	x	x	5	Complete occlusion	2	x	18
20	76	M	Superior cerbellar artery	additional at SAH	no	3x3x5	5	w4-4-s	sls	x	x	3	Complete occlusion	2	x	18
21	62	M	Carotid tip	incidental	no	10x10x16	16	w2-11-s	sls	x	x	3	Complete occlusion	0	x	18
22	64	F	Middle cerebral artery	incidental	no	3x4x6	6	w4-5-s	sls	x	x	3	Complete occlusion	0	x	18
23	72	F	Carotid tip	incidental	yes	4x5x5	5	w4-6-3	sl	x	x	3	Complete occlusion	0	x	18
24	60	M	Anterior communicating artery	incidental	yes	5x5x5	5	w4-7-3	sl	x	x	3	Complete occlusion	0	x	9
25	69	M	Anterior communicating artery	incidental	yes	9x5x5	9	w2-8-3	sl	x	x	3	Complete occlusion	0	x	18
26	46	M	Middle cerebral artery	incidental	no	3x3x4	4	w5-4-s	sls	x	x	3	Complete occlusion	0	x	6
			Pericallosal artery	incidental	no	3x3x6	6	w4-4-5	sls	x	x	3	Complete occlusion	0	x	12
27	48	F	Internal carotid artery	incidental	yes	6x7x7	7	w2-9-s	sls	x	x	3	Complete occlusion	0	x	6
28	60	F	Anterior communicating artery	incidental	yes	5x8x5	8	w4-7-3	sl	x	x	3	Complete occlusion	0	x	18
29	55	M	Basilar tip	incidental	yes	7x8x6	8	w2-9-4	sl	x	x	3	Neck remnant	0	x	6
30	55	F	Posterior communicating artery	incidental	yes	4x3x7	7	w4-5-s	sls	x	x	3	Complete occlusion	0	x	9
31	70	F	Basilar tip	incidental	yes	9x9x11	11	w2-11-5	sl	x	occlusion PCA	no	Complete occlusion	4	x	no
32	73	M	Middle cerebral artery	incidental	yes	7x8x6	8	w2-9-4	sl	x	x	3	Neck remnant	0	x	6
33	46	F	Posterior communicating artery	symptomatic	yes	6x6x6	6	w4-7-s	sls	x	x	3	Complete occlusion	0	x	9
34	74	F	Posterior communicating artery	incidental	yes	5x6x9	9	w2-8-s	sls	x	x	3	Complete occlusion	0	x	12
35	70	F	Middle cerebral artery	incidental	yes	3x4x6	6	w4-5-s	sls	x	x	3	Neck remnant	0	x	no
			Ophtalmic carotid artery	incidental	yes	3x3x5	5	w4-4-s	sls	x	x	3	Complete occlusion	0	x	no
36	54	F	Middle cerebral artery	incidental	no	3x3x5	5	w4-4-s	sls	x	x	3	Complete occlusion	0	x	6
37	64	F	Anterior communicating artery	incidental	yes	10x8x13	13	w4-7-s	sls	yes	x	no	Neck remnant	0	x	3
38	65	F	Middle cerebral artery	incidental	yes	5x6x7	7	w5-7-3	sl	x	x	3	Complete occlusion	0	x	9
			Pericallosal artery	incidental	no	2x2x3	3	w5-3-2	sl	x	x	3	Complete occlusion	0	x	9
			Pericallosal artery	incidental	no	2x2x3	3	w5-3-2	sl	x	x	3	Complete occlusion	0	x	9
			Middle cerebral artery	incidental	yes	2x2x3	3	w5-3-2	sl	x	x	3	Complete occlusion	0	x	9
39	61	M	Anterior communicating artery	incidental	yes	4x5x5	5	w4-6-3	sl	x	x	3	Complete occlusion	0	x	6
40	65	F	Middle cerebral artery	incidental	no	3x4x4	4	w5-4.5-3	sl	x	x	3	Neck remnant	0	x	6
41	70	F	Middle cerebral artery	incidental	yes	6x6x6	6	w5-7-4	sl	x	x	3	Neck remnant	0	x	6
42	49	F	Middle cerebral artery	additional at SAH	yes	3x2x4	4	w5-4-s	sls	x	x	no	Complete occlusion	6	x	no
43	51	F	Posterior inferior cerebellar artery	incidental	yes	3x4x4	4	w4-5-3	sl	x	x	3	Neck remnant	0	x	6
44	63	M	Anterior communicating artery	incidental	yes	5x5x4	5	w4-6-3	sl	x	x	3	Complete occlusion	0	x	6
45	62	M	Middle cerebral artery	incidental	yes	6x5x8	8	w4-7-4	sl	x	x	3	Complete occlusion	0	x	6
46	53	F	Middle cerebral artery	incidental	yes	3x3x4	4	w5-4-2	sl	x	x	3	Complete occlusion	0	x	6
47	57	F	Middle cerebral artery	additional at SAH	yes	3x2x3	3	w5-4-2	sl	x	x	3	Complete occlusion	1	x	6
			Posterior communicating artery	additional at SAH	yes	3x3x4	4	w5-4.5-2	sl	x	x	3	Neck remnant	1	x	6
48	54	F	Pericallosal artery	incidental	no	2x3x4	4	w5-4-s	sl	x	x	3	Complete occlusion	0	x	6
			Middle cerebral artery	incidental	yes	3x3x4	4	w5-4-s	sl	x	x	3	Complete occlusion	0	x	6
49	51	F	Posterior communicating artery	symptomatic	yes	7x7x10	10	w4-10-s	sls	x	x	3	Aneurysm remnant	0	2nd WEB	no
50	65	F	Carotid tip	incidental	yes	4x4x6	6	w5-6-s	sls	x	x	3	Complete occlusion	0	x	no
51	61	F	Superior cerbellar artery	additional at SAH	yes	4x3x4	4	w5-5-3	sl	x	x	no	Complete occlusion	2	x	6

Tabel 1

Characteristics of 51 patients with 59 unruptured aneurysms treated with the WEB.

***** The first number indicates WEB generation; 2 for Single Layer, 4 for 21 system and 5 for 17 system.
Second 2 numbers indicate size in mm in SL shape. Second number followed by "s" indicates size in mm and SLS shape.
PCA = Posterior Cerebral Artery

CHAPTER

7

The new low-profile WEB 17 system for treatment of intracranial aneurysms: first clinical experiences

van Rooij SB, Peluso JP, Sluzewski M, Kortman HG, van Rooij WJ

AJNR Am J Neuroradiol 2018;39:859-863

Introduction

The Woven EndoBridge (WEB) is an intrasaccular flowdiverter intended to treat widen necked aneurysms. The latest generation WEBs needed a 0.021-inch microcatheter in the small sizes. Recently, a lower-profile range of WEBs compliant with a 0.017-inch microcatheter (WEB 17) was introduced. We present the first clinical results of treatment of both ruptured and unruptured aneurysms with the WEB 17.

Materials and Methods

Between December 2016 and September 2017, 46 aneurysms in 40 patients were treated with the WEB 17. No supporting stents or balloons were used. Twenty-five aneurysms were ruptured (54%). There were 6 men and 34 women, mean age 62 years (median 63, range 46-87). Mean aneurysm size was 4.9 mm (median 5, range 2-7 mm).

Results

There were 2 thrombo-embolic procedural complications without clinical sequelae and no ruptures. Overall permanent procedural complication rate was 0% (0 of 40, 97.5%CI 0-10.4%).

Imaging follow-up at 3 months was available in 33 patients with 39 aneurysms (97.5% of eligible aneurysms). In one aneurysm the detached WEB was undersized and the remnant was additionally treated with coils after 1 week. This same aneurysm reopened at 3 months and was again treated with a second WEB. One other aneurysm showed persistent WEB filling at 3 months. Complete occlusion was achieved in 28 aneurysms (72%) and 9 aneurysms (23%) showed a neck-remnant.

Conclusion

WEB 17 is safe and effective for both ruptured and unruptured aneurysms. The WEB 17 is a valuable addition to the existing WEB size range, especially for very small aneurysms.

Introduction

Recently, the self-expanding intra-aneurysmal flowdisruptor Woven EndoBridge (WEB, Microvention, Tustin, CA, USA) device has been developed primarily for the treatment of wide-necked aneurysms without the need for supporting devices and without the need for concomitant dual antiplatelet therapy.

First clinical results of the WEB device show good safety and efficacy profiles. Most of the published series comprised wide-necked, unruptured aneurysms [1-8, 10-15]. The first generation WEBs required 0.027-0.033-inch microcatheters for delivery. In 2015 the WEB was redesigned for a 0.021-inch delivery microcatheter (WEB 21) in the sizes 4-7 mm.

A new generation low profile WEBs was introduced in clinical practice in December 2016. This system is compatible with a 0.017-inch microcatheter (WEB 17). To achieve this lower profile, fewer wires were used to construct the device. In benchmark studies the flow diverting effect seemed equal to that of the WEB 21 system (MicroVention, unpublished data). The WEB 17 is intended for small aneurysms and comes in sizes 3-7 mm.

In this study, we present the first clinical results of 46 ruptured and unruptured small aneurysms treated with the new WEB 17 system.

Materials and Methods

The WEB device

The WEB device is a self-expanding oblong or spherical shaped braid of platinum-cored nitinol wires intended to implant inside the aneurysmal sac. The device is electro thermally detachable and is introduced through a micro catheter. In 2010 the device was introduced as the WEB Dual-Layer (DL), with a second nitinol mesh placed at the bottom inside the primary braid in order to increase metal coverage at the neck of the aneurysm. In 2015 the lower profile WEB SL (Single-Layer) and WEB SLS (Single-Layer Sphere) replaced this high profile dual-layer version. The WEB SL has an oblong shape whereas the SLS version has a more spherical shape. The WEB 21 comes in diameters ranging from 4 mm (144 wires) to 11 mm (216 wires) in 1-mm increments. The lengths of the SL version ranges from 3 to 7 mm. The length of the SLS version is 1.6 mm less than its diameter. WEB devices in diameter of 4-7 mm are compatible with a 0.021-inch microcatheter, while 8 and 9 mm diameter needs a 0.027-inch micro catheter. The largest sizes of 10–11 mm go through a 0.033-inch microcatheter. The VIA microcatheter (MicroVention) is available in these different sizes and is specifically designed for the delivery of the WEB device.

Recently, the new low profile WEB 17 system was introduced. The WEB 17 is especially designed for (very) small aneurysms. This system can be delivered through a 0.017-inch microcatheter. The WEB 17 comes in new smaller sizes starting at 3 mm and more shallow devices of 2 mm height for WEB sizes 3-5 mm. The WEB 17 has fewer platinum-cored nitinol wires than WEB 21 (72-108 versus 144) but a similar metal coverage at the neck (57-

59% versus 59-62%). The WEB 17 SL is available in diameters ranging from 2x3 mm to 7x4 mm and the WEB 17 SLS in diameters 4-7 mm. In the 4-7 mm range there is overlap with the WEB 21 system, both in SL and SLS shapes.

General indications in this study

Treatment of patients with both ruptured and unruptured aneurysms is primarily endovascular in our institution. Patients with ruptured aneurysms are treated within 24 hours after admission. Patients with unruptured aneurysms are discussed in a weekly joint meeting with neurologists, neurosurgeons and neuroradiologists.

The WEB system is used for endovascular treatment in our institution since early 2015. We started using the WEB for wide necked bifurcation aneurysms to replace stents, especially in ruptured aneurysms. Encouraging results led us to expand the indication for the WEB to all aneurysms suitable for the device, regardless of location or neck size [9].

With the introduction of the WEB 17, we considered using this WEB in all small aneurysms judged suitable for the device. In general, only shallow aneurysms (height/dome ratio ≤0.5) and some aneurysms with vessels coming from the sac were treated otherwise.

WEB 17-embolization technique

Embolization was performed on a biplane angiographic system (Allura Neuro, Philips Healthcare, Best, the Netherlands) with the patient under general anesthesia by 3 interventional Neuroradiologists with 26, 24 and 12 years of experience (WR,MS,JP). In unruptured aneurysms, 5000 U Heparin was administered as a bolus at the start of the procedure. In ruptured aneurysms, no anticoagulation was given except the Heparin in the pressure bags used for flushing (1000 U/L).

From a 3D angiographic dataset with calibrated distance measurement the required WEB is determined. Width, height and neck size of the aneurysm is measured in 2 orthogonal planes. The WEB is slightly oversized to ensure a stable position inside the aneurysm and1 mm was added to the average width of the aneurysm. To correct for increased height caused by horizontal compression, 1 mm was deducted from the average height of the aneurysm (+1/-1 rule).

A VIA 17 microcatheter was placed inside the aneurysmal fundus. The micro-catheter could be steam-shaped depending on vessel geometry. Once inside the aneurysm, gentle forward pushing and simultaneous withdrawal of the micro catheter slowly deployed the WEB. After deployment, the position of the WEB device was evaluated with fluoroscopy and an additional angiographic run, sometimes including 3D angiography. When the position of the WEB 17 was considered correct, the device was detached and the catheters removed.

Data collection and angiographic follow-up

Patient demographics and treatment- and aneurysm characteristics were recorded and retrospectively reviewed. Clinical follow-up was classified in Modified Rankin Scale (mRS) at 3 months follow-up. Angiographic follow-up was scheduled at 3 months and 3T MRA follow-up at 6 and 12 months according to a previously published protocol [16]. Angiographic results were classified as complete occlusion, neck remnant or aneurysm remnant.

Categorical variables were expressed as frequencies or percentages with 95% CIs. Quantitative variables were expressed with descriptive statistics.

Results

Patients

Between December 19, 2016 and September 19, 2017, 40 patients with 46 aneurysms were treated with the WEB 17 system. Two patients had 3 aneurysms and one patient had 4 aneurysms. Of 46 aneurysms, 25 had ruptured (54%). There were 34 women and 6 men with a mean age of 62 years (median 63, range 46-87). Patient- and aneurysm characteristics are displayed in the Table.

Aneurysm location was anterior communicating artery 17, middle cerebral artery 13, posterior communicating artery 7, pericallosal artery 3, basilar tip 3, and anterior choreoidal artery, carotid tip and cerebellar superior artery each in 1. Mean aneurysm size was 4.9 mm (median 5, range 2-7 mm). WEB sizes and shapes used are displayed in Fig 1.

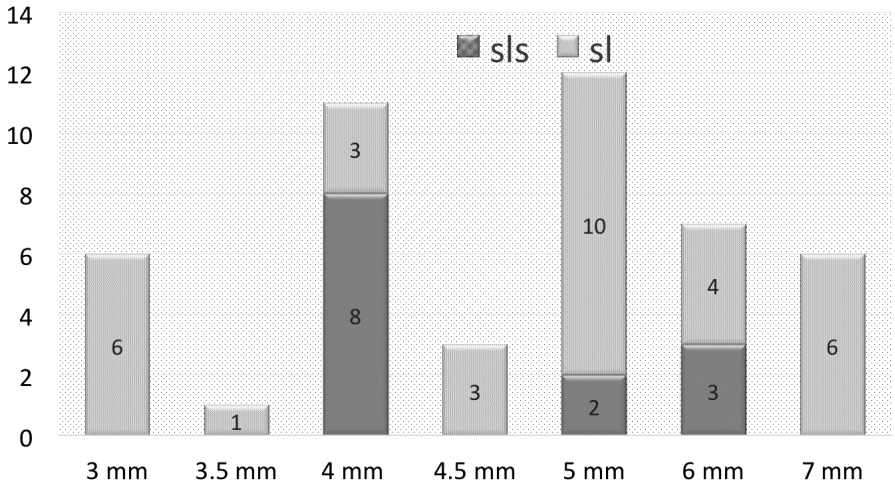

Figure 1. WEB sizes and shapes used in 46 aneurysms treated with WEB 17

Initial results and complications

After WEB placement with sealing of the aneurysm neck, the position of the WEB inside the aneurysm was judged good in 45 of 46 aneurysms without filling of aneurysm remnants. In 1 patient (# 10) the WEB was undersized but this was only noticed after detachment. Follow-up angiography after 1 week showed an aneurysm remnant that was then occluded with coils.

There were 2 thrombo-embolic complications, both in patients with a ruptured anterior communicating artery aneurysm. In a 62-year-old woman (#25) there was a thrombo-embolic occlusion of the carotid tip during diagnostic catheterization before WEB placement. This thrombus could be removed with thrombosuction. After the procedure she had a paresis of the left arm that was cured the next day. The other patient was a 54-year-old woman (#11) with an ICA dissection during diagnostic angiography followed by thrombotic occlusion of the left A2. During WEB placement the thrombus migrated distally. After sealing of the aneurysm, she was treated with Tirofiban infusion and she woke up without a deficit.

There were no procedural ruptures. Overall permanent complication rate was 0% (0 of 40, 97.5%CI 0-10.4%).

Clinical and imaging follow-up

All 15 patients with 21 unruptured aneurysms treated with WEB 17 remained clinically intact. In 25 patients with a ruptured aneurysm, no early or late rebleeds occurred. Clinical follow-up of these 25 patients was as follows: 6 died on sequelae of SAH (mRS 6), one was dependent (mRS 4), 5 had some disability but were independent (mRS 2 and 3) and 13 were independent (mRS 0 and 1).

Six patients died of SAH during hospital admission. Of the 34 surviving patients, 1 refused follow-up angiography. Of the remaining 33 patients, 31 with 37 aneurysms had 3 months angiographic follow-up. Two patients had MRA follow-up at 3 months. Thus, imaging follow-up at 3 months was available in 33 patients with 39 aneurysms (97.5% of eligible aneurysms).

Two aneurysms (5.1%) were incompletely occluded: Patient #10 had early additional treatment of the WEB 17 treated ruptured aneurysm. At 3 months follow-up the aneurysm had reopened and was again retreated, now with a WEB 17. One other aneurysm (patient #33) showed persistent WEB filling at 3 months.

Complete occlusion was achieved in 28 aneurysms (72%) and 9 aneurysms (23%) showed a neck-remnant.

Extended MRA follow-up at 6 months was available in 22 aneurysms (Table). Occlusion status of those aneurysms was not changed during the time interval.

Discussion

Our preliminary clinical experience with the new low-profile WEB 17 system demonstrates an encouraging safety- and efficacy profile. No permanent procedural complications occurred in 40 patients and no rebleeds occurred in 25 patients with a ruptured aneurysm. Aneurysm occlusion at follow-up was satisfactory with 95% adequate occlusion at 3 months with only one aneurysm with retreatment. Two procedural thrombo-embolic complications occurred that could be resolved with thrombosuction and Tirofiban and remained without clinical sequelae.

Comparison with other studies is hampered by several factors. The small sample size of this study keeps confidence levels wide. Both ruptured and unruptured aneurysms were included. All aneurysms were small (≤ 7 mm) since maximum size of WEB 17 is 7 mm. Since larger aneurysm size is a well-known risk factor for reopening over time, our study -only comprising small aneurysms- has a bias towards better results at follow-up.

Our first results with the WEB 17 are in line with other studies using previous generations of WEB or coils to treat intracranial aneurysms [1-15]. In a meta-analysis by Asnafi et al [7], 15 uncontrolled series were included totaling 565 patients with 588 aneurysms treated with the WEB, of which 127 were ruptured. Initial complete and adequate occlusion rates were 27% and 59%, respectively. Midterm complete and adequate occlusion rates after a median of 7 months were 39% and 85%, respectively. Perioperative morbidity and mortality rates were 4% and 1%, respectively. Midterm adequate occlusion rates for ruptured aneurysms were 85%, compared with 84% for unruptured aneurysms. Both patients with ruptured aneurysms and patients with unruptured aneurysms had perioperative morbidity of 2%. Our results of 95% adequate occlusion at 3 months are in the same range as in this meta-analysis and complication rate is in the same order.

Subjectively, handling of the WEB 17 is smoother than WEB 21. The WEB 17 is easily introduced through the VIA 17 micro catheter with very low resistance. Unsheathing and deploying the WEB 17 in the aneurysm is smooth and recapturing is easy with only little pulling force needed. Since the WEB 17 has fewer and thinner wires than WEB 21 with less strong memory forces, deployment may sometimes be incomplete, especially when the WEB is angled or rotated. The softer WEB structure makes deformation by pushing or pulling forces easier than with WEB 21. On the other hand, navigation with the VIA 17 is simpler than with the more rigid VIA 21 micro catheter. The VIA 17 is advantageous in complicated anatomy such as navigating a sharp angled carotid artery-A1 transition or in situations were a “hairpin” position of the micro catheter is required such as in some posterior communicating artery aneurysms (fig 2). With very small aneurysms of 2-3 mm, use of the WEB 17 in the smallest sizes is imperative (fig 3).

There is overlap in WEB 17 and 21 in the sizes 4-7 mm. When a WEB in this size range is required to treat the aneurysm, the operator has a choice between the 2 systems. The WEB 21 system is more stable during WEB deployment and the WEB 21 has better memory

forces. Instead, the WEB 17 system can be navigated easier in complicated anatomy. These considerations may help the operator in the choice between the 2 systems.

Our study confirms the conceptual proof of the WEB 17 system. Despite the construction with fewer platinum-cored nitinol wires, flow disruption proved excellent with only one aneurysm showing persistent WEB filling at follow-up. Adequate aneurysm occlusion was obtained in 95% of aneurysms with imaging follow-up and no rebleeds occurred in the 25 ruptured aneurysms during clinical follow-up. There were no permanent complications.

Recently, a new intrasaccular flow disruptor has become available in clinical practice (Medina Embolization Device, Medtronic, Minneapolis MN). This device combines the design of a detachable coil and the one of an intrasaccular flow disruption device. As for now, clinical experience is limited and the first results are encouraging [17].

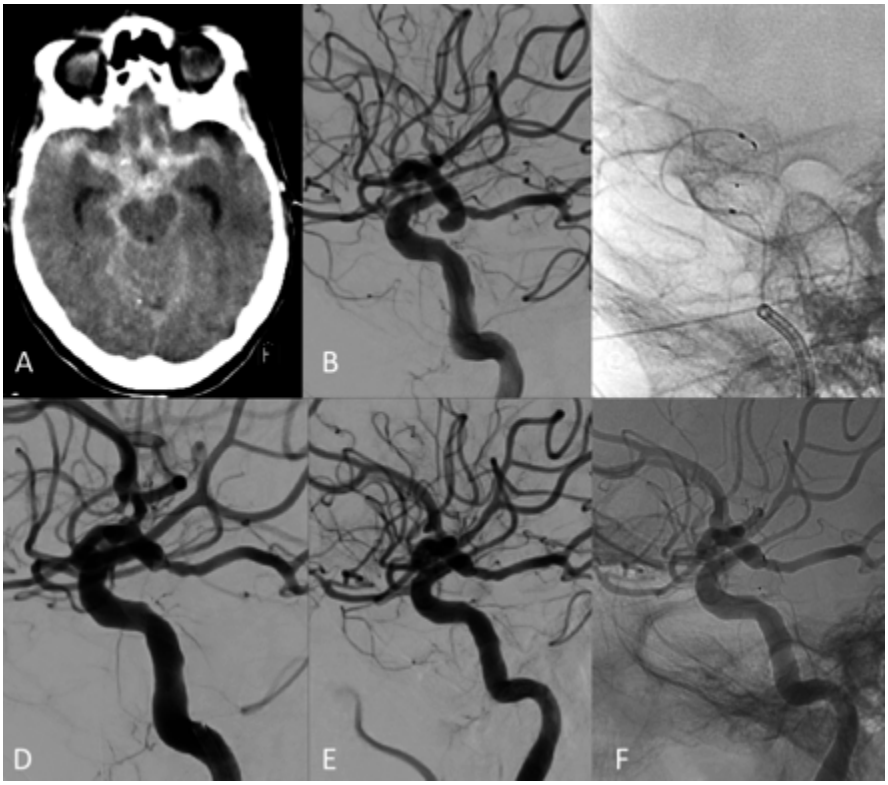

Figure 2. 71-year-old woman (patient # 32) with a ruptured posterior communicating artery aneurysm.
A: CT scan showing diffuse subarachnoid blood.
B: Lateral right internal carotid angiogram reveals small posterior communicating artery aneurysm pointing downwards.
C: VIA 17 in "hairpin" configuration after deployment of WEB 17 SLS 6 mm inside the aneurysm.
D: immediate aneurysm occlusion after WEB 17 placement.
E and F: 3 months follow-up angiogram demonstrates persistent complete aneurysm occlusion.

Our study has several limitations. The limited sample size makes confidence intervals wide and encumbers comparison with other studies. Patients were not consecutive but were selected based on anticipated suitability of the aneurysm for the WEB 17. We, not a core lab, established aneurysm occlusion at follow-up. Follow-up period is limited which precludes conclusions of effectiveness on mid- and long term. The essential choice of small and very small aneurysms is a bias towards better results at follow-up. Strong points of the study are the complete clinical and almost complete imaging follow-up.

In conclusion, the new low profile WEB 17 system is a welcome addition to the existing WEB range. Indication expands to very small aneurysms. The supple VIA 17 microcatheter navigates well in situations with difficult vascular geometry. In the sizes 4-7 mm is overlap of WEB 17 and 21 and the operator may choose between the two systems depending on patient specific factors.

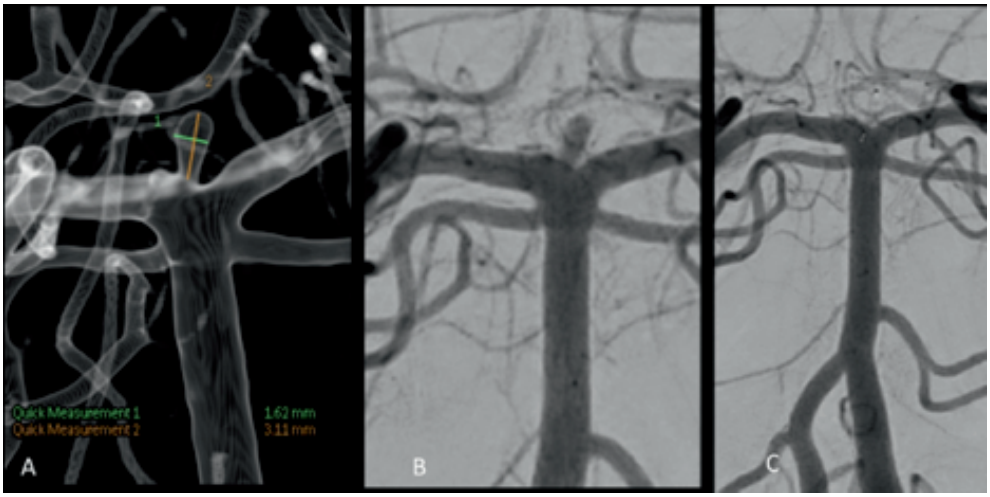

Figure 3. 62-year-old woman (patient #36) with an unruptured small basilar tip aneurysm.
A: basilar tip aneurysm measuring 1.6x3.1 mm
B: immediately after placement of WEB 17, 2x3mm.
C: complete occlusion at 3 months follow-up.

References

1. Armoiry X, Turjman F, Hartmann DJ, et al. Endovascular treatment of intracranial aneurysms with the WEB Device: A systematic review of clinical outcomes. AJNR Am J Neuroradiol 2016;37:868-72
2. Sivan-Hoffmann R, Gory B, Riva R et al. One-year angiographic follow-up after WEB-SL endovascular treatment of wide-neck bifurcation intracranial aneurysms. AJNR Am J Neuroradiol 2015;36:2320-4
3. Lawson A, Goddard T, Ross S, et al. Endovascular treatment of cerebral aneurysms using the Woven EndoBridge technique in a single center: preliminary results. J Neurosurg 2017;126:17-28
4. Lawson A, Molyneux A, Sellar R et al. Safety results from the treatment of 109 cerebral aneurysms using the Woven EndoBridge technique: preliminary results in the United Kingdom. J Neurosurg 2017; Feb 3:1-10 [Epub ahead of print]
5. Gherasim DN, Gory B, Sivan-Hoffmann R et al. Endovascular treatment of wide-neck anterior communicating artery aneurysms using WEB-DL and WEB-SL: short-term results in a multicenter study. AJNR Am J Neuroradiol 2015;36:1150-4
6. Fiorella D, Molyneux A, Coon A et al. Demographic, procedural and 30-day safety results from the WEB Intra-saccular Therapy Study (WEB-IT). J Neurointerv Surg 2017;9:1191-6
7. Asnafi S, Rouchaud A, Pierot L, et al. Efficacy and Safety of the Woven EndoBrigde (WEB) Device for the Treatment of Intracranial Aneurysms: A Systemic Review and Meta-Analysis. AJNR Am J Neuroradiol 2016;37:2287-2292
8. Pierot L, Moret J, Turjman F, et al. WEB treatment of intracranial aneurysms: clinical and anatomic results in the French Observatory. AJNR Am J Neuroradiol 2016;37:655-59
9. van Rooij SB, van Rooij WJ, Peluso JP, et al. WEB treatment of ruptured intracranial aneurysms: a single-center cohort of 100 aneurysms. AJNR Am J Neuroradiol 2017;38:2282-87
10. Pierot L, Spelle L, Molyneux A, et al. Clinical and anatomical follow-up in patients with aneurysms treated with the WEB device: 1-year follow-up report in the cumulated population of 2 prospective, multicenter series (WEBCAST and French Observatory). Neurosurgery 2016;78:133-41
11. Pierot L, Costalat V, Moret J et al. Safety and efficacy of aneurysm treatment with WEB: results of the WEBCAST study. J Neurosurg 2016;124:1250-56
12. Clajus C, Strasilla C, Fiebig T, et al. Initial and mid-term results from 108 consecutive patients with cerebral aneurysms treated with the WEB device. J Neurointerv Surg 2017;9:411-17
13. L. Pierot, I. Gubucz, J.H. Buhk et al. Safety and efficacy of aneurysm treatment with the WEB: Results of the WEBCAST 2 study. AJNR Am J Neuroradiol 2017;38:1151-55

14. Liebig T, Kabbasch C, Strasilla C et al. Intrasaccular flow disruption in acutely ruptured aneurysms: a multicenter retrospective review of the use of the WEB. AJNR Am J Neuroradiol 2015;36:1721-27
15. Popielski J, Berlis A, Weber W, et al. Two-center experience in the endovascular treatment of ruptured and unruptured aneurysms using the WEB device: a retrospective analysis. AJNR Am J Neuroradiol 2108;39:111-117
16. Majoie CB, Sprengers ME, van Rooij WJ et al. MR angiography at 3T versus digital subtraction angiography in the follow-up of intracranial aneurysms treated with detachable coils. AJNR Am J Neuroradiol 2005;26:1349-56
17. Sourour NA, Vande Perre S, Maria FD, et al. Medina embolization device for the treatment of intracranial aneurysms: safety and angiographic effectiveness at 6 months. Neurosurgery 2018;82:155-162

Patient #	Gender	Age	SAH	HH	Aneurysm location	Size (mm)	WEB size	Complication	Imaging FU	Result	additional treatment	mRS at 3 mo	extended MRA FU
1	M	46	no		MCA	4	4 SLS	none	angio 3 mo	complete occlusion		0	6 mo
2	F	65	no		MCA	7	7x3	none	angio 5 mo	complete occlusion		0	6 mo
		65	no		pericall	3	3x2	none	angio 5 mo	complete occlusion			6 mo
		65	no		pericall	3	3x2	none	angio 5 mo	complete occlusion			6 mo
		65	no		MCA	7	3x2	none	angio 3 mo	complete occlusion			6 mo
3	F	60	yes	1	pericall	5	5 SLS	none	angio 3 mo	neck remnant		0	6 mo
4	F	65	no		MCA	5	4.5x3	none	angio 3 mo	neck remnant		0	6 mo
5	F	70	yes	1	AcomA	5	4 SLS	none	refused	NA		0	
6	F	70	no		MCA	7	7x4	none	angio 3 mo	neck remnant		0	6 mo
7	F	49	yes		MCA	4	4 SLS	none	no	NA		6	
8	F	66	yes	3	AcomA	4	3.5x2	none	angio 4 mo	complete occlusion		1	6 mo
9	M	56	yes	5	AcomA	4	4 SLS	none	no	NA		6	
10	F	60	yes	1	AcomA	7	7x3	none	angio 3 mo	aneurysm remnant	coiling, 2nd WEB	1	
11	F	54	yes	2	AcomA	5	6x3	thrombus A2	angio 3 mo	complete occlusion		0	6 mo
12	F	67	yes	3	AcomA	6	5x3	none	no	NA		6	
13	F	51	yes	1	AcomA	4	4 SLS	none	angio 3 mo	complete occlusion		0	6 mo
14	F	53	no		MCA	4	4x2	none	angio 4 mo	complete occlusion		0	6 mo
15	F	57	yes	1	AcomA	3	4 SLS	none	angio 3 mo	complete occlusion		1	6 mo
16	F	57	no		MCA	3	4x2	none	angio 3 mo	neck remnant		0	6 mo
		57	no		PcomA	4	4.5x2	none	angio 3 mo	complete occlusion			6 mo
17	F	64	yes	1	MCA	5	5x3	none	angio 3 mo	neck remnant		0	6 mo
18	F	72	yes	3	PcomA	4	3x2	none	angio 3 mo	complete occlusion		2	6 mo
19	F	70	yes	1	AcomA	4	5x2	none	angio 3 mo	neck remnant		1	6 mo
20	F	87	yes	1	AcomA	4	4.5x2	none	no	NA		6	
21	F	81	yes	4	AcomA	7	6x5	none	no	NA		6	
22	F	54	no		MCA	5	4 SLS	none	angio 3 mo	complete occlusion		0	6 mo
		54	no		PcomA	5	4 SLS	none	angio 3 mo	complete occlusion			6 mo
23	F	77	yes	5	AchorA	4	4x3	none	angio 3 mo	complete occlusion		1	
24	F	64	yes	5	MCA	7	7x3	none	no	NA		6	
25	M	62	yes	1	AcomA	7	6x3	thrombus M1	angio 3 mo	neck remnant		2	6 mo
26	M	66	yes	1	MCA	5	6x3	none	MRA 3 mo	complete occlusion		3	6 mo
27	F	65	yes	1	MCA	4	5x2	none	angio 4 mo	complete occlusion		1	
28	F	65	no		carotid tip	6	6 SLS	none	angio 3 mo	complete occlusion		0	
29	F	62	no		SCA	5	5x3	none	MRA 3 mo	complete occlusion		0	
30	F	52	yes	1	AcomA	6	7x3	none	angio 3 mo	complete occlusion		4	
31	F	59	yes	3	PcomA	4	5 SLS	none	angio 3 mo	neck remnant		2	
32	F	71	yes	3	PcomA	4	6 SLS	none	angio 3 mo	complete occlusion		1	
33	M	66	no		AcomA	5	5x3	none	angio 3 mo	aneurysm remnant	WEB filling, follow-up	0	
34	F	52	no		basilar tip	3	3x2	none	angio 3 mo	complete occlusion		0	
35	F	53	no		AcomA	7	7x3	none	angio 3 mo	neck remnant		0	
36	F	62	no		basilar tip	2	3x2	none	angio 3 mo	complete occlusion		0	
37	F	68	no		PcomA	6	6 SLS	none	angio 3 mo	complete occlusion		0	
		68	no		AcomA	5	5x2	none	angio 3 mo	complete occlusion			
38	F	58	yes		basilar tip	5	5x3	none	angio 3 mo	complete occlusion		2	
39	F	52	no		PcomA	4	5x2	none	angio 3 mo	complete occlusion		0	
40	M	55	yes	1	AcomA	6	5x2	none	angio 3 mo	complete occlusion		1	

Patient- and aneurysm characteristics of 40 patients with 46 ruptured or unruptured aneurysms treated with WEB 17

Abbreviations

AcomA = anterior communicating artery, PcomA = posterior communicating artery, MCA = middle cerebral artery
Pericall = pericallosal artery, AchorA = anterior choreoideal artery, SCA = Superior cerebellar artery

CHAPTER

8

Mid-term 3T MRA follow-up of intracranial aneurysms treated with the Woven EndoBridge

van Rooij SBT, Peluso JP, Sluzewski M, Kortman HG, Boukrab I, van Rooij WJ

Interventional Neuroradiology 2018;24:601-607

Introduction
Angiography is the standard follow-up modality for treated aneurysms with the WEB and MRA is a useful for extended follow-up. We present the results of WEB treated aneurysms with angiographic follow-up at 3 months and at least 18 months 3T MRA follow-up.

Materials and Methods
Included were 52 patients with 53 aneurysms treated with the WEB between February 2015 and July 2016. There were 29 women and 23 men with a mean age of 60 years (median 62, range 23-76). Mean aneurysm size was 6.2 mm (median 6, range 3-16 mm).

Results
3T MRA follow-up was mean 19.6 months (median 18, range 18-36 months). One patient had an aneurysm remnant at 3 months angiography that was additionally coiled and with stable complete occlusion at 18 months 3T MRA follow-up. At 3 months follow-up angiography, 44 aneurysms were completely occluded and 8 had a neck remnant. At latest 3T MRA, stable complete occlusion was present in 43 aneurysms and stable neck remnant in 8. One PCA dissection aneurysm was stable at 3 and 6 months but was enlarged and reopened at 18 months, confirmed with angiography.
Focal signal loss by the proximal marker of the WEB was apparent in 4 patients without compromising diagnostic evaluation.

Conclusion
WEB treated aneurysms with adequate occlusion at 3 months angiography remained stable during serial 3T MRA follow-up of 18-36 months. One PCA aneurysm reopened during the 6-18 months interval. Once the WEB treated aneurysm is adequately occluded on short term, later reopening is uncommon.

Introduction

Endovascular treatment with coils is the preferred modality for the management of both ruptured and unruptured aneurysms [1]. For complex aneurysms such as large size, wide-necked or vessels originating from the sac, the endovascular approach may need additional devices such as supporting balloons or stents or a different concept of flow diversion or flow disruption [2-6].

The Woven EndoBridge (WEB, MicroVention, Tustin CA) is a recently introduced intrasaccular device designed to disrupt the intra-aneurysmal flow at the aneurysm neck level. Initial experience with the WEB device show good results in terms of aneurysm occlusion, complications and protection against (re)bleeds [7-11].

The potential risk of aneurysm recanalization after endovascular treatment makes regular imaging follow-up necessary [12]. Angiography is the standard for follow-up but this modality is invasive with potential neurological complications and uses radiation exposure. Several MR angiography techniques have been tested and used to follow endovascular treated intracranial aneurysms [13-16]. In our institution, we use 3D-TOF-MRA at 3T (3T MRA) for follow up and validated this technique against angiography [15,16]. Clinical data using MRA for follow-up of WEB treated aneurysms showed that the WEB is compatible with MR imaging in terms of safety and image quality both at 1.5 and 3T. First results suggest that MRA is a useful screening tool [13,17,18].

At our institution, aneurysms treated with the WEB were followed with angiography at 3 months, with 3T MRA at 6 months and every 6-month interval thereafter.
In this study, we evaluate the mid-term occlusion stability of aneurysms treated with the WEB device of aneurysms with at least 18 months imaging follow-up.

Materials and Methods

Study population

From February 2015 onwards, consecutive patients with ruptured and unruptured intracranial aneurysms treated with the WEB were entered in a database. Imaging follow-up consisted of angiography at 3 months and 3T MRA at 6 months and 12-18 months intervals thereafter. Included in this study were patients treated with the WEB and with imaging follow-up of at least 18 months.

Imaging technique for angiography

Follow-up angiography was performed on a biplane angiographic system (Allura Neuro, Philips Healthcare, Best, the Netherlands). With transfemoral catheterization, we performed selective injections of the internal carotid or vertebral artery, according to the aneurysm location. We started with 3D Rotational Angiography of the involved vessel,

completed with 2D projections that best showed the relation of the aneurysm with the surrounding vessels.

Imaging technique for 3T MRA

MRI and MRA were performed on a 3.0-Tesla system (Philips Intera R10, Philips Healthcare, Best, the Netherlands) using the sensitivity encoding (SENSE) phased array head coil (MRI Devices, Gainesville, FL).

The MR protocol included axial and coronal T2-weighted fast spin echo, coronal T1-weighted spin echo and high-resolution multi slabs 3D-TOF (MOTSA) MRA sequences. Imaging parameters for the T1-weighted spin echo sequence were 570/12 (TR/TE), 256x256 matrix (reconstructed to 512x512), 180-mm field of view, 90% rectangular field of view, 3-mm thick sections with 0.3-mm gap. Parameters for the T2- weighted fast spin echo sequence were 3394/80 (TR/TE), 400x400 matrix (reconstructed to 512x512) 230-mm field of view, 70% rectangular field of view, 3-mm thick sections with 0.5-mm gap. For the MOTSA 3D-TOF MR sequence the parameters were as follows: 3D fast field echo T1-weighted sequence, 21/4 (TR/TE) flip angle 20º, 512x512 matrix (reconstructed to 1024x1024), 200-mm field of view, 85% rectangular field of view, 1.0-mm thick sections, interpolated to 0.5-mm, 160 slices acquired in 8 slabs. The measured voxel size of the MOTSA 3D-TOF MR sequence was 0.39 x 0.61 x 1 mm and the reconstructed voxel size 0.2 x 0.2 x 0.5 mm.

Analysis of imaging follow-up and data

Two interventional neuroradiologists with 25 and 12 years experience (WR and JP) evaluated angiography and MRA examinations in consensus. For the 3 months angiographic follow-up examination, subtracted and non-subtracted series were available in PACS and freely rotatable 3D images on a dedicated computer. Aneurysm occlusion status was defined as complete occlusion, neck remnant or aneurysm remnant. A neck remnant was defined as residual filling at the base of the aneurysm. An aneurysm remnant was defined as residual filling of part of the aneurysm. Central recess filling of the WEB was not considered as aneurysm filling.

With MRA follow-up examinations, source images, multiple maximum intensity projections and 3D reconstructions were used. MR images were evaluated for artifacts, presence and size of aneurysm remnants and recurrences, and patency of parent and branch vessels.

Any discrepancy between follow-up MRA and the first 3 months angiographic follow-up indicating progressive reopening of the aneurysm was an indication for repeated angiography and possible additional treatment.

Quantitative variables were expressed with descriptive statistics, and categorical variables were expressed as frequencies or percentages with 95% CIs.

Results

Patients

Between February 2015 and July 2016, 94 aneurysms in 93 patients were treated with the WEB. There were 63 ruptured and 31 unruptured aneurysms. Of 63 patients with a ruptured aneurysm, 10 died during hospital admission on the sequelae of SAH. Of the remaining 83 patients with 84 aneurysms, 1 patient refused 3 months follow-up angiography. Follow-up angiography was available in 82 patients with 83 aneurysms.

Two aneurysms in 2 patients were incompletely occluded, were additionally treated and had short-term follow-up MRA only after additional treatment.

Of the remaining 80 patients with 81 aneurysms, 52 patients with 53 aneurysms (65%) had 3T MRA follow up of at least 18 months and these patients are the subjects of this study. Patient-and aneurysm characteristics are summarized in the online Table. Aneurysms were treated with WEB without additional stents. One aneurysm was treated with WEB and coils in the fundus.

There were 23 men and 29 women with a mean age of 60 years (median 62, range 23-76 years). Of 53 aneurysms, 34 had ruptured and 19 were unruptured.

Aneurysm location was anterior communicating artery in 26, posterior communicating artery in 6, middle cerebral artery in 7, carotid tip in 4, pericallosal artery in 3, basilar tip in 3, superior cerebellar artery in 2 and internal carotid artery and posterior cerebral artery each in 1. Of 53 aneurysms, 33 (62%) had a wide neck defined as ≥4 mm or dome-neck ratio ≤ 1.5. Mean aneurysm size was 6.2 mm (median 6, range 3-16 mm).

Imaging follow up

At 3 months angiography, one patient with a trilobar anterior communicating artery aneurysm (pt# 51) had an aneurysm remnant that was additionally coiled. This patient had 18 months follow up 3T MRA after additional coiling with stable complete occlusion of the aneurysm (fig 1). Of the remaining 52 aneurysms, 44 were completely occluded (fig 2) with proximal recess filling in 5 and 8 had a neck remnant.

3T MRA follow-up was mean 19.6 months (median 18, range 18-36 months). Focal signal loss by the proximal marker of the WEB was apparent in 4 patients (fig 3) without compromising diagnostic evaluation. Stable complete occlusion was present in 43 aneurysms (with proximal recess filling in 4) and a stable neck remnant in 8 aneurysms.
One ruptured posterior cerebral artery aneurysm (pt # 25) was stable at 6 months (proximal recess filling) but was enlarged and reopened on the 18 months MRA, confirmed at angiography (fig 4). This patient is scheduled for additional treatment.

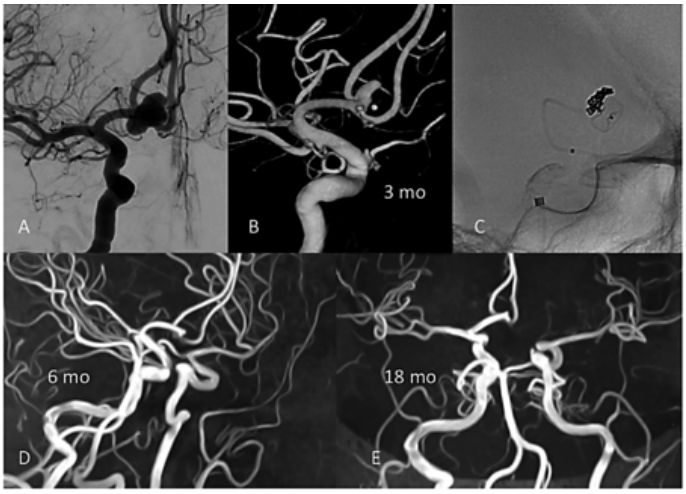

Figure 1. Middle-aged patient (# 51) with incidental trilobar anterior communicating artery aneurysm
A: right carotid angiogram with trilobar aneurysm.
B and C: 3D angiogram 3 months after WEB treatment shows aneurysm remnant that was additionally coiled.
D and E: 3T MRA follow-up at 6 and 18 months demonstrates stable complete occlusion.

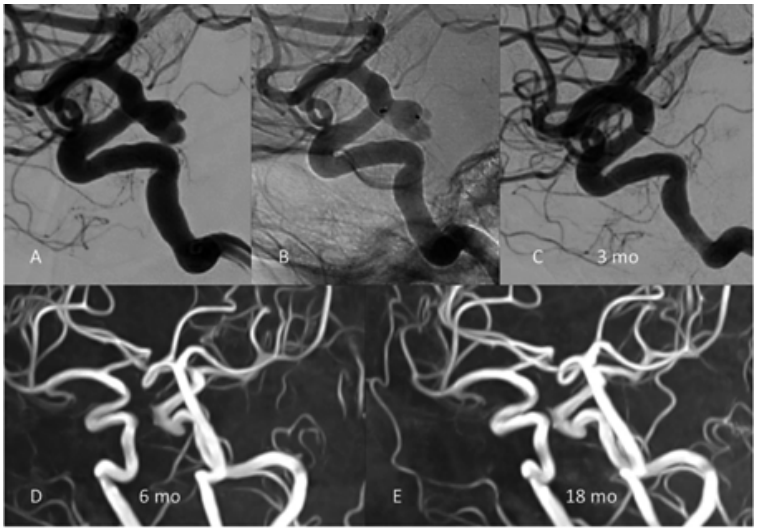

Figure 2. Elderly patient (#24) with a ruptured posterior communicating artery aneurysm.
A: Right internal carotid angiogram shows irregular shaped posterior communicating artery aneurysm.
B: immediately after WEB placement persistent contrast filling.
C: complete occlusion at 3 months follow-up angiogram.
D and E: 3T MRA follow-up at 6 and 18 months demonstrates stable complete occlusion.

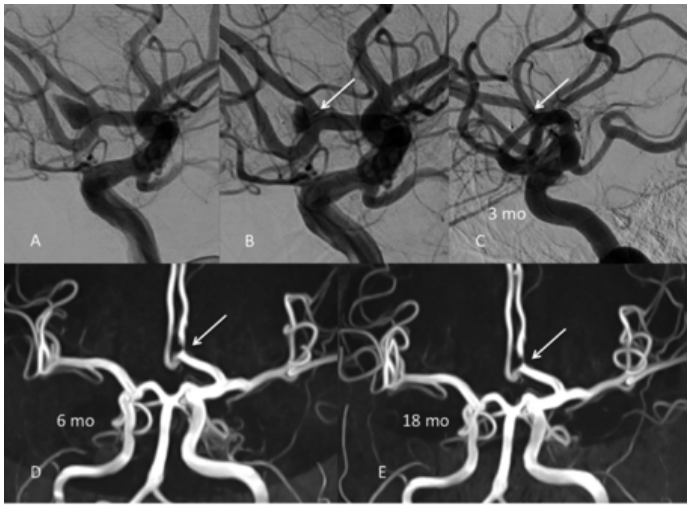

Figure 3. Middle-aged patient (#15) with a ruptured anterior communicating artery aneurysm.
A: left carotid angiogram demonstrates anterior communicating artery aneurysm
B: immediately after WEB placement. Note protrusion of the proximal WEB marker into the parent vessel (arrow in A-E).
C: 3 months angiographic follow-up with complete occlusion.
D and E: 3T MRA at 6 and 18 months shows persistent complete occlusion of the aneurysm with focal signal loss in the parent vessel due to the proximal WEB marker.

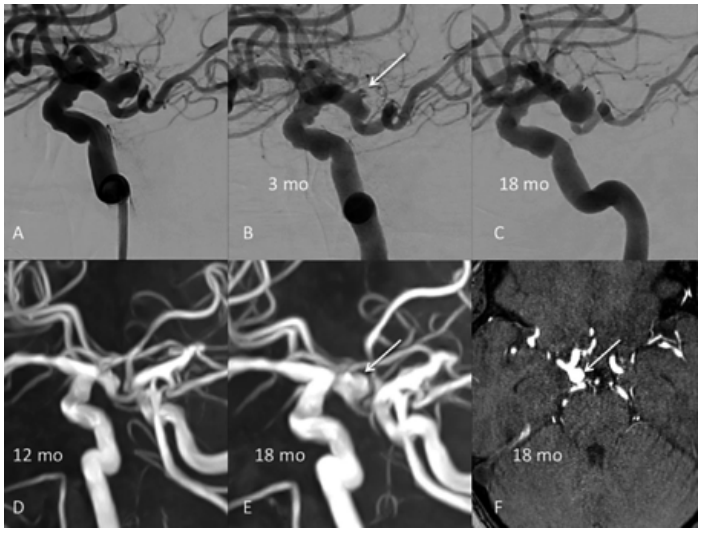

Figure 4. Elderly patient (#25) with a ruptured posterior cerebral artery aneurysm.
A: right carotid angiogram reveals wide necked aneurysm on a fetal posterior cerebral artery.
B: 3 months follow-up angiogram with central recess filling of the WEB (arrow).
C: angiogram at 18 months confirms reopening found on 3T MRA (E and F)
D: 3T MRA at 12 months confirms occlusion at 3 months in B.
E and F: MIP and source image of 3T MRA at 18 months demonstrates enlargement and reopening of the aneurysm (arrows).

Discussion

Our preliminary results indicate that 3T MRA is a beneficial screening tool for the mid- and long-term imaging follow-up of aneurysms treated with the WEB device after initial angiographic short-term follow-up. Correlation with short-term angiography was good for complete occlusion, central recess filling, neck remnants and patency of side branches in aneurysms that were stable. In one aneurysm, 3TMRA showed reopening and aneurysm growth which was subsequently confirmed on angiography (fig 4).

Our strategy of short-term angiographic follow-up of WEB treated aneurysms depicted reopening in 2 and these aneurysms were early additionally treated. Aneurysms with adequate occlusion (complete occlusion or neck remnant) on short-term angiographic follow-up showed stable results on follow-up 3T MRA in serial scans up to 36 months in all but one aneurysm.

Correlation of angiography and MRA for follow-up of aneurysms treated with the WEB has been the subject of several studies [13,17,18]. The drawbacks of MRA in WEB treated aneurysms are analogous to those of aneurysms treated with stents or flow diverters. The braiding of the WEB consists of platinum cored nitinol wires, similar to flow diverters and intracranial stents. These electrically conductive materials cause susceptibility artifacts and in geometry form a Faraday cage that shields the MR signal. MR imaging of the lumen of a stent or flowdiverter is difficult or impossible due to a combination of susceptibility artifacts and Faraday shielding [19,20]. Analogous, the lumen of the WEB device is obscured for MR imaging. In addition, the proximal WEB marker, were all wires of the braid come together, causes focal signal loss due to susceptibility artifacts. In clinical practice, this focal signal loss is obvious in a small minority of WEB treated aneurysms and is readily recognized as such without interfering with evaluation of occlusion status (fig 3). Persistent flow in (part of) the WEB is an occasional finding at short-term angiographic follow-up. In our experience it occurred only once [21] and in this case we had no direct MRA and angiographic correlation. However, Timsit et al [13] described a case with persistent flow within the WEB on angiography that was not visible on both 3D-TOF-MRA and CE-MRA at 3T performed the same day due to Faraday shielding. So, both on theoretical and practical grounds, flow within the braid of the WEB will not be apparent on 3T MRA.

Our follow-up policy with serial 3T MRA after short-term angiography included angiography whenever 3T MRA findings indicated possible reopening that would potentially need additional treatment. This phenomenon occurred only once and suspected reopening and aneurysm growth was confirmed with angiography.

Our preliminary data indicate that 3T MRA is a useful imaging modality in the mid-and long-term follow-up of aneurysms treated with the WEB, despite obvious shortcomings. We found that all but one WEB treated aneurysm remained stable during serial 3T MRA follow-up. The one aneurysm that reopened probably was a PCA dissection aneurysm (fig 4)

and dissections often behave differently from saccular aneurysms. These first imaging follow-up data of WEB treated aneurysms are in concordance with data from coiled aneurysms [22,23]. Once the WEB treated aneurysm is adequately occluded on short term, reopening over time is uncommon.

Our study has several limitations. First, there was a 3 months interval between angiography and 3T MRA and direct comparison between the 2 modalities was not possible. Second, the study population was a selection of WEB treated aneurysms with at least 18 months 3T MRA follow-up and aneurysms with early reopening were thus disregarded. Third, the lack of statistics makes our results mostly descriptive and difficult to translate to other practices. Fourth, diagnostic accuracy of 3T MRA for WEB treated aneurysms is not completely elucidated. Strong points of the study included a homogeneous group of aneurysms treated with WEB and the serial 3T MRA examinations allowing comparison over time.

In conclusion, 3T MRA seems a promising screening procedure for the serial follow-up of aneurysms treated with the WEB. However, due to some susceptibility artifacts and Faraday shielding, angiography remains the criterion imaging modality. The vast majority of adequately occluded WEB treated aneurysms at short-term remain stable occluded at mid-term follow-up.

References

1. Molyneux AJ, Kerr RS, Yu LM, et al; International Subarachnoid Aneurysm Trial (ISAT) Collaborative Group. International Subarachnoid Aneurysm Trial (ISATof neurosurgical clipping versus endovascular coiling in 2143 patients with ruptured intracranial aneurysms: a randomized comparison of effects on survival, dependency, seizures, rebleeding, subgroups, and aneurysm occlusion. Lancet 2005;66:809-17
2. Piotin M, Blanc R, Spelle L, et al. Stent-assisted coiling of intracranial aneurysms: clinical and angiographic results in 216 consecutive aneurysms. Stroke 2010;41:110-5
3. Bartolini B, Blanc R, Pistocchi S, et al. "Y" and "X" stent-assisted coiling of complex and wide-neck intracranial bifurcation aneurysms. AJNR Am J Neuroradiol 2014;35:2153–58
4. Bechan RS, Sprengers ME, Majoie CB, et al. Stent-assisted coil embolization of intracranial aneurysms: Complications in acutely ruptured versus unruptured aneurysms. AJNR Am J Neuroradiol 2016;37:502-7
5. Madaelil TP, Moran CJ, Cross DT 3rd, Kansagra AP. Flow diversion in ruptured intracranial aneurysms: A meta-analysis. AJNR Am J Neuroradiol 2017;38:590-595
6. Cagnazzo F, Mantilla D, Lefevre PH, et al. Treatment of middle cerebral artery aneurysms with flow-diverter stents: A systematic review and meta-analysis. AJNR Am J Neuroradiol 2017;38:2289-2294
7. Pierot L, Moret J, Turjman F, et al. WEB treatment of intracranial aneurysms: clinical and anatomic results in the French Observatory. AJNR Am J Neuroradiol 2016;37:655-9
8. Pierot L, Spelle L, Molyneux A, et al. Clinical and anatomical follow-up in patients with aneurysms treated with the WEB device: 1-year follow-up report in the cumulated population of 2 prospective, multicenter series (WEBCAST and French Observatory). Neurosurgery 2016;78:133-41
9. Armoiry X, Turjman F, Hartmann DJ, et al. Endovascular treatment of intracranial aneurysms with the WEB Device: A systematic review of clinical outcomes. AJNR Am J Neuroradiol 2016;37:868-72
10. van Rooij SB, van Rooij WJ, Peluso JP, et al. WEB treatment of ruptured intracranial aneurysms: a single-center cohort of 100 patients. AJNR Am J Neuroradiol 2017,38:2282-2287
11. van Rooij SB, van Rooij WJ, Peluso JP, Sluzewski M. The Woven EndoBridge (WEB) as primary treatment for unruptured aneurysms. Interv Neuroradiol 2018 Jan 1 [Epub ahead of print]
12. Ferns SP, Sprengers ME, van Rooij WJ et al. Coiling of intracranial aneurysms: a systematic review on initial occlusion and reopening and retreatment rates. Stroke 2009;40:e523-9
13. Pierot L, Portefaix C, Gauvrit JY. Follow-up of coiled intracranial aneurysms: comparison of 3D time-of-flight MR angiography at 3T and 1.5T in a large prospective series. AJNR Am J Neuroradiol 2012;33:2162–66

14. Pierot L, Portefaix C, Boulin A, et al. Follow-up of coiled intracranial aneurysms: comparison of 3D-time-of-flight and contrast-enhanced magnetic resonance angiography at 3T in a large, prospective series. Eur Radiol 2012;22;2255–63
15. Majoie CB, Sprengers ME, van Rooij WJ, et al. MR angiography at 3T versus digital subtraction angiography in the follow-up of intracranial aneurysms treated with detachable coils. AJNR Am J Neuroradiol 2005;26:1349-56
16. Sprengers ME, Schaafsma JD, van Rooij WJ, et al. Evaluation of the occlusion status of coiled intracranial aneurysms with MR angiography at 3T: is contrast enhancement necessary? AJNR Am J Neuroradiol 2009;30:1665-71
17. Mine B, Tancredi I, Aljishi A, et al. Follow-up of intracranial aneurysms treated by a WEB flow disrupter: a comparative study of DSA and contrast-enhanced MR angiography. J Neurointerv Surg 2016;8:615-20
18. Timsit C, Soize S, Benaissa A, et al. Contrast-enhanced and Time-of-Flight MRA at 3T compared with DSA for the follow-up of intracranial aneurysms treated with the WEB Device. AJNR Am J Neuroradiol 2016;37:1684-9
19. Klemm T, Duda S, Machann J, et al. MR imaging in the presence of vascular stents: a systematic assessment of artifacts for various stent orientations, sequence types, and field strengths. J Magn Reson Imaging 2000;12:606
20. Choi JW, Roh HG, Moon WJ, et al. Optimization of MR parameters of 3D-TOF-MRA for various intracranial stents at 3.0T MRI. Neurointervention 2011;6:71–77
21. van Rooij SB, Peluso JP, Sluzewski M, et al. The new low-profile WEB 17 system for treatment of intracranial aneurysms: first clinical experiences. AJNR Am J Neuroradiol 2018;39:859-863
22. Ferns SP, SPrengers ME, van Rooij WJ, et al. Late reopening of adequately coiled intracranial aneurysms: frequency and risk factors in 400 patients with 440 aneurysms. Stroke 2011;42:1331-7
23. Van Amerongen, Boogaarts HD, de Vries J, et al. MRA versus DSA for follow-up of coiled intracranial aneurysms: a meta-analysis. AJNR Am J Neuroradiol 2014;35:1655-61

CHAPTER

9

A Systematic Review and Meta-Analysis of Woven EndoBridge Single Layer for Treatment of Intracranial Aneurysms

van Rooij SB, van Rooij WJ, Sprengers ME, Damen J, Verbaan D, Peluso JP, Majoie CB

Interv Neuroradiol 2020 Feb 6 [Epub ahead of print]

Background
the Woven Endobridge (WEB) is an intrasaccular device for treatment of intracranial aneurysms. The first generation was a high profile double layer braid (WEB DL). This has been replaced by lower profile single layer device (WEB SL).

Purpose
to evaluate procedural complications, adequate occlusion at follow-up, rebleeds and retreatments of the new generation low-profile WEB Single Layer device for intracranial aneurysm treatment.

Data sources
Medline, Embase and Web of Science Conference Proceedings databases.

Study selection
Articles after 2010 reporting on outcomes of patients treated with WEB were selected. Studies reporting on both WEB DL and SLS were included if results could be stratified. The search strategy provided 589 articles, 15 were included.

Data analysis
Multiple patient- aneurysm- and imaging characteristics were extracted. A meta-analysis was performed of cumulative data of various variables as proportions with 95%CI confidence limits.

Data synthesis
Fifteen papers reported on WEB SL treatment in 963 aneurysms. Procedural rupture occurred in 8 of 963 patients (0.83%; 95%CI 0.39-1.66%), thromboembolic events in 54 of 963 patients (5.61%, 95CI 4.31-7.26%). Cumulative morbidity was 2.85 % (27/949, 95%CI 1.95-4.12%), mortality 0.93% (9/963, 95%CI 0.46-1.80%). Adequate occlusion at follow-up was 83.3% (613/736; 95%CI 80.4-85.8%). Retreatment was reported in 38 of 450 aneurysms with follow-up (38/450; 8.4%, 95CI 6.2-11-4%). Rebleeds occurred in 3 patients in 644 aneurysms with follow-up (0.47%, 95%CI 0.09-1.43%).

Limitations
Most studies were retrospective cohort studies with self-reported data.

Conclusion
WEB SL is a safe and effective low profile device for (wide necked) aneurysms, both ruptured and unruptured.

Introduction

Endovascular therapy has become the first-line treatment modality for intracranial aneurysms over surgical clipping [1-3]. Wide-necked aneurysms, especially located at arterial bifurcations, are generally not suited for simple coiling. For these aneurysms, stent- or balloon-assisted techniques and flow diverters have been developed. However, these endovascular approaches are technically more challenging and are hampered by increased complications compared to simple coiling [4]. Besides, with stents and flow diverters, longstanding double antiplatelet therapy is needed.

The Woven EndoBridge device (WEB; Sequent Medical, Aliso Viejo, California, USA) is developed to overcome these limitations and improve the safety of the treatment of wide-necked bifurcation aneurysms without the need for supporting stents and concomitant dual antiplatelet therapy. The WEB consists of a self-expanding, oblong or spherical braid of platinum-cored nitinol wires intended to implant inside the aneurysmal sac, and it can be electro thermally detached. After deployment, the mesh covers the neck of the aneurysm, resulting in flow disruption in the sac and thrombosis of the aneurysm.

The WEB was introduced in Europe in 2010 and in January 2019 the U.S. Food and Drug Administration approved the device. Since its introduction in 2010, the WEB has evolved from a high-profile dual-layer (WEB-DL) to a low-profile single-layer (WEB-SL and WEB-SLS) construction.

The WEB-DL contains a second nitinol braid and was the first available WEB device for clinical use. These double-layered devices were delivered through high profile 0.027, 0.033 and 0.038-inch microcatheters. From November 2013, WEB-SLS that could be delivered through 0.027-inch microcatheters for WEB sizes 4-7 mm replaced WEB-DL. In February 2015, the WEB 21 system (0.021-inch microcatheters for WEB sizes 4-7 mm) was introduced followed by the WEB 17 system (0.017-inch microcatheter for WEB sizes 3-7 mm) in December 2016.

The constructional improvements have enormously expanded the technical application possibilities of the WEB device. While the high profile microcatheters needed for the WEB-DL could only navigate in vessels with a straight course, the WEB 21 and 17 SL and SLS can be navigated through tortuous vasculature and can also be used for small aneurysms from 2mm. This technical improvement resulted in an expansion of the indication for use of the WEB with changing aneurysm population characteristics in earlier studies with WEB-DL (unruptured wide-neck bifurcation aneurysms) and later studies with WEB SLS (also more distal and sidewall aneurysms, ruptured and unruptured). Recent meta-analyses of clinical use of the WEB device have included early studies with WEB-DL [5-8]. Since WEB-DL is no longer used, these reviews might not reflect current clinical practice.

In this systematic review, we aim to assess the safety and effectiveness of the current WEB-SL and SLS device for endovascular therapy of both ruptured and unruptured intracranial aneurysms.

Methods

Search Strategy and Article Selection

A systematic review of the literature was performed to identify studies reporting on clinical experience with WEB devices for intracranial aneurysms. Single – and multicenter retrospective and prospective cohort studies reporting on safety and/or outcome were considered for inclusion. This review was performed following the PRISMA (Preferred Reporting Items for Systematic Reviews and Meta-Analyses) statement [9]. Medline, Embase, and Web of Science Conference Proceedings databases were searched. The WEB device was introduced in 2010 and articles published before that time were excluded. For the search strategy, key researchers and trials were identified in a scoping search and included in the search strategy on WEB devices. The search strategy was made with help from a librarian (JD) and is described in Supplementary Table 1. The resulting flowchart is shown in Figure 1. After the articles were imported into Rayyan QCRI, duplicates were removed.

Two authors (SBR and WR) independently screened titles and abstracts for articles reporting on the clinical use of the WEB device for intracranial aneurysms. Articles in English language reporting on the clinical and imaging outcome of aneurysms treated with a WEB device were selected for full-text screening. Case reports, congress abstracts, commentaries, and reviews were excluded. Studies that reported on the use of both WEB-DL and SLS were included if results could be stratified. With overlapping cohorts, only the largest and most recent cohort was included. Web of Science was consulted for additional articles, and references of selected articles were checked for possible additional relevant studies. Finally, 3 recent studies were added [10,30,31].

Data Extraction

The following variables, when available, were extracted from the full text of each study: study design, number of patients, number of aneurysms treated, number of ruptured aneurysms, aneurysm type, successful WEB device placement, WEB-DL, WEB-SL/S, use of additional devices, anti-coagulation protocol, thrombo-embolic complications, other complications, length of follow-up, complete aneurysm occlusion, aneurysm neck remnant, adequate occlusion (complete occlusion and neck remnant), aneurysm remnant, retreatment and rerupture.

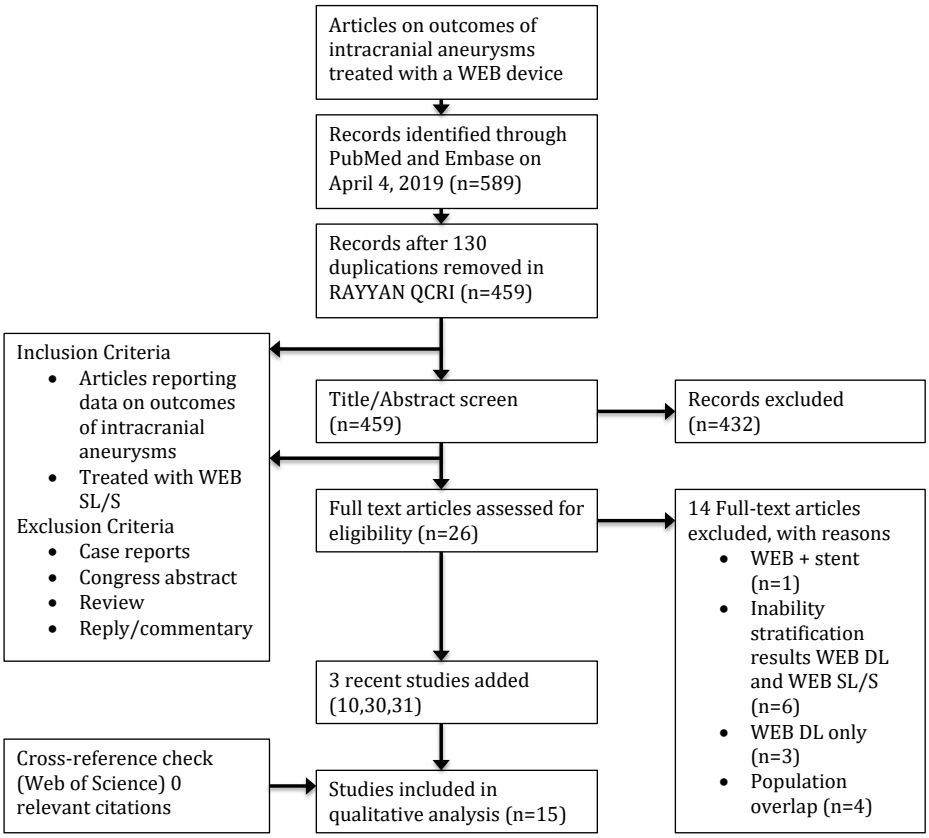

Figure 1. Flowchart search strategy.

Results

The search identified 589 articles (Fig 1). After removing duplicates and screening for title and abstract, 562 articles were excluded and the full texts of 26 articles were reviewed. Subsequently, 15 studies were included in the review [10-22, 30,31], with 963 aneurysms treated with WEB SL/S. Study characteristics are displayed in Table 1.

Five studies reported on the results of both WEB-DL and WEB-SL/S allowing stratification of the results [12, 15, 20-22]. In one study with comparative data from WEB 17 and previous WEB versions, only the WEB 17 data could be used [30].

Feasibility

Feasibility was reported in 11 of 15 studies. Of 986 attempted aneurysm treatments with the WEB SL/S, 953 were successful (96.7%, 95%CI 95.3-97.6%).

Additional devices

Twelve studies with a total of 832 aneurysms reported the use of additional coils and/or stents in 64 cases (7.7%) with a wide range between studies from 0% (0 of 148) [10] to 15.3% (15 of 98) [16]. The reasons to use additional devices (primary treatment or bail-out procedure) are not elucidated in the studies.

Anticoagulation

Anticoagulation was reported in all studies. There was a wide variation between studies and between operators. In unruptured aneurysms, mostly heparin was used either alone [18] or in combination with preloaded and prolonged single or dual antiplatelet medication. In ruptured aneurysms, the anticoagulation protocol varied between heparin in the pressure bags only [14,19] and bolus heparin followed by single or dual antiplatelet medication after the procedure.

Complications

Complications and adverse events associated with WEB SL/S device placement were described in all studies. Procedural aneurysm rupture was reported in 8 of 963 patients (0.83%; 95%CI 0.39-1.66%). Thromboembolic events associated with the procedure occurred in 54 of 963 patients (5.61%, 95CI 4.31-7.26%). Cumulative morbidity was 2.85 % (27/949, 95%CI 1.95-4.12%) and mortality 0.93% (9/963, 95%CI 0.46-1.80%). Rebleeds were reported in 12 studies with 644 aneurysms with follow-up. Only 3 patients in 3 studies with mean follow-up of 3.3 and 14.4 months [13,15,20] had a rebleed (0.47%, 95%CI 0.09-1.43%)

Aneurysm occlusion and retreatment at follow-up

The overall rate of adequate aneurysm occlusion (complete occlusion or neck remnant) at last reported follow-up in 13 studies reached 83.3% (613/736; 95%CI 80.4-85.8%). Retreatment during follow-up was reported in 8 studies. Of 450 aneurysms with follow-up, 38 were retreated (8.4%, 95CI 6.2-11.4%).

Ruptured Aneurysms

Specific outcomes for ruptured aneurysms treated with WEB-SL/S were described in 2 retrospective studies [14,17] and 1 prospective cohort study [19]. The first retrospective study [14] included 33 aneurysms, 21 of which had a mean follow-up of 14 months. Of these 21 aneurysms, 15 (71.4%) were adequately occluded and 6 (28.6%) showed a remnant. WEB-related mortality was 12% (4/33) and morbidity was 3% (1/33). In the other retrospective study [17], no morbidity and mortality occurred in 33 aneurysms in 33 patients. Six months follow-up was available in 26 aneurysms. Adequate occlusion was reported in 25/26

(96%) and one aneurysm (4%) had a remnant. The prospective cohort study [19] comprised 100 ruptured aneurysms. Procedure-related morbidity was 3% (3/100) and mortality 1% (1/100). At 3 months follow-up, 71/74 aneurysms (96%) were adequately occluded and 3 had a remnant (4%). Two aneurysms were retreated. Of note, in the 3 studies reporting on ruptured aneurysms only, no rebleeds occurred during follow-up. Comparison of outcomes of ruptured versus unruptured aneurysms treated with WEB SL/S was not possible due to study heterogeneity and lack of outcome stratification in studies reporting on cohorts with both ruptured and unruptured aneurysms.

Discussion

In this review, clinical and imaging outcomes of intracranial aneurysms treated with the WEB-SL/S are described. We identified 7 prospective studies and 8 retrospective studies totaling 963 aneurysms treated with WEB-SL/S (10-22,30,31).

We specifically sought for articles reporting on results of WEB-SL/S or articles were results of WEB-DL could be stratified and excluded. The reason why we wanted to exclude the results of aneurysms treated with WEB-DL is twofold. First, the WEB-DL was the first WEB on the market and consisted of a high profile dual-layer device needing large-bore catheters up to 0.038-inch for placement. The indications were limited to difficult proximal aneurysms on arterial bifurcations that could not be treated otherwise. Second, at the beginning of the use of the WEB, it was not yet clear that oversizing the device was imperative to obtain a satisfactory occlusion over time. Over the years, the WEB evolved into a single layer device with a progressive lower profile now suitable for 0.017-inch catheters. This mechanical and technical progression has expanded the range of aneurysms that can be treated and procedures are technically easier with potentially lower complication rates. In a recent review by Lv et al (8), it was shown that studies with a higher proportion of WEB-DL treatments had higher morbidity figures.

Although we succeeded in extracting results for WEB-SL/S only, direct comparison with previous reviews is not possible because of heterogeneity in reporting and wide confidence intervals. Adequate occlusion rate for WEB SL/S on last follow-up was 83.3% (613/736; 95%CI 80.4-85.8%) and was in the same range as in the reviews by Lv [8] (81% (95%CI 76-85%) and Tau [7] (81% (95%CI, 73%–88%). In a recent meta-analysis of coiling of wide-necked bifurcation aneurysms with or without stenting [23], long-term adequate occlusion rate was with 71.9% remarkably lower but confidence intervals were still overlapping. The retreatment rate of WEB SL/S treated aneurysms in the current study was 8.4% (95%CI 6.2-11.4%). This is in the same range as the 5.2% (95% CI, 1.9%-8.4%) reported for (stent-assisted) coiling (24).

In the current study, cumulative morbidity for WEB SL/S was 2.85 % (27/949, 95%CI 1.95-4.12%) and mortality 0.93% (9/963, 95%CI 0.46-1.80%). This was not different from the review by Lv [8] (morbidity 3% (95% CI, 1-4%) and mortality 2% (95% CI, 1-3%)).

An advantage of WEB treatment for wide-neck aneurysms over stent-assisted coiling is that periprocedural and prolonged dual antiplatelet therapy is not necessary. This is in particular advantageous in the setting of ruptured wide-neck aneurysms. With stent-assisted coiling and anticoagulation, complications are higher than with simple coiling with more hemorrhagic and ischemic complications and higher mortality, especially in ruptured aneurysms [24-28]. Even though anti-platelet medication is not recommended for WEB treatment, in this review anti-coagulation protocol varied widely between studies and between ruptured versus unruptured aneurysms. Most operators used periprocedural single or dual antiplatelet therapy in unruptured aneurysms as a preventive measure with the possible use of a stent as a bailout with protrusion of the WEB over the parent vessel. When no stent was used, the antiplatelet medication was mostly discontinued. In the 3 studies [14,17,19] reporting on ruptured aneurysms only treated with WEB SL/S, antiplatelet medication was not used. In one study [17], heparinization was used while in the other 2 studies [14,19] only heparin in the pressure bags for flushing was administered.

The WEB device is a promising innovative endovascular treatment device originally designed for wide-neck and bifurcation aneurysms that are technically challenging for endovascular treatment. The WEB device has shown promising results in four multi-center prospective trials [10,13, 20,21]. With the progressive technical improvement of the WEB with lower profiles, smaller sizes, and low profile catheters, indications are no longer limited to wide-neck bifurcation aneurysms. Also, sidewall aneurysms and aneurysms on distal locations are now more and more treated with the WEB. Mid-term occlusion rates are in the same range as for stent-assisted coiling and complication rates tend to be lower, especially in ruptured aneurysms since the antiplatelet medication is not needed [24-28]. The imperative use of dual antiplatelet medication with the use of stents or extra-saccular flow diverters [29] imposes patients with ruptured aneurysms to a significant risk of rebleed and other hemorrhagic complications.

A limitation of this review is that most included studies were single- or multicenter cohort studies with self-reported data and short follow-up. However, the included studies provide the presently best available data. Long-term results remain unknown, and no direct comparison has been made with currently available treatment alternatives such as stent-assisted coiling, flow diversion or clipping. In the future, well-designed studies are necessary to determine the true added value of treating intracranial aneurysms with a WEB device.

References

1. Rosenwasser RH, Chalouhi N, Tjoumakaris S, Jabbour P. Open vs endovascular approach to intracranial aneurysms. Clin Neurosurg 2014;61:121-129
2. van Gijn J, Kerr RS, Rinkel GJ. Subarachnoid haemorrhage. Lancet 2007;369:306-318
3. Li H, Pan R, Wang H, Rong X, Yin Z, Milgrom DP, et al. Clipping versus coiling for ruptured intracranial aneurysms: a systematic review and meta-analysis. Stroke 2013;44:29-37
4. Algra AM, Lindgren A, Vergouwen MDI, Greving JP, van der Schaaf IC, van Doormaal TPC, Rinkel GJE. Procedural clinical complications, case-fatality risks, and risk factors in endovascular and neurosurgical treatment of unruptured intracranial aneurysms: A systematic review and meta-analysis. JAMA Neurol 2018 Dec 28. doi: 10.1001/jamaneurol.2018.4165. [Epub ahead of print]
5. Armoiry X, Turjman F, Hartmann DJ, et al. Endovascular treatment of intracranial aneurysms with the WEB device: A systematic review of clinical outcomes. AJNR Am J Neuroradiol 2016; 37: 868–872
6. Asnafi S, Rouchaud A, Pierot L, et al. Efficacy and safety of the Woven EndoBrigde (WEB) device for the treatment of intracranial aneurysms: a systemic review and meta-analysis. AJNR Am J Neuroradiol 2016;37:2287-92
7. Tau N, Sadeh-Gonik U, Aulagner G, Turjman F, Gory B, Armoiry X. The Woven EndoBridge (WEB) for endovascular therapy of intracranial aneurysms: Update of a systematic review with meta-analysis Clin Neurol Neurosurg 2018;166:110-115
8. Lv X, Zhang Y, Jiang W. Systematic review of Woven EndoBridge for wide-necked bifurcation aneurysms: Complications, adequate occlusion rate, morbidity, and mortality. World Neurosurg 2018;110:20-25
9. Moher D, Liberati A, Tetzlaff J, Altman DG, Group P. Preferred reporting items for systematic reviews and meta-analyses: the PRISMA statement. Ann Intern Med 2009;151:264-269. W264
10. Arthur AS, Molyneux A, Coon AL, Saatci I, Szikora I, Baltacioglu F, Sultan A, Hoit D, Delgado Almandoz JE, Elijovich L, Cekirge S, Byrne JV, Fiorella D; WEB-IT Study investigators. The safety and effectiveness of the Woven EndoBridge (WEB) system for the treatment of wide-necked bifurcation aneurysms: final 12-month results of the pivotal WEB Intrasaccular Therapy (WEB-IT) Study. J Neurointerv Surg 2019 Apr 16[Epub ahead of print]
11. Ambrosi PB, Gory B, Sivan-Hoffmann R, Riva R, Signorelli F, Labeyrie PE, et al. Endovascular treatment of bifurcation intracranial aneurysms with the WEB SL/SLS: 6-month clinical and angiographic results. Interv Neuroradiol 2015;21:462-469
12. Behme D, Berlis A, Weber W. Woven EndoBridge intrasaccular flow disrupter for the treatment of ruptured and unruptured wide-neck cerebral aneurysms: report of 55 cases. AJNR Am J Neuroradiol 2015;36:1501-1506

13. Caroff J, Mihalea C, Klisch J, Strasilla C, Berlis A, Patankar T, et al. Single-layer webs: intrasaccular flow disrupters for aneurysm treatment-feasibility results from an European study. AJNR Am J Neuroradiol 2015;36:1942-1946
14. Da Ros V, Bozzi A, Comelli C et al. Ruptured intracranial aneurysms treated with Woven EndoBridge intrasaccular flow disruptor: A multicenter experience. World Neurosurg 2019;122:e498-e505
15. Clajus C, Strasilla C, Fiebig T, et al. Initial and mid-term results from 108 consecutive patients with cerebral aneurysms treated with the WEB device. J NeuroIntervent Surg 2017;9:411–417.
16. Popielski J, Berlis A., Weber W, Fisher S. Two-center experience in the endovascular treatment of ruptured and unruptured intracranial aneurysms using the WEB device: A retrospective analysis. AJNR Am J Neuroradiol 2018;39:111-117
17. Raj R, Rautio R, Pekkola J, et al. Treatment of ruptured intracranial aneurysms using the Woven EndoBridge device: A two-center experience. World Neurosurg 2019;123: e709-e716
18. van Rooij SB, van Rooij WJ, Peluso JP, Sluzewski M. The Woven EndoBridge (WEB) as primary treatment for unruptured intracranial aneurysms. Interventional Neuroradiology 2018;24:475-481
19. van Rooij SB, van Rooij WJ, Peluso JP, et al. WEB treatment of ruptured intracranial aneurysms: A single-center cohort of 100 patients. AJNR Am J Neuroradiol 2017;38:2282-87
20. Lawson A, Molyneux A, Sellar R, et al. Safety results from the treatment of 109 cerebral aneurysms using the Woven EndoBridge technique: preliminary results in the United Kingdom. J Neurosurg 2018;128:144-153
21. Pierot L, Moret J, Barreau X et al. Safety and efficacy of aneurysm treatment with WEB in the cumulative population of three prospective, multicenter series. J Neurointerv Surg 2018;10:553-559
22. Khalid Z, Sorteberg W, Nedregaard B, Sorteberg A. Efficiency and complications of Woven EndoBridge (WEB) devices for treatment of larger, complex intracranial aneurysms-a single-center experience. Acta Neurochirurgica 2019;161:393-401
23. Zhao B, Yin R, Lanzino G, et al. Endovascular coiling of wide-neck and wide-neck bifurcation aneurysms: A systematic review and meta-analysis. AJNR Am J Neuroradiol 2016;37:1700-5
24. Zhao B, Tan X, Yang H, et al. Stent-assisted coiling versus coiling alone of poor-grade ruptured intracranial aneurysms: a multicenter study. J Neurointerv Surg 2017;9:165-168
25. Bechan RS, Majoie CB, Sprengers ME et al. Stent-assisted coil embolization of intracranial aneurysms: complications in acutely ruptured versus non-ruptured aneurysms. AJNR Am J Neuroradiol 2016;37:502-7
26. Phan K, Huo YR, Jia F, et al. Meta-analysis of stent-assisted coiling versus coiling-only for the treatment of intracranial aneurysms. J Clin Neurosci 2016;31:15-22

27. Zhang X, Zuo Q, Tang H, et al. Stent assisted coiling versus non-stent assisted coiling for the management of ruptured intracranial aneurysms: a meta-analysis and systematic review. J Neurointerv Surg 2019;11:489-496
28. Feng MT, Wen WL, Feng ZZ, et al. Endovascular embolization of intracranial aneurysms: To use stent(s) or not? Systematic Review and Meta-analysis. World Neurosurg 2016;93:271-8
29. Ten Brink MF, Jäger M, de Vries J, et al. Flow diversion for acutely ruptured aneurysms. J Neurointerv Surg 2019 Aug 24 [Epub ahead of print]
30. Goertz L, Liebig T, Siebert E, et al. Low-profile intra-aneurysmal flow disruptor WEB 17 versus WEB predecessor systems for treatment of small intracranial aneurysms: Comparative analysis of procedural safety and feasibility. AJNR Am J Neuroradiol 2019 Sept 5 [Epub ahead of print]
31. Maurer C, König I, Berlis A, et al. Two-center experience in the endovascular treatment of intracranial aneurysms using the Woven EndoBridge 17 device including midterm follow-up results: A retrospective analysis. AJNR Am J Neuroradiol 2019;40:1517-22

Reference	study design	# patients	# Aneurysms treated	# ruptured aneurys	aneurysm type	successfull WEB placement	WEB DL	WEB SL/S	additional devices	anticoagulation protocol	thrombo-embolic complications	other complications	morbidity	mortality	length fu imaging	complete occlusion at fu	neck remnant at fu	adequate occlusion	aneurysm remnant at fu	retreatment at fu	(re)rupture
Popielski 2018 (16)	RMCS	101	102	37	wide neck	98	0	98	15	ASA/clopidogrel	4	1 rupture	4 of 98	1 of 98	median 3.5 mo	47/78	16/78	63/78	15/78	10/78	0
Da Ros 2013 (14)	RMCS	33	NS	33	wide neck	33	0	33	2	none	2	2 rupture 5 protrusion	1 of 33	4 of 33	mean 14 mo	7/21	8/21	15/21	6/21	NS	0
van Rooij 2017 (19)	PCS	100	NS	100	all	100	0	100	2	none	9	1 rupture	3 of 100	1 of 100	3 mo	54/74	17/74	71/74	3/74	2/74	0
van Rooij 2018 (18)	PCS	51	NS	0	all	59	0	59	4	heparin	0	1 protrusion	1 of 59	0 of 59	3 mo	41/57	12/57	53/57	4/57	3/57	0
Lawson 2018 (20)	PMCS	109	109	18	wide neck	104	57	47	NS	various	4	NS	5 of 47	1 of 47	NS	NS	NS	NS	NS	NS	1
Pierot 2018 (21)	PMCS	168	169	14	bifurcation	163	78	85	12	various	9	1 rupture	2 of 85	0 of 85	12 mo	43/81	21/81	64/81	17/81	NS	0
Raj 2019 (17)	RMCS	33	NS	33	wide neck	33	0	33	1	heparin	3	0	0 of 33	0 of 33	6 mo	21/26	4/26	25/26	1/26	2/26	0
Ambrosi 2015 (11)	PCS	10	10	0	wide neck	8	0	8	0	heparin/aspirin	0	0	0 of 8	0 of 8	6 mo	2/8	5/8	7/8	1/8	0/8	0
Behme 2015 (12)	RMCS	52	55	14	all	51	28	23	NS	ASA/clopidogrel	0	1 rupture	1 of 23	0 of 23	3 mo	NS	NS	15/23	NS	NS	NS
Clajus 2017 (15)	RCS	108	114	47	wide neck	110	49	61	NS	various	2	0	0 of 61	0 of 61	mean 13.4 mo	36/51	6/51	42/51	9/51	7/51	1
Arthur 2019 (10)	PMCS	150	148	9	wideneck bifurcation	148	0	148	0	various	7	1 parenchymal hemorrhage	1 of 147	0 of 147	12 mo	77/143	44/143	121/143	22/143	8/143	0
Caroff 2015 (13)	PMCS	90	98	33	wideneck bifurcation	93	0	93	12	various	6	2 arterial occlusion, 1 perforation, 4 hemorrhage	6 of 93	2 of 93	mean 3,3 mo	NS	NS	45/69	24/69	NS	1
Khalid 2015 (22)	RCS	16	16	3	large wide neck	16	3	13	2	ASA/heparin	0	parenchymal hematoma, drain hematoma, seizure/infarct	NS	0 of 13	0.1-4 years	9/13	2/13	11/13	2/13	6/13	0
Maurer 2019 (31)	RMCS	117	127	29	wide neck	124	0	124	12	various	5	hemorrhage	2 of 124	0 of 124	3 mo	70/92	11/92	81/92	11/92	NS	NS
Goertz 2019* (30)	RMCS	38	38	NS	wide neck	38	0	38	2	various	3	1 rupture, 1 hemorrhage	1 of 38	0 of 38	NA	NA	NA	NA	NA	NA	NA

Table
Study Characteristics

ASA = Acetyl Salicyl Acid
NS = Not Specified
NA = Not Applicable
fu = follow-up
mo = months

RMCS = Retrospective Multicenter Cohort Study
PMCS = Prospective Multicenter Cohort Study
RCS = Retrospective Cohort Study
PCS = Prospective Cohort Study

* only WEB 17

CHAPTER

10

General discussion and future directions

General discussion and future directions

Advances in imaging

The introduction of 3D Rotational Angiography in the late nineties of the last century was a diagnostic revolution and provided new possibilities and insights in both diagnostic and therapeutic angiographic techniques. For the first time, it was possible to have a realistic 3D image of the cerebral vessels that could be freely rotated in any desired projection. This was particularly useful in the treatment of intracranial aneurysms. With the endovascular treatment of intracranial aneurysms, the most important issue is the exact delineation of the aneurysm neck to prevent coil placement outside the aneurysm in the parent vessel. In the era of 2D imaging, many projections were necessary to evaluate the neck of the aneurysm. Despite many projections, one could never be certain of the best working projection. With 3D angiography, after only one rotational run finding the best working projection was easy and definitive. Moreover, the computer of the workstation allowed many post-processing items such as several steps in resolution and magnification, the exact measurement of vessels and aneurysms and computer simulation of implanting devices such as stents and flow-diverters. The new 3D angiography provided far more accurate images of the cerebral vessels and vascular pathology such as aneurysms. Even aneurysms smaller than one millimeter could be easily detected. Because of the detailed imaging, also variations and anomalies of the cerebral vessels, that were previously known from surgical and anatomical studies but rarely seen on angiography, could now be easily depicted. In fact, with 3D angiography as a new gold standard current knowledge about incidence and prevalence of aneurysms and anatomical variants had to be revisited. Also, comparative studies using 2D imaging as a golden standard needed an update.

In a comparative study of 3D angiography versus 2D angiography in 350 patients with intracranial aneurysms 27 of 94 aneurysms (29%) additional to the target aneurysms were missed. The mean size of the missed aneurysms was 1.94 mm with a range of 0.5 – 4 mm (1).

This study demonstrated the diagnostic superiority of 3D angiography over 2D angiography.

At the beginning of the century, CT angiography was increasingly used as the primary diagnostic modality in patients with suspected intracranial aneurysms. At some institutions, CT angiography had even replaced angiography in the preoperative evaluation of patients with intracranial aneurysms. However, most studies on the clinical and diagnostic value of CT angiography were based on comparison with 2D angiography. Thus, it was plausible that the diagnostic accuracy of CTA was overrated. Therefore, we wanted to evaluate the impact of 3D angiography on the diagnosis of aneurysms and other vascular disorders and variations in patients with SAH. Data were collected from March 2013 – June 2014 of 179 consecutive patients with brain CT angiography performed for intracranial hemorrhage and suspected aneurysms or other vascular causes of this

hemorrhage. 3D angiography of all cerebral vessels was performed in 139 patients, mostly under general anesthesia preceding endovascular treatment. These 3D angiographic data were used as a reference to assess the clinical value of CT angiography in patients with SAH. The most important finding was that with CT angiography, all 5 non-aneurysmal causes of SAH (micro AVM, arterial dissections and reversible vasoconstrictions syndrome) were missed. CT angiography performance was poor in aneurysms ≤ 3 mm. Of the ruptured aneurysms, a quarter was ≤ 3 mm and of additional aneurysms, three quarters were ≤ 3 mm. With CT angiography, one in ten ruptured aneurysms and the majority of additional aneurysms were missed. This makes CT angiography of limited value in de diagnostic workup of patients with suspected intracranial aneurysms or other vascular pathology.

With 3D angiography, anatomical variations, mostly occult on 2D angiography, could be easily depicted for the first time. Fenestrations of cerebral arteries were commonly seen at surgery but hardly reported on 2D angiography. To assess the frequency and locations of fenestrations of cerebral vessels we evaluated 208 3D angiography datasets that were made between June 2004 and October 2008. Most patients had 3D angiography of only 1 or 2 vessels. Since an association of fenestrations with aneurysms is suggested in many studies, in patients with one or more aneurysms, we noted the relation of fenestrations with aneurysms. Surgical and anatomical studies suggested that fenestrations of intracranial arteries occur commonly, especially in the anterior communicating artery complex. With 2D angiography, demonstration of fenestration is exceptional. Many fenestrations are only visible from specific viewing angles that are usually not available on 2D angiography. In our dataset, 61 fenestrations were demonstrated in 59 of 208 patients (28%). Fenestrations were more common in the anterior than in the posterior circulation and the most common location was the anterior communicating artery. A definite relationship between fenestrations and aneurysms could not be concluded. In a later study, we used the dataset obtained between March 2013 and June 2014 with 140 patients with 3D angiography of all cerebral vessels (2), allowing a more accurate assessment of the incidence of fenestrations of intracranial vessels than in the previous study. In 33 of 140 patients (24%), 45 fenestrations were detected, again with the anterior communicating artery as the most common location (69%). Although 14 of 45 fenestrations were related to an aneurysm, no relation between fenestrations and aneurysms could be established. This study confirmed that in about a quarter of patients with suspected intracranial aneurysms, fenestrations of intracranial arteries can be detected.

The dataset obtained between March 2013 and June 2014 and expanded until April 2015, was used to revise the current knowledge about hospital demographics of patients with subarachnoid hemorrhage. Hospital demographics were dramatically changed in the last two decades. Implementation of 3D angiography resulted in the detection of more and smaller ruptured and additional unruptured aneurysms. Endovascular techniques for the treatment of intracranial aneurysms allowed more patients to be treated than in the era of surgical clipping. In 197 of 220 patients with an aneurysmal bleeding pattern a

cause of the bleeding was found, in 195 this was a ruptured aneurysm. On the other hand, in 23 of 204 patients (11%) with an aneurysmal bleeding pattern and 3D angiography performed no cause of SAH was found, not even after repeated 3D angiography. Multiple aneurysms were found in 72 of 204 patients (35%) with an aneurysmal bleeding pattern. Of 177 patients that were treated, 147 (83%) were treated endovascular and 30 (17%) were clipped. Rules of thumb for general practice from this study were as follows:

- 70% of patients with SAH admitted to the Elisabeth Hospital Tilburg had a ruptured aneurysm.
- 14% of patients with SAH had a perimesencephalic bleeding pattern and no aneurysm.
- 10% of patients with an aneurysmal bleeding pattern on CT did not have an aneurysm.
- In half of the patients with aneurysmal SAH and negative 3D angiography, repeat 3D angiography disclosed an aneurysm.
- One-third of patients with SAH had multiple aneurysms.
- 90% of ruptured aneurysms were treated.
- Over 80% of treated aneurysms are treated with endovascular techniques.
- Most clipped aneurysms were wide-necked anterior communicating- or middle cerebral artery aneurysms.

Future directions in imaging

The addition of the 3rd dimension in angiographic imaging was a major step forward. A rational next step would be to use this 3D imaging for the implementation of virtual reality in the treatment of vascular disorders. In a 3D dataset of the head obtained with rotational angiography, MRI and CT, the visualization of added catheters and devices would be in a virtual environment with infinite viewing angles at any time. Changes in position and location of catheters and devices can be monitored with pulsed fluoroscopy in 2 directions. Insertion and manipulation of catheters and devices will be done with robotic assistance (3). In this way, the operator can be independent of the physical location and highly trained experts from all over the world can be consulted for difficult cases. In individual cases, the intended endovascular treatment can be largely simulated beforehand and the anatomical result can be predicted by the computer model. A large library of clinical cases, catheters and devices can be loaded in computer systems and used for training in a virtual setting, analogous on the use of flight simulators for airline pilots.

Future research and development should be aimed to realize these short term perspectives.

Advances in treatment

In patients with ruptured aneurysms with a wide neck, endovascular treatment is technically challenging. To prevent migration of inserted coils through the neck into the parent artery, an additional temporary balloon was developed in the early nineties of the last century. The use of the balloon made the procedure more complicated by the simultaneous use of 2 microcatheters. Moreover, the balloon had to be navigated across the neck of the aneurysm, often difficult and time-consuming handling. With advancing production techniques, flexible stents for neurovascular use became available. With the placement of a stent in the parent vessel before the aneurysm neck, a microcatheter for coiling could be placed through the mazes of the stent inside the aneurysm. An advantage is that placement of the stent and coiling can be done through the same microcatheter without the need for a second one. A major disadvantage of the stent is that it attracts blood platelets with the risk of thrombus formation and stent occlusion. Therefore, with the use of stents, longstanding antiplatelet medication is imperative. In patients with unruptured aneurysms, the antiplatelet medication poses a minor risk of bleeding complications. However, in the clinical setting of endovascular treatment of patients with ruptured aneurysms, the antiplatelet medication is a major issue. In many studies, it was shown that the use of antiplatelet medication in patients with ruptured aneurysms initiated both thromboembolic and hemorrhagic complications. In patients with intracranial hemorrhage, the endogenic coagulation system may be disturbed, further influenced by the antiplatelet medication. Despite the added anticoagulation medication, thrombo-embolic complications still occurred. Besides, rebleed from the coiled aneurysm was not infrequent, even in aneurysms that appeared completely occluded after coiling. Apparently, thrombosis of the aneurysm after coiling was delayed by the anticoagulation, resulting in rebleed. Because of the increased complications with the use of antiplatelet medication, the placement of stents in patients in the acute phase of subarachnoid hemorrhage is discouraged.

In 2014 we evaluated our results of stent-assisted coiling and found out that stenting in 45 acutely ruptured aneurysms resulted in permanent neurological deficit or death in 10 (22%), in 5 due to thromboembolic complications and 5 due to early rebleed in the postoperative period despite the aneurysms were adequately coiled (4). In February 2015, we found an alternative for stent-assisted coiling in the new generation WEB with a single layer and suitable for a 0.021 microcatheter. The WEB consists of a self-expanding, oblong or spherical braid of platinum-cored nitinol wires intended to implant inside the aneurysmal sac and can be electro thermally detached. Since its introduction in 2010, the WEB has evolved from a high profile dual-layer to a low-profile single layer construction that can be delivered through a 0.021-inch microcatheter in the sizes up to 7 mm. After proper training on flow models, the WEB was first used for wide-necked unruptured bifurcation aneurysms without supporting stents or balloons. Soon it became evident

that handling was straightforward and easy and that angiographic and clinical results of the early cases were good. Encouraged by the initial good results and the easy handling, the WEB soon became the device of choice in the treatment of intracranial aneurysms. Not only wide-necked bifurcation aneurysms but also small-necked and side-wall aneurysms were treated. Only shallow aneurysms were not suitable for the WEB. Since maximum WEB size is 11 mm, larger aneurysms cannot be treated with the device. In 2017, the WEB range was expanded with a low-profile version suitable for a 0.017-inch microcatheter, WEB 17. With WEB 17, it was easier to negotiate through tortuous vessels and also very small aneurysms of 2 mm or even smaller could be treated. Clinical and imaging results of all patients with endovascular treated aneurysms were prospectively entered into a database. These data were used for several studies.

Figure 1 is a graphic display of the use of the WEB, coils and additional supporting devices for endovascular treatment of intracranial aneurysms in the St Elisabeth Ziekenhuis in Tilburg in the period 2013-2018. From 2015 onwards, the WEB became the most applied device for the treatment of intracranial aneurysms and stents were hardly any more used.

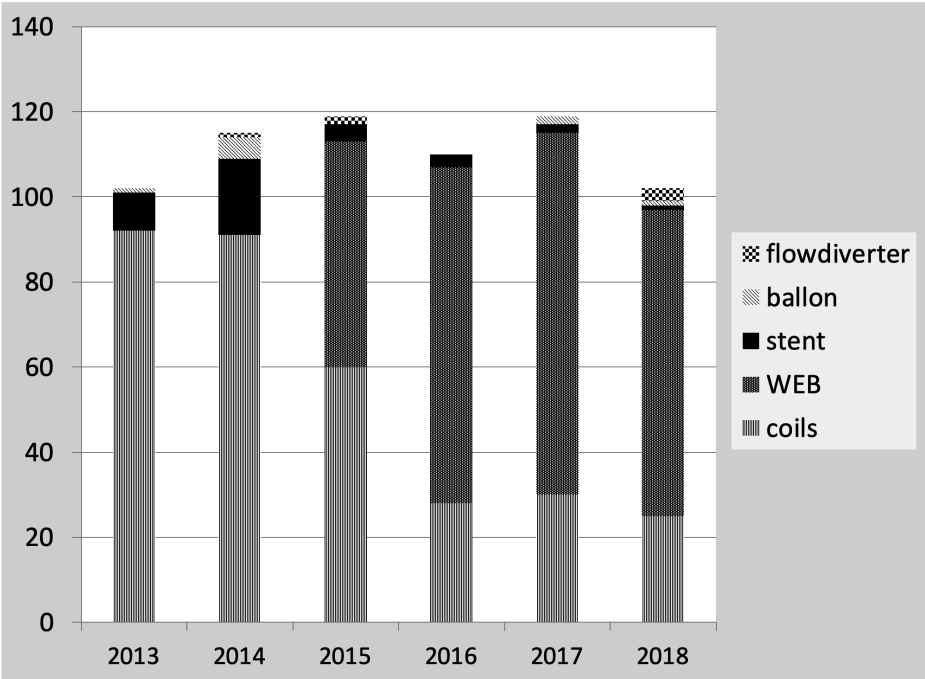

Figure 1. Evolution of devices used for endovascular treatment of intracranial aneurysms between 2013 and 2018 in the St Elisabeth Ziekenhuis Tilburg.

WEB procedure

The technique for the implantation of the WEB is as follows. A bi-axial approach is used. A short (11cm) 6Fr sheath is inserted and a Benchmark (Penumbra, Alameda, CA) guiding catheter positioned in the petrous carotid artery or V3 segment of the vertebral artery. Only with very tortuous vessels, a 90 cm long sheath (Neuron Max, Penumbra) is used with a 6 or 5Fr distal access-guiding catheter. Admitted patients receive subcutaneous Heparin 2,500 U twice daily as thrombotic prophylaxis. In patients with ruptured aneurysms, we use no other anticoagulation than the Heparin in the pressure bags for flushing (5000U/L). In patients with unruptured aneurysms, Heparin 2,500-5,000 bolus is given at the beginning of the procedure. Antiplatelet medication is not routinely administered. In case of a thromboembolic complication, removal of the thrombus is attempted with thrombosuction or a stent-retriever and for peripheral emboli, Tirofiban is used. When antiplatelet medication is considered necessary, Aspegic 500 mg is given intravenously later followed by Prasugrel or Plavix.

From 3D rotational images, the aneurysm is measured in 3 dimensions. Oversizing the WEB is imperative to assure anchoring the device on the aneurysm walls. In general, the WEB is oversized with 1-2 mm from the mean of the width of the aneurysm in 2 perpendicular planes. Since compression in diameter results in increased height of the WEB, the height is chosen 1-2mm less than the aneurysm height. In regularly shaped aneurysms, WEB sizing is straightforward. In irregularly shaped aneurysms, some spatial awareness is helpful. Throughout our experience with WEB sizing, we have a sizing failure rate of about 25% that has not improved over time.

In the sizes 4-7 mm there is overlap between the WEB 21 and 17 systems. In general, the WEB 17 performs better in tortuous and difficult anatomy and WEB 21 is more stable. Our personal preference is WEB 17 in the smallest sizes 3-4 mm and WEB 21 in the larger sizes 5-8 mm.

The VIA 17 and 21 microcatheters are specifically developed for the WEB. These catheters can be steam shaped when necessary (about 1 in 10 in our practice) and are stable during WEB delivery. The technique of WEB implantation is as follows: the tip of the microcatheter is positioned in the dome of the aneurysm. Then, the first part of the WEB is slowly unsheathed by microcatheter withdrawal until half of the WEB is deployed. At that point, the WEB has become soft and puncture of the aneurysm wall with the distal marker has become highly unlikely. Next, the micro-catheter is slightly pushed forward to assure the WEB is in the fundus of the aneurysm. At this point, the WEB can be completely deployed by further retracting the microcatheter while keeping the WEB in place.

The position of the WEB is checked with an angiographic run. Sometimes a rotational angiographic run may be helpful to evaluate the WEB position in relation to the aneurysm neck and parent vessels. We never use VASO-CT for this purpose since this is time-consuming and we are somewhat afraid to recapture the WEB after several minutes have passed; possible thrombus formed inside the WEB may be fragmented and dispersed.

When a good WEB position is confirmed, the device is detached and the procedure terminated, despite the possible presence of some flow inside the WEB and aneurysm.

Additional coils are only rarely necessary to occlude (part of) the aneurysm. In most irregular shaped aneurysms, the WEB can be used to cork the neck. Parts of the aneurysm not covered with the WEB will thrombose anyway. A supporting balloon during WEB placement was never used.

Although the use of the WEB has some technical issues, these can readily be learned by anyone with some experience with endovascular aneurysm treatment. The procedure is more or less similar to simple coiling. Proper training on phantoms and proctoring of first cases can largely avoid a learning curve. First-time users can better start with simple aneurysms than with complex wide-necked aneurysms. Simple aneurysms can be wide-necked as long as there is sufficient height to accommodate oversizing in width. With growing confidence, more challenging aneurysms can be treated, sometimes surprisingly easy.

Imaging follow-up after WEB treatment

Since many aneurysms still show some filling immediately after WEB placement, initial occlusion rates as with coiling cannot be given. Angiography after 3 months is performed to confirm the absence of residual filling inside the WEB. Further follow-up is scheduled with 3T MRA. Since the WEB acts like a Faraday cage, with MRA, the possible residual flow may remain undetected. Fortunately, residual flow at 3 months is extremely rare. In our study, we showed that MRA can be used in the extended imaging follow-up after WEB placement in aneurysms that were adequately occluded at initial angiographic follow-up. The signal loss from the proximal marker in the WEB did not interfere with the diagnostic performance of MRA.

Clinical results of WEB treatment of intracranial aneurysms

Published results from the St Elisabeth Ziekenhuis in Tilburg with the WEB both for ruptured and unruptured aneurysms are good with a reopening/retreatment rate of 7%, about 95% overall adequate occlusion and no (re)bleeds during follow-up. There was only 1 procedural rupture without clinical sequelae. Most thrombo-embolic complications were due to catheterization and not to the WEB.

Clinical results have improved since the WEB replaced stent-assisted coiling, especially in ruptured aneurysms. The simple periprocedural anticoagulation protocol without antiplatelet medication is a great advantage and prevents hemorrhagic complications.

The WEB procedure is a single catheter treatment and usually straightforward and quick and can be used in the majority of intracranial aneurysms that are treated. In the St Elisabeth Ziekenhuis most aneurysms (about 70%) are treated with the WEB (Fig 1). Only large aneurysms and shallow aneurysms are treated otherwise. Stents and flow diverters are never used in ruptured aneurysms and only rarely in unruptured aneurysms (Fig 1).

Also in the meta-analysis comprising 963 aneurysms, clinical results in terms of adequate occlusion rates, complications, rebleeds, and retreatments at follow-up were in the same range as for simple coiling and better than for stent-assisted coiling in wide-necked aneurysms. In the St Elisabeth Ziekenhuis the WEB has rapidly gained popularity and largely replaced the use of coils, stents and flow diverters. The avoidance of dual anti-platelet medication is a big advantage over stents and flow diverters, resulting in fewer thrombo-embolic complications and fewer early rebleeds. The easy, quick and safe technique is a convincing advantage over balloon- or stent-assisted coil treatments.

Improvements and future perspectives

The development of the WEB is ongoing. More shallow sizes are being developed and experiments are done with changes in the WEB shape, for example, a hybrid version between SL and SLS. The larger WEB sizes 9-11 mm may become available in lower-profile suitable for a 0.027 instead of a 0.033 microcatheter. To reduce the proportion of wrong seizing of about 1 in 4, an automated 3D software program could be a valuable tool.

The WEB is now marketed as an expensive device, comparable to the price of stent-assisted coiling. With growing popularity, prices are likely to drop.

The WEB has the potential to replace coils for a large part. The simple technique in both small-necked and wide-necked aneurysms is appealing. In mid-2018, over 6000 WEBs have been implanted worldwide, the vast majority of those in Europe. In the USA, the FDA approved the device in January 2019. The extensive European experience with the WEB provides for a flying start in the USA. Approval of the WEB is still pending in many countries. Once available around the world, the WEB is likely to find its place for the next decades.

References

1. Van Rooij WJ, Sprengers ME, de Gast AN, Peluso JP, Sluzewski M. 3D rotational angiography: the new gold standard in the detection of additional intracranial aneurysms. AJNR Am J Neuroradiol 2008;29:976-979
2. Van Rooij SB, Bechan RS, Peluso JP, Sluzewski M, van Rooij WJ. Fenestrations of intracranial arteries. AJNR Am J Neuroradiol 2015;36:1167-1170
3. Britz GW, Tomas J, Lumsden A, et al. Feasibility of robotic-assisted neurovascular interventions: Initial experience in flow model and porcine model. J Neurosurg 2019;Apr 17 [Epub ahead of print]
4. Bechan RS, Sprengers ME, Majoie CB, et al. Stent-assisted coil embolization of intracranial aneurysms: complication in acutely ruptured versus unruptured aneurysms. AJNR Am J Neuroradiol 2016;37:502-7

Appendices

New Developments in Diagnosis and Treatment of Intracranial Aneurysms

Summary

In **Chapter 1** an introduction and outline of the thesis is provided.

In **Chapter 2** we provide an update of hospital demographics of patients with intracranial hemorrhage and suspected vascular disorders with 3D angiography as the golden standard.
Clinical outcome data were available for 284 patients over a time-span of 2 years. In patients with aneurysms, characteristics and mode of treatment were recorded. In 197 of 220 patients with an aneurysmal bleeding pattern a cause of the bleeding was found: 195 patients had a ruptured aneurysm (98%), 1 patient a micro AVM and 1 patient reversible vasoconstriction syndrome. Of 195 ruptured aneurysms, 6 were dissection aneurysms and 3 were AVM associated flow aneurysms. In 23 of 204 patients (11%) with an aneurysmal bleeding pattern and 3DRA performed no cause was found. In 8 of 9 patients (89%) with a positive lumbar puncture but negative CT, no cause was found.
Of 180 patients with a ruptured aneurysm eligible for treatment, 147 (82%) were treated endovascular and 30 (17%) were clipped. Of 204 patients with an aneurysmal bleeding pattern and 3DRA, 72 (35%) had multiple aneurysms. These 72 patients had altogether 117 additional aneurysms of which 24 (21%) were treated either by coiling or clipping.
This study provides robust data on hospital demographics of SAH in a neurosurgical referral center, based on CTA and 3D Rotational Angiography of all vessels. We found that new 3D imaging techniques provide more accurate diagnosis and endovascular treatment has largely replaced surgery.

Chapter 3 describes the diagnostic accuracy of CTA in the detection of intracranial aneurysms and other vascular disorders in consecutive patients with acute SAH in 179 patients. One hundred thirty-nine patients with acute SAH underwent CTA followed by 3DRA. We compared CTA with 3DRA of all cerebral vessels. In 118 of 139 patients (85 %), 3DRA diagnosed the cause of hemorrhage: 113 ruptured aneurysms, three arterial dissections, one micro-arteriovenous malformation (AVM), and one reversible vasoconstriction syndrome. On CTA, both observers missed all five non-aneurysmal causes of SAH. The sensitivity of CTA in depicting ruptured aneurysms was 0.88–0.91, and accuracy was 0.88–0.92. Of 113 ruptured aneurysms, 28 were ≤3 mm (25 %) and of 95 additional aneurysms, 71 were ≤3 mm (75 %). The sensitivity of depicting aneurysms ≤3 mm was 0.28–0.43. Of 95 additional aneurysms, the two raters missed 65 (68 %) and 58 (61 %). Sensitivity in detection was lower in aneurysms of the internal carotid artery than in other locations.

CTA had some limitations as a primary diagnostic tool in patients with SAH. All non-aneurysmal causes for SAH and one in ten ruptured aneurysms were missed. The performance of CTA was poor in aneurysms ≤3 mm. The majority of additional aneurysms were not depicted on CTA.

In **Chapter 4** we assess with 3DRA the prevalence and location of fenestrations of intracranial arteries and the relation with aneurysms in a cohort of 208 patients. In 59 of 208 patients, 61 fenestrations were detected (28%). Fenestrations were more frequent in the anterior than in the posterior circulation (23% versus 7%), and the most common location was the anterior communicating artery (Acoma) (43 of 61, 70%). The frequency of fenestrations in 185 patients with aneurysms was not different from the frequency in 23 patients without aneurysms. Of 220 aneurysms present in 208 patients, 10 aneurysms (4.5%) were located on a fenestration. Of 61 fenestrations, 51 (84%) were not associated with an aneurysm. A definite relationship between fenestrations and aneurysms cannot be concluded from our data.

Chapter 5 reports the clinical- and imaging results of 100 patients (71 women, mean age 59 years) with a ruptured aneurysm treated with the WEB regardless of aneurysm location or neck size. No supporting stents or balloons were used. The mean aneurysm size was 5.6 mm (range 3-13 mm) and 42 aneurysms were ≤4mm. Sixty-six aneurysms (66%) had a wide neck defined as ≥4 mm or dome-neck ratio ≤ 1.5. There was 1 procedural rupture without sequelae. In 9 patients (9%), thromboembolic complications occurred. One poor grade patient died, neurological deficits remained in 3. The overall treatment-related morbidity-mortality was 4% (4 of 100; 95% CI, 1.2%-10.2%). Of 80 eligible patients, 74 (93%) had 3 months' angiographic follow-up. Fifty-four aneurysms (73%) were completely occluded, 17 (23%) had a small neck remnant and 3 (4%) were incompletely occluded. One patient was additionally treated with a second WEB and in 2 patients additional treatment is scheduled. Overall reopening/retreatment rate was 6.8% (5 of 74, 95%CI 2.6-15.2%). There were no rebleeds during follow-up. WEB treatment of ruptured aneurysms is feasible, effective and safe. The WEB proved a valuable alternative to coils and it allowed us to refrain from the use of adjunctive stents and supporting balloons.

In **Chapter 6**, we evaluated the clinical and imaging results of the WEB as a primary treatment for 59 unruptured intracranial aneurysms. We treated all aneurysms suitable for the device, regardless of neck size and location. There were 15 men and 36 women with a mean age of 59 years. The mean aneurysm size was 7.0 mm (range 3-22 mm). Of 59 aneurysms, 45 (76%) had a wide neck defined as ≥4 mm or dome-neck ratio ≤ 1.5. No stents or supporting balloons were used.
The initial WEB position was judged good in all 59 unruptured aneurysms. One patient with a basilar tip aneurysm had a late thrombotic posterior cerebral artery occlusion

by a protrusion of the WEB over the artery. There were no procedural ruptures. Overall complication rate was 2.0% (1 of 51, 95%CI 0.01-11.3%). Imaging follow-up was available in 55 of 59 aneurysms (93%). At 3 months, 41 of 57 aneurysms (72%) were completely occluded, 12 (21%) had a neck remnant and 4 (7%) were incompletely occluded. WEB treatment is safe and effective in selected unruptured aneurysms suitable for the device, regardless of neck size or location. There was no need for supportive devices. In our opinion, the WEB is a valuable alternative to coils, especially in wide-necked aneurysms.

In **Chapter 7**, we present the first clinical and imaging results of the treatment of 46 ruptured and unruptured aneurysms with the new low-profile WEB 17. The WEB 17 was developed to improve technical performance in tortuous vasculature and for (very) small aneurysms. Between December 2016 and September 2017, 46 aneurysms in 40 patients were treated with the WEB 17. There were 6 men and 34 women, mean age 62 years (median 63, range 46-87). No supporting stents or balloons were used. Twenty-five aneurysms were ruptured (54%). The mean aneurysm size was 4.9 mm (median 5, range 2-7 mm). There were 2 thrombo-embolic procedural complications without clinical sequelae and no ruptures. Overall permanent procedural complication rate was 0% (0 of 40, 97.5%CI 0-10.4%).
Imaging follow-up at 3 months was available in 33 patients with 39 aneurysms (97.5% of eligible aneurysms). In one aneurysm the detached WEB was undersized and the remnant was additionally treated with coils after 1 week. This same aneurysm reopened at 3 months and was again treated with a second WEB. One other aneurysm showed persistent WEB filling at 3 months. Complete occlusion was achieved in 28 aneurysms (72%) and 9 aneurysms (23%) showed a neck-remnant. WEB 17 was safe and effective for both ruptured and unruptured aneurysms. The WEB 17 proved a valuable addition to the existing WEB size range, especially for very small aneurysms.

In **Chapter 8**, Magnetic Resonance Angiography (3T MRA) was used for mid-term follow-up of WEB-treated aneurysms that were adequately occluded at 3 months angiographic follow-up. Included were 52 patients with 53 aneurysms treated with the WEB between February 2015 and July 2016. There were 29 women and 23 men with a mean age of 60 years. The mean aneurysm size was 6.2 mm. 3T MRA follow-up was mean 19.6 months (median 18, range 18–36 months). One patient had an aneurysm remnant at 3 months' angiography that was additionally coiled and with stable complete occlusion at 18 months' 3T MRA follow- up. At three-month follow-up angiography, 44 aneurysms were completely occluded and eight had a neck remnant. At the latest 3T MRA, stable complete occlusion was present in 43 aneurysms and stable neck remnant in eight. One posterior cerebral artery (PCA) dissection aneurysm was stable at three and six months but was enlarged and reopened at 18 months, confirmed with angiography. Focal signal loss by the proximal marker of the WEB was apparent in four patients without compromising

diagnostic evaluation. WEB-treated aneurysms with adequate occlusion at three-month angiography remained stable during serial 3T MRA follow-up of 18–36 months. One PCA aneurysm reopened during the 6- to 18-month interval. Once the WEB-treated aneurysm is adequately occluded in the short term, later reopening is uncommon.

In **Chapter 9**, a systematic review and meta-analysis were presented to evaluate the outcomes of the new generation low-profile WEB Single Layer device for intracranial aneurysm treatment. Fifteen papers were identified reporting the use of WEB SL devices in 963 aneurysms, mostly wide-neck bifurcation aneurysms. Procedural aneurysm rupture was reported in 8 of 963 patients (0.83%; 95%CI 0.39-1.66%) and thromboembolic events in 54 of 963 patients (5.61%, 95CI 4.31-7.26%). Cumulative morbidity was 2.85 % (27/949, 95%CI 1.95-4.12%) and mortality 0.93% (9/963, 95%CI 0.46-1.80%). The overall rate of adequate aneurysm occlusion at last follow-up was 83.3% (613/736; 95%CI 80.4-85.8%). Retreatment was reported in 38 aneurysms in 8 studies with 450 aneurysms with follow-up (38/450; 8.4%, 95CI 6.2-11-4%). In 12 studies comprising 644 aneurysms with follow-up, rebleeds occurred in 3 patients in 3 studies with mean follow-up between 3.3 and 14.4 months (0.47%, 95%CI 0.09-1.43%). WEB SL is a promising new low profile device especially for wide-neck bifurcation aneurysms, both ruptured and unruptured. No antiplatelet medication is needed which is a great advantage, especially in ruptured aneurysms. Efficacy and safety compare favorably with (stent-assisted) coiling. However, no direct comparison with other treatments is available as yet.

In **Chapter 10**, the findings of this thesis are generally discussed and possible future directions are outlined.

New Developments in Diagnosis and Treatment of Intracranial Aneurysms

Nederlandse samenvatting

In **Hoofdstuk 1** wordt een introductie en opzet van dit proefschrift gegeven.

In **Hoofdstuk 2** geven we een update over de ziekenhuis demografie van patiënten met een intracraniële bloeding waarbij een vasculaire oorzaak wordt vermoed en met 3D angiografie als gouden standaard. Klinische uitkomstdata waren bekend van 284 patiënten over een periode van 2 jaar. Door de komst van nieuwe 3D onderzoekstechnieken is het mogelijk een meer accurate diagnose te stellen en heeft endovasculaire behandeling vaak de voorkeur boven chirurgie. Bij patiënten met een aneurysma werden de karakteristieken en de behandelingsmethode ervan genoteerd. Bij 197 van 220 patiënten met een aneurysmaal bloedingspatroon werd een oorzaak voor de bloeding gevonden: 195 patiënten hadden een geruptureerd aneurysma (98%), 1 patiënt had een micro-AVM en 1 patiënt had het reversibel vasoconstrictie syndroom. Van 195 geruptureerde aneurysma's waren er 6 dissecties en 3 waren flow aneurysma's bij een AVM. Bij 23 van 204 patiënten (11%) met een aneurysmaal bloedingspatroon en met 3DRA verricht werd geen oorzaak gevonden. Bij 8 van 9 patiënten (89%) met positieve liquor test en negatieve CT werd geen oorzaak gevonden.
Van de 180 patiënten met een geruptureerd aneurysma die in aanmerking kwamen voor behandeling werden 147 (82%) endovasculair behandeld en 30 (17%) werden geclipt. Bij 204 patiënten met een aneurysmaal bloedingspatroon en 3DRA verricht hadden 72 (35%) multiple aneurysma's. Deze 72 patiënten hadden samen 117 additionele aneurysma's waarvan er 24 (21%) werden behandeld met coilen of clippen.
Deze studie geeft betrouwbare gegevens over ziekenhuis demografie van subarachnoïdale bloeding in een neurochirurgisch referentie centrum, gebaseerd op CTA en 3DRA van alle vaten. De nieuwe 3D technieken leiden tot meer accurate diagnoses en de endovasculaire behandeling van aneurysma's heeft voor een groot deel chirurgie vervangen.

Hoofdstuk 3 beschrijft de diagnostische waarde van CT angiografie bij het detecteren van intracraniële aneurysma's en andere intracraniële vasculaire afwijkingen bij 179 opeenvolgende patiënten met een acute subarachnoïdale bloeding. Honderd negenendertig patiënten met een SAB ondergingen CTA gevolgd door 3DRA. We hebben de uitkomsten van CTA met 3DRA van alle intracraniële bloedvaten vergeleken. Bij 118 van 139 patiënten (85%) werd de oorzaak voor de bloeding gevonden met 3DRA: 113 geruptureerde aneurysma's, 3 dissecties, 1 micro-AVM en 1 reversibel vasoconstrictie syndroom. Met CTA misten beide waarnemers alle 5 niet-aneurysmale oorzaken voor de SAB. Sensitiviteit van CTA voor detectie van geruptureerde aneurysma's was 0,88-0,91 en accuratesse was 0,88-0,92. Van de 113 geruptureerde aneurysma's waren er 28 ≤3

mm (25 %) en van 95 additionele aneurysma's waren er 71 ≤3 mm (75 %). Sensitiviteit voor detectie van aneurysma's ≤3 mm was 0,28–0,43. Van de 95 additionele aneurysma's werden er door de 2 waarnemers 65 (68%) en 58 (61%) gemist. Sensitiviteit voor detectie was lager bij aneurysma's van de arteria carotis interna dan voor andere locaties.
CTA had beperkingen als primair diagnostisch onderzoek bij patiënten met een SAB. Alle niet-aneurysmale oorzaken voor een SAB en 10% van de geruptureerde aneurysma's werden gemist op CTA. Kleine aneurysma's waren moeilijk detecteerbaar met CTA en de meeste additionele aneurysma's werden gemist.

In **Hoofdstuk 4** hebben we de prevalentie en locatie van fenestraties van de intracraniële bloedvaten en een mogelijke relatie met aneurysma's onderzocht in een cohort van 208 patiënten. Bij 59 van de 208 patiënten werden 61 fenestraties gedetecteerd (28%). Fenestraties kwamen vaker voor in de anterieure dan in de posterieure circulatie (23% versus 7%) en de meest voorkomende locatie was de arteria communicans anterior (43 van 61, 70%). Het voorkomen van fenestraties bij 185 patiënten met een aneurysma verschilde niet van het voorkomen bij 23 patiënten zonder aneurysma. Van de 220 aneurysma's bij 208 patiënten, waren 10 aneurysma's (4.5%) gelokaliseerd op een fenestratie. Van de 61 fenestraties waren er 51 (84%) niet geassocieerd met een aneurysma. Een definitieve relatie tussen fenestraties en aneurysma's kon door onze gegevens niet worden vastgesteld.

Hoofdstuk 5 beschrijft de klinische en beeldvormende uitkomsten van 100 patiënten met een geruptureerd aneurysma die met de WEB behandeld zijn ongeacht de locatie of de nekwijdte van het aneurysma. Er werden geen ondersteunende stents of ballonnen gebruikt. De gemiddelde grootte van het aneurysma was 5.6 mm (spreiding 3-13 mm) en 42 aneurysma's waren ≤4mm. Zes-en-zestig aneurysma's hadden een wijde nek gedefinieerd als ≥4 mm of fundus-nek ratio ≤ 1,5mm. Er was 1 procedurele ruptuur zonder klinische gevolgen. Bij 9 patiënten (9%) traden thrombo-embolische complicaties op. Een patiënt in slechte klinische toestand overleed en 3 patiënten hadden blijvende neurologische schade. Behandeling morbiditeit/mortaliteit was 4% (4 van 100; 95% CI, 1,2%-10,2%). Van de 80 patiënten die in aanmerking kwamen voor angiografisch vervolg onderzoek na 3 maanden werd dit uitgevoerd bij 74 (93%). Vier-en-vijftig aneurysma's (73%) waren volledig afgesloten, bij 17 (23%) was er een kleine nekrest en 3 (4%) waren niet compleet afgesloten. Een patiënt werd aanvullend behandeld met een tweede WEB en 2 patiënten staan gepland voor tweede behandeling. Vijf van de 74 aneurysma's (6,8%, 95%CI 2,6-15,2%) heropenden of werden aanvullend behandeld tijdens de vervolgperiode. WEB behandeling van geruptureerde aneurysma's is uitvoerbaar, effectief en veilig. De WEB bleek een goed alternatief voor coiling in veel geruptureerde aneurysma's en het gebruik van aanvullende stents en ballonnen was niet noodzakelijk.

In **Hoofdstuk 6** evalueren we de klinische en beeldvormende uitkomsten van de WEB als primaire behandeling bij 59 ongeruptureerde intracraniële aneurysma's. We behandelden alle ongeruptureerde aneurysma's die geschikt waren voor de WEB, ongeacht de nekwijdte en locatie. Er waren 15 mannen en 36 vrouwen met een gemiddelde leeftijd van 59 jaar. De gemiddelde grootte van het aneurysma was 7,0 mm met een spreiding van 3-22 mm. Van de 59 aneurysma's hadden er 45 (76%) een wijde nek gedefinieerd als ≥4 mm of fundus-nek ratio ≤ 1,5mm. Er werden geen ondersteunende stents of ballonnen gebruikt. Initiële WEB positie werd als goed beoordeeld bij alle 59 ongeruptureerde aneurysma's. Complicatie percentage was 2.0% (1 van 51, 95% CI 0,01-11,3%). Angiografisch vervolgonderzoek na 3 maanden toonde dat 41 van de 57 aneurysma's (72%) compleet waren afgesloten, 12 (21%) hadden een nekrest en 4 (7%) waren incompleet afgesloten. WEB behandeling is veilig en effectief in geselecteerde niet-geruptureerde aneurysma's die geschikt zijn voor deze techniek, ongeacht nek wijdte en locatie. Ondersteunende stents of ballonnen waren niet nodig. De WEB is een waardig alternatief voor coils in niet geruptureerde aneurysma's, speciaal voor aneurysma's met een wijde nek.

In **Hoofdstuk 7** worden de eerste klinische en beeldvormende resultaten gepresenteerd van de behandeling van 46 geruptureerde en ongeruptureerde aneurysma's met de nieuwe WEB 17 met een laag profiel. De WEB 17 is ontwikkeld om de technische uitvoering te verbeteren in tortueuze vaten en voor (hele) kleine aneurysma's. Van december 2016 tot september 2017 werden 46 aneurysma's bij 40 patiënten behandeld met de WEB 17. Er waren 6 mannen en 34 vrouwen met een gemiddelde leeftijd van 62 jaar met een spreiding van 43-87 jaar. Ondersteunende stents of ballonnen werden niet gebruikt. Vijf-en-twintig aneurysma's waren geruptureerd (54%). Gemiddelde grootte van het aneurysma was 4,9 mm met een spreiding van 2-7 mm. Er waren 2 thrombo-embolische complicaties zonder klinische gevolgen en er waren geen procedurele rupturen. Het permanente complicatie percentage was 0% (0 of 40, 97,5%CI 0-10,4%). Angiografisch vervolg onderzoek was beschikbaar bij 33 patiënten met 39 aneurysma's (97,5%). Bij 1 aneurysma was de WEB te klein en het restant van het aneurysma werd aanvullend behandeld met coils na 1 week. Dit zelfde aneurysma heropende na 3 maanden en werd opnieuw behandeld met een tweede WEB. Een ander aneurysma toonde persisterende contrast vulling van de WEB na 3 maanden. Complete occlusie werd behaald bij 28 aneurysma's (72%) en 9 aneurysma's (23%) hadden een nekrest. De WEB 17 was veilig en effectief voor behandeling van zowel geruptureerde als ongeruptureerde aneurysma's. De WEB 17 is een waardevolle aanvulling op de bestaande WEB 21, vooral voor hele kleine aneurysma's.

In **Hoofdstuk 8** gebruikten we Magnetische Resonantie Angiografie met 3 Tesla (3T MRA) voor middellange termijn vervolg onderzoek van aneurysma's die met de WEB waren behandeld en die adequaat waren afgesloten op angiografisch vervolg onderzoek na 3 maanden. Twee-en-vijftig patiënten met 53 WEB behandelde aneurysma's werden

geïncludeerd. Er waren 29 vrouwen en 23 mannen met een gemiddelde leeftijd van 60 jaar. De gemiddelde grootte van het aneurysma was 6,2 mm. 3T MRA vervolgduur was gemiddeld 19,6 maanden met een mediaan van 18 en een spreiding van 18-36 maanden. Een patiënt had een aneurysma rest bij angiografie na 3 maanden die aanvullend werd behandeld met coils en met volledige afsluiting op 3T MRA na 18 maanden. Bij vervolg angiografie na 3 maanden waren 44 aneurysma's volledig afgesloten en 8 hadden een nekrest. Op de laatst vervaardigde 3T MRA waren 43 aneurysma's volledig afgesloten en 8 hadden een stabiele nekrest. Een dissectie aneurysma van de arteria cerebri posterior was stabiel na 3 en 6 maanden maar was groter en heropend na 18 maanden, bevestigd met angiografie. Focaal signaal verlies bij de proximale marker van de WEB trad op bij 4 patiënten zonder nadelig effect op de diagnostische mogelijkheden. WEB behandelde aneurysma die adequaat waren afgesloten na 3 maanden bleven stabiel gedurende 3T MRA vervolgonderzoek van 18-36 maanden. Een dissectie aneurysma groeide en heropende gedurende het 6-18 maanden interval. Wanneer een WEB behandeld aneurysma adequaat is afgesloten op korte termijn is latere heropening ongebruikelijk.

In **Hoofdstuk 9** beschrijven we een systematische review en meta-analyse van de literatuur om de klinische uitkomsten te onderzoeken van patiënten met een intracranieel aneurysma die met de nieuwe generatie WEB Single Layer zijn behandeld. Vijftien studies werden geïncludeerd die het gebruik van de WEB SL beschreven in 963 aneurysma's met meestal een wijde nek en gelokaliseerd op een bifurcatie. Procedurele ruptuur van het aneurysma werd beschreven bij 8 van 963 patiënten (0,83%; 95%CI 0,39-1,66%) en thrombo-embolische complicaties bij 54 van 963 patiënten (5,61%, 95CI 4,31-7,26%). Cumulatieve morbiditeit was 2,85 % (27/949, 95%CI 1,95-4,12%) en mortaliteit 0,93% (9/963, 95%CI 0,46-1,80%). Het percentage aneurysma's met adequate afsluiting bij het laatste vervolgonderzoek was 83,3% (613/736; 95%CI 80,4-8,.8%). Herbehandeling werd beschreven bij 38 aneurysma's in 8 studies met 450 aneurysma's met vervolg onderzoek (38/450; 8,4%, 95CI 6,2-11,4%).In 12 studies met 644 aneurysma's trad een herbloeding op bij 3 patiënten in 3 studies met gemiddelde vervolg duur van 3,3 en 14,4 maanden (0,47%, 95%CI 0,09-1,43%). WEB SL is een veelbelovend behandel instrument met een laag profiel voor bifurcatie aneurysma's met een wijde nek, zowel geruptureerd als ongeruptureerd. Anti-aggregatie remmers zijn niet noodzakelijk hetgeen een groot voordeel is, vooral bij geruptureerde aneurysma's.
Effectiviteit en veiligheid zijn vergelijkbaar met (stent-geassisteerde) coiling. Er is echter nog geen directe vergelijking met andere behandelmethodes beschikbaar.

In **Hoofdstuk 10** worden de resultaten van dit proefschrift besproken en worden mogelijke toekomstige ontwikkelingen geschetst.

List of publications

1. **van Rooij SBT,** Bechan RS, van Rooij WJ, Sprengers ME. Current hospital demographics of subarachnoid hemorrhage based on CT Angiography and 3D Rotational Angiography in a neurosurgical centre. AJNR Am J Neuroradiol 2019;40:1013-1017
2. **van Rooij SB,** van Rooij WJ, Sluzewski M, Peluso JP. The Woven EndoBridge (WEB) for recurrent aneurysms: Clinical and imaging results. Interv Neuroradiol 2019;25:21-26
3. van Rooij WJ, **van Rooij SBT,** Kortman HG, Peluso JP. The Woven EndoBridge finally coming home across the Atlantic: What to expect? AJNR Am J Neuroradiol 2018;39:1964-1966
4. **van Rooij SB,** van Rooij WJ, Peluso JP, Sluzewski M. The Woven EndoBridge (WEB) as primary treatment for unruptured intracranial aneurysms. Interv Neuroradiol 2018;24:475-481
5. **van Rooij SB,** van Rooij WJ, Peluso JP, Sluzewski M, Kortman HG, Boukrab I, van Rooij WJ. Mid-term 3T-MRA follow-up of intracranial aneurysms treated with the Woven EndoBridge (WEB). Interv Neuroradiol 2018;24:601-607
6. **van Rooij SB,** Peluso JP, Kortman HG, van Rooij WJ. The new low-profile WEB 17 system for treatment of intracranial aneurysms: first clinical experiences. AJNR Am J Neuroradiol 2018;39:859-863
7. **van Rooij SBT,** van Rooij WJ, Peluso JP, Sluzewski M, Bechan RS, Kortman HG, Beute GN, van der Pol B, Majoie CB. WEB treatment of ruptured intracranial aneurysms: A single center cohort of 100 patients. AJNR Am J Neuroradiol 2017;38:2282-2287
8. Bechan RS, **van Rooij SB,** Sprengers ME, Peluso JP, Sluzewski M, Majoie CB, van Rooij WJ. CT Angiography versus 3D Rotational Angiography in patients with subarachnoid hemorrhage. Neuroradiology 2015;57:1239-1246
9. **van Rooij SB,** Bechan RS , Peluso JP, SLuzewski M, van Rooij WJ. Fenestrations of intracranial arteries. AJNR Am J Neuroradiol 2015;36:1167-1170
10. **van Rooij SB,** Bechan RS, Markenstein JE, Sluzewski M, van Rooij WJ. The donut sign: A new angiographic sign for partially thrombosed aneurysms with flow-induced intraluminal thrombus. Interv Neuroradiol 2014;20:55-59
11. van Rooij WJ, **van Rooij SB.** Endovascular treatment of traumatic pericallosal artery aneurysms. A case report. Interv Neuroradiol 2013;19:56-59
12. **van Rooij SB,** van Rooij WJ, Sluzewski M, Sprengers ME. Fenestrations of intracranial arteries detected with 3D Rotational Angiography. AJNR Am J Neuroradiol 2009;30:1347-1350
13. **van Rooij SB,** Sprengers ME, Daams J, Verbaan D, van Rooij WJ, Majoie CB. A systematic review and meta-analysis of Woven EndoBridge Single Layer for treatment of intracranial aneurysms. Interv Neuroradiol in press

Dankwoord

Iedereen die heeft bijgedragen aan de totstandkoming van dit proefschrift wil ik hartelijk bedanken. Een aantal mensen in het bijzonder:

Mijn hooggeleerde promotor, Prof. Dr. C.B.L.M. Majoie. Beste prof. Majoie, mede door uw vertrouwen in het onderwerp van mijn proefschrift is dit boekje tot stand gekomen. Uw uitgebreide kennis en ervaring heeft me erg geholpen. Ik kon altijd op een snelle reactie rekenen en ik waardeer uw flexibele houding als mijn tijd (mede) door de opleiding weer eens beperkt was. Dank voor uw doortastendheid en voor alle adviezen.

Mijn co-promotoren Dr. M.E.S. Sprengers en Dr J.P.P. Peluso. Beste Marieke en Jo, veel dank voor de tijd en inspanning die jullie hebben besteed aan het beoordelen en bekritiseren van mijn proefschrift.

De leden van de promotiecommissie wil ik bedanken voor het beoordelen van mijn proefschrift.

Mijn collega Dr. R.S. Bechan. Beste Ratna, ooit ben jij begonnen in het St. Elisabeth Ziekenhuis Tilburg met het opbouwen van onze database met gegevens van patiënten. Deze database werd de basis van onze proefschriften. Zie waar dat uiteindelijk toe heeft geleid! Eerst jouw promotie in 2016, straks zijn we allebei gepromoveerd. Dank voor de fijne samenwerking.

The representatives from MicroVention-Terumo, the manufacturer of the Woven EndoBridge, especially Frits de Graaf and Bill Patterson. Thank you for giving me the opportunity to complete this thesis. It was always a pleasure to meet you in different parts of the world.

De radiologen uit het NoordWest Ziekenhuis in Alkmaar. Jullie hebben mij de mogelijkheid geboden om tijdens mijn opleiding tot radioloog tijd vrij te maken voor wetenschap. Ik heb een geweldige en leerzame tijd in het NWZ gehad en ik ben er trots op dat ik door jullie ben opgeleid.

Lieve Leonie, jij staat altijd voor mij en ons gezin klaar. Ik waardeer je oprechte interesse in ons en je onvoorwaardelijke liefde en steun. In deze heftige tijd hoop ik dat we dat ook voor jou kunnen betekenen.

Lieve vriendinnen; Mieke, Katja, Femke, Mariska en Lotje. We kennen elkaar vanaf het begin van de geneeskunde studie en delen lief en leed met elkaar. Hopelijk blijven we dat nog heel lang doen.

Lieve schoonfamilie, en in het bijzonder Ineke, Maurits en Maud. Jullie staan altijd voor ons klaar en bieden hulp in welke vorm dan ook. Dank jullie wel daarvoor.

Lieve familie, Willem Jan Jr., Marlou en in het bijzonder mijn ouders. Lieve papa, jouw enthousiasme voor de interventie-neuroradiologie heeft er mede toe geleid dat ik gekozen heb voor radiologie en daar ben ik je elke dag dankbaar voor. Ik heb heel veel plezier beleefd aan de totstandkoming van dit proefschrift samen met jou en ik ben er trots op dat wij als vader en dochter dit hebben kunnen doen. Woorden schieten te kort om je te bedanken.
Lieve mama, mijn grote steun en toeverlaat. Jij staat altijd voor me klaar. Ik wil je bedanken voor al je wijze adviezen en je onvoorwaardelijke liefde. Het geeft me een heel fijn gevoel dat je op 2 juli naast me staat.
Ik hou van jullie!

Lieve Jeroen, liefde van mijn leven. Al 14 jaar zijn we samen waarvan drie jaar getrouwd. Ik vind het heerlijk om mijn leven met jou te delen, ik zou niets anders willen. Als kers op de taart zijn we de trotse ouders van onze dochters Fenna en Sofie. Daar genieten we allebei enorm van. Ik wil je bedanken voor je steun, ook op het gebied van mijn carrière. Zonder jouw hulp had ik dit proefschrift niet kunnen realiseren.
In de zomer gaan we een spannende maar mooie tijd tegemoet; ik heb er zin in!

About the author

Sanne van Rooij was born on March 15, 1985, in Utrecht. In 2005 she graduated high school at the Jacob Roelands Lyceum in Boxtel. She started Medical School at the Vrije Universiteit Amsterdam in 2005. In 2008 she did a scientific rotation in the St. Elisabeth Ziekenhuis in Tilburg and started the work that finally led to this dissertation. She received her medical degree in 2011. After a Surgical internship of 8 months, she began as a resident Radiology in Noord West Ziekenhuis Groep in Alkmaar in 2012. During her Radiology training, she continued her scientific work. She achieved Board Registration in Radiology in 2019. Currently she is a fellow Mamma Radiology at St. Antonius Ziekenhuis in Nieuwegein.
In 2017 she married Jeroen Markenstein. Together they have two daughters of 1 and 5 years old.
In August 2020, she will start a permanent position as general- and mamma-radiologist in Bravis Hospitals in Roosendaal and Bergen op Zoom.